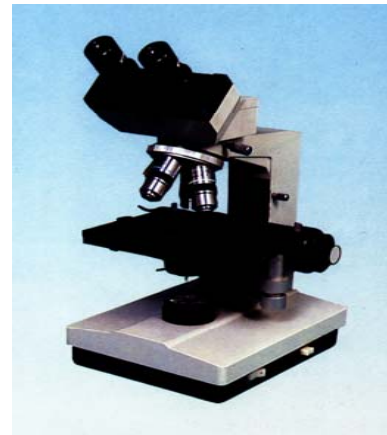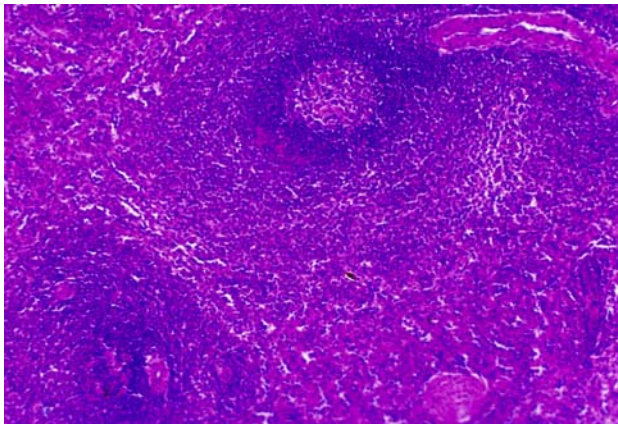



Histology and Embryology



- Chapter 1 Introduction and Cell**
- Chapter 2 Epithelial tissue**
- Chapter 3 Connective Tissue**
- Chapter 4 Blood**
- Chapter 5 Cartilage and Bone**
- Chapter 6 Muscle Tissue**
- Chapter 7 Nerve Tissue**
- Chapter 8 Circulatory System**
- Chapter 9 Immune System**
- Chapter 10 Skin**
- Chapter 11 Digestive Tract**
- Chapter 12 Digestive Gland**
- Chapter 13 Respiratory System**
- Chapter 14 Urinary System**
- Chapter 15 Endocrine System**
- Chapter 16 Sense Organ**
- Chapter 17 Male Reproduction**
- Chapter 18 Female Reproduction**
- Chapter 19 Embryology 1**
- Chapter 20 Embryology 2**

Chapter 9 Immune System

I Slides

II Sections

NO.34 thymus

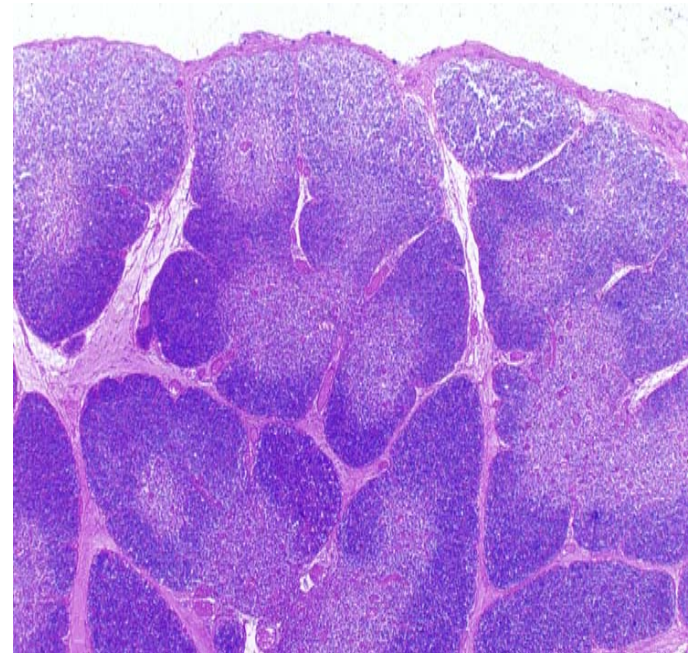
NO.36 lymph node

NO.37 spleen

NO.38 tonsil

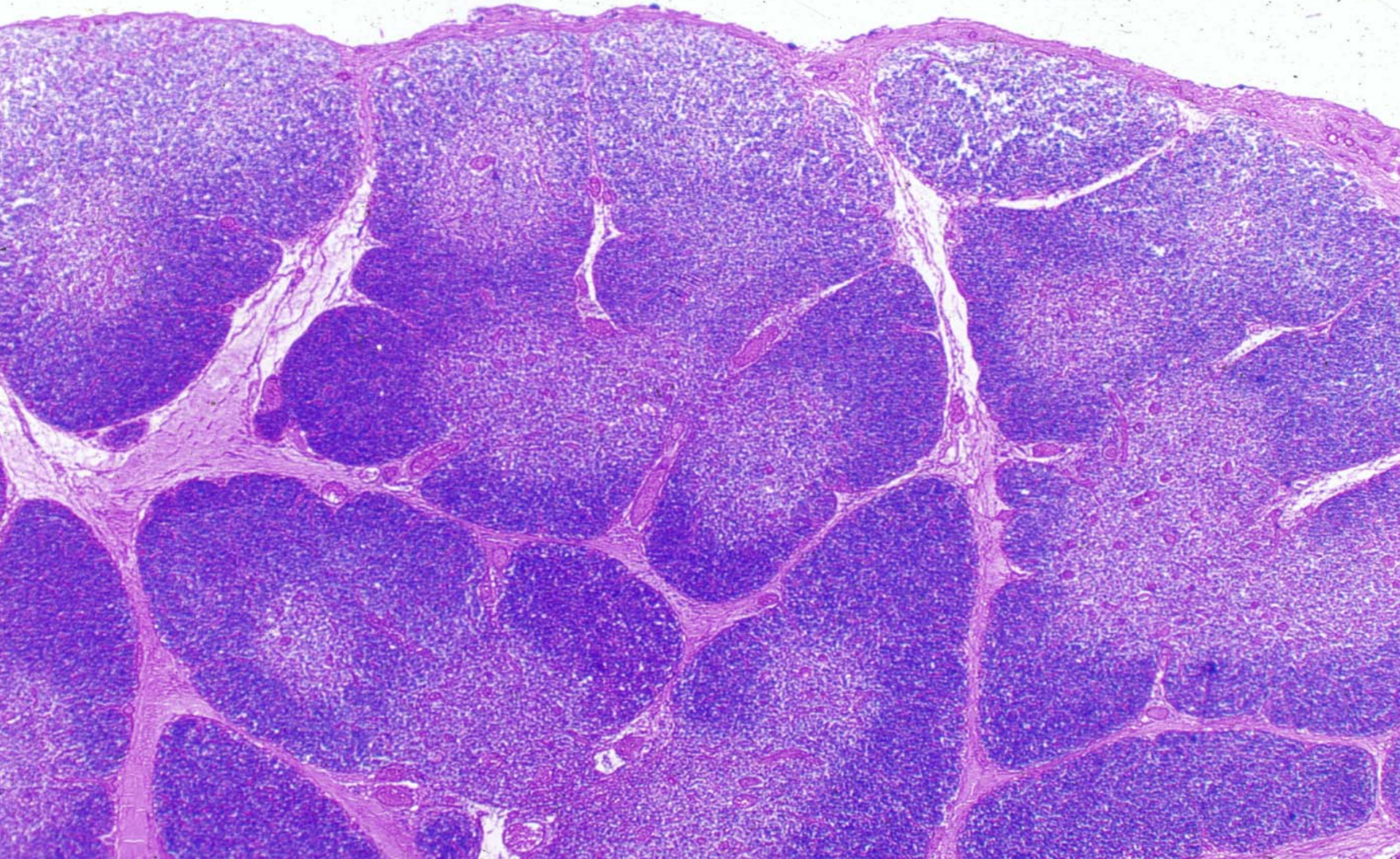
III EM photos: 35~39

IV Summary

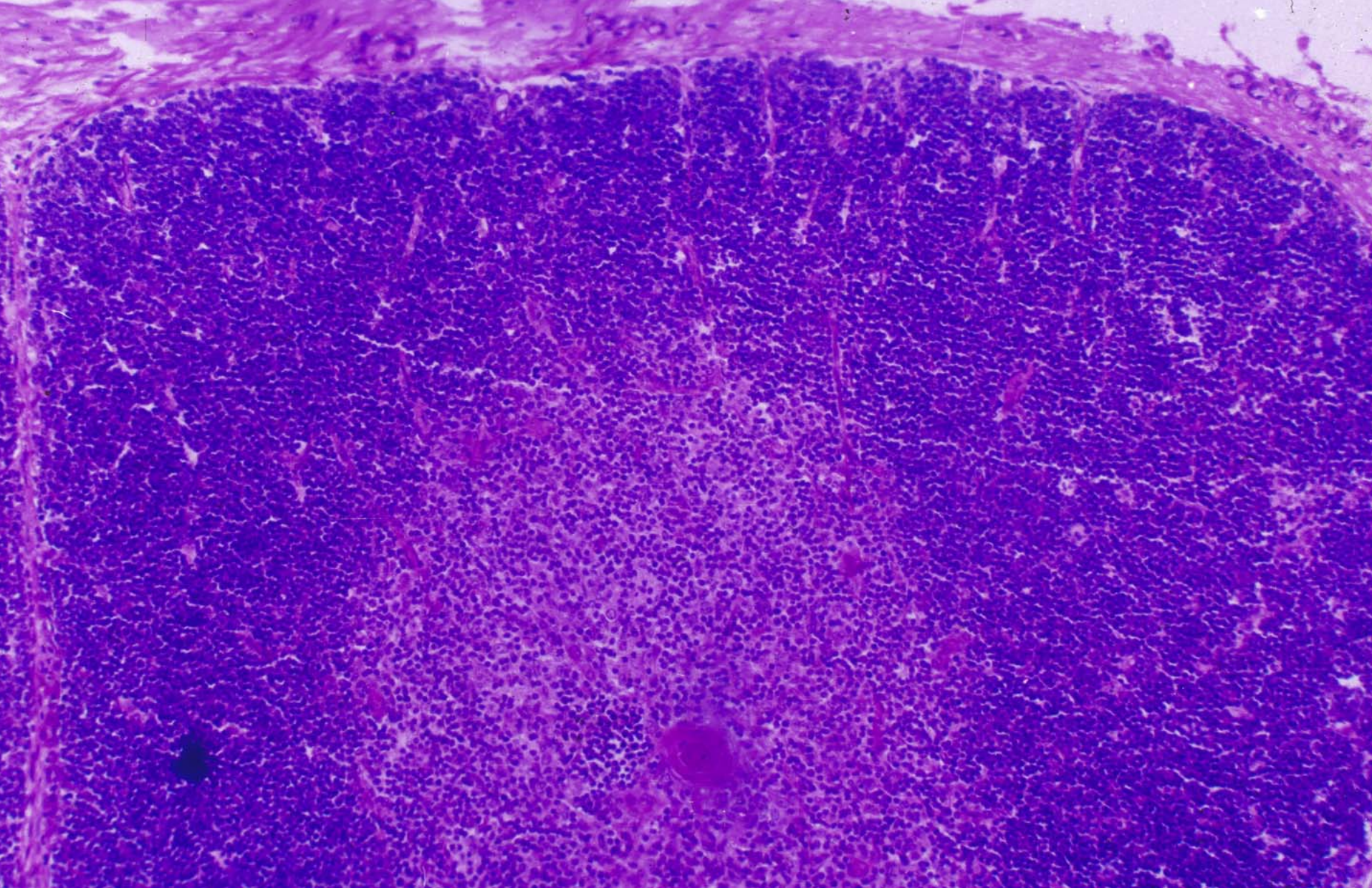


四、小结：

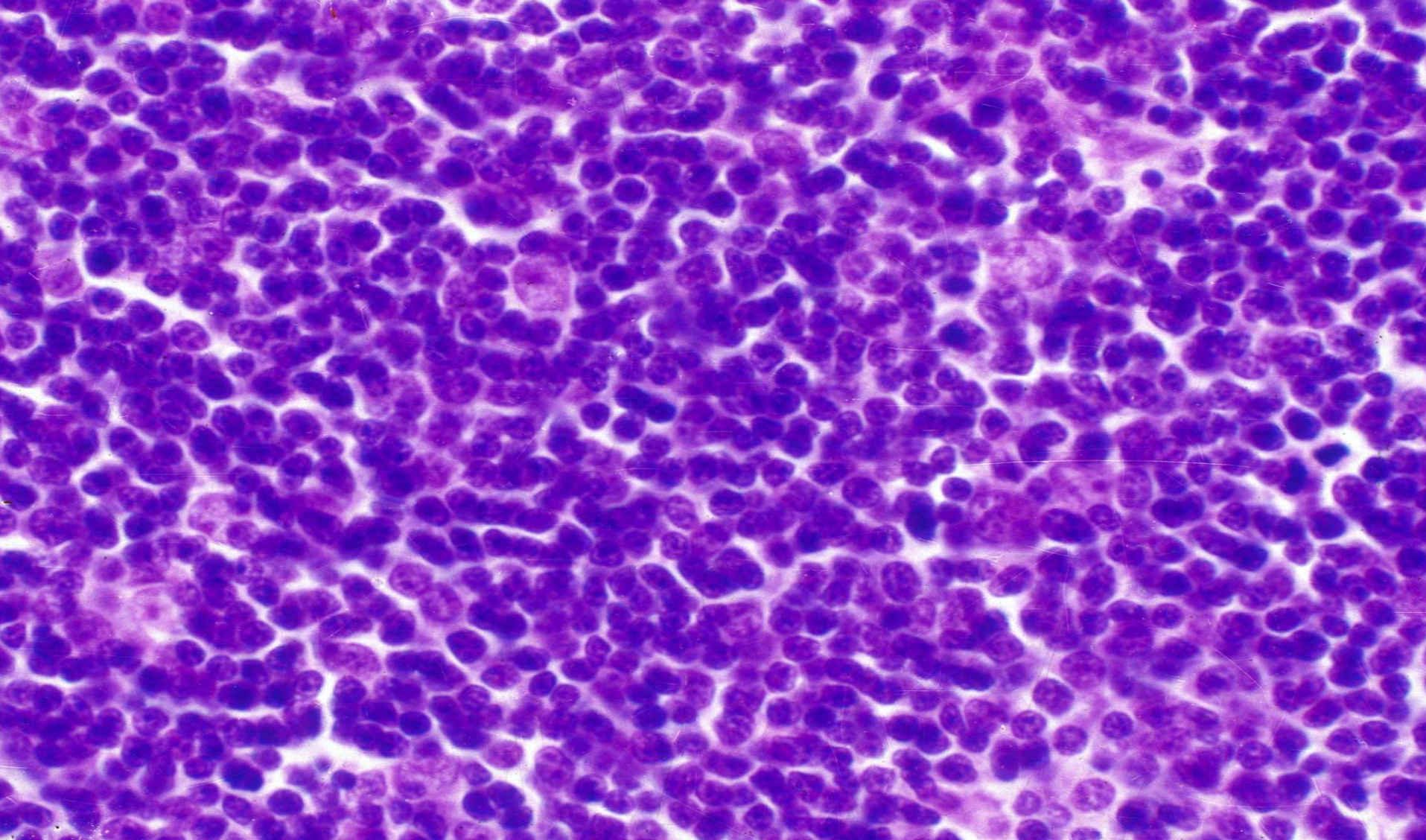
- 淋巴小结与弥散淋巴组织的结构与功能
- 淋巴结与脾的一般结构与功能



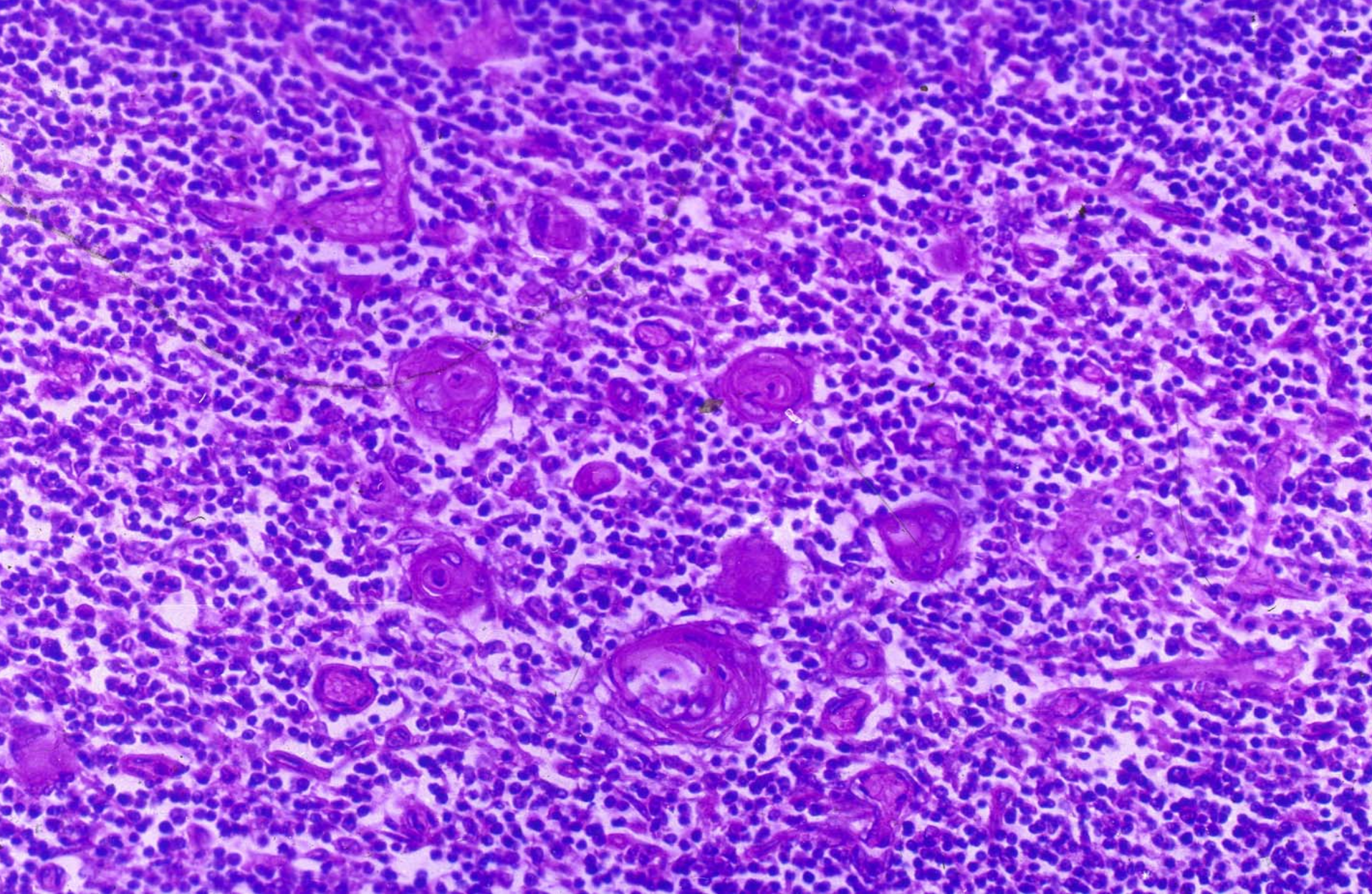
thymus



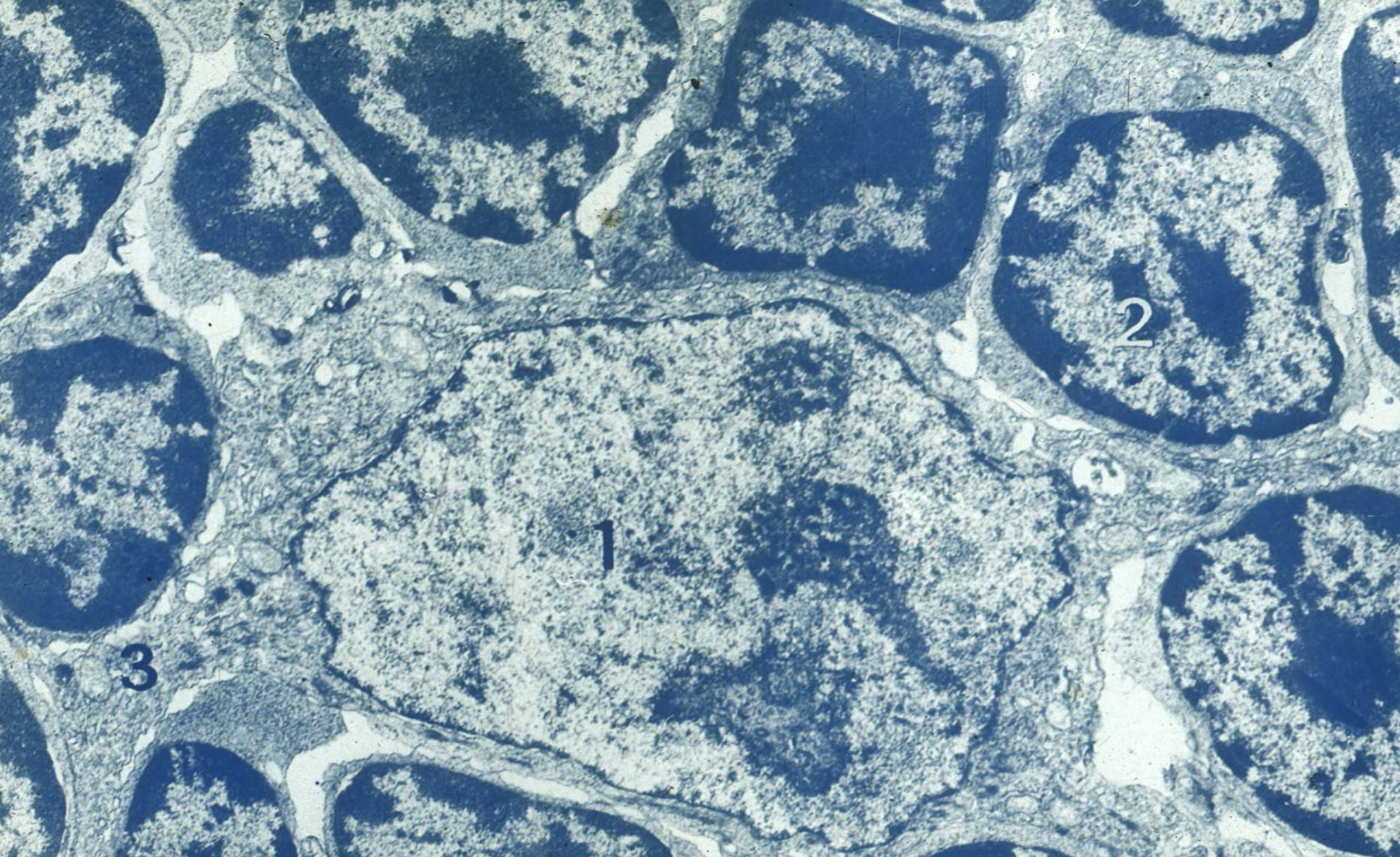
cortex of thymus



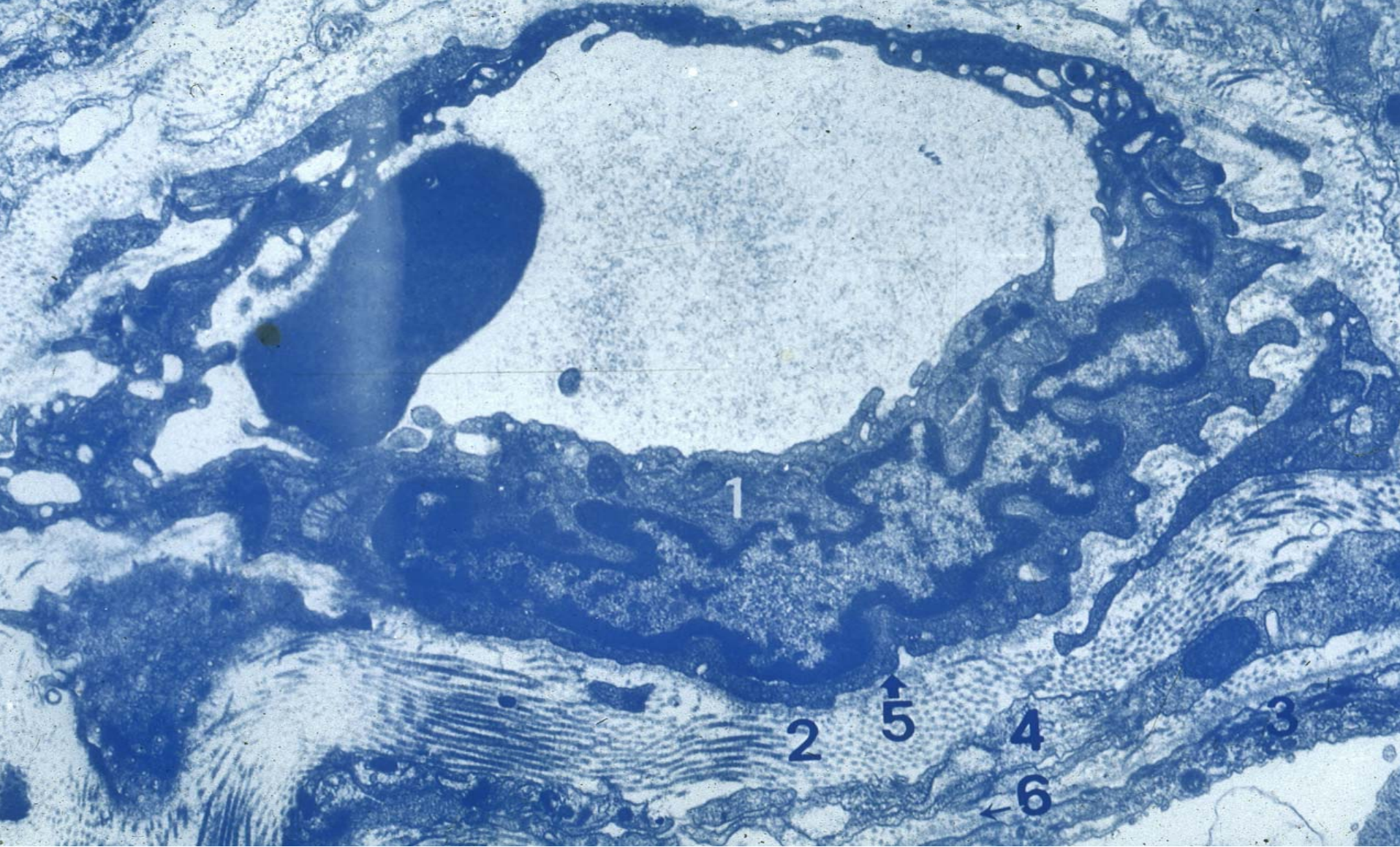
cortex of thymus



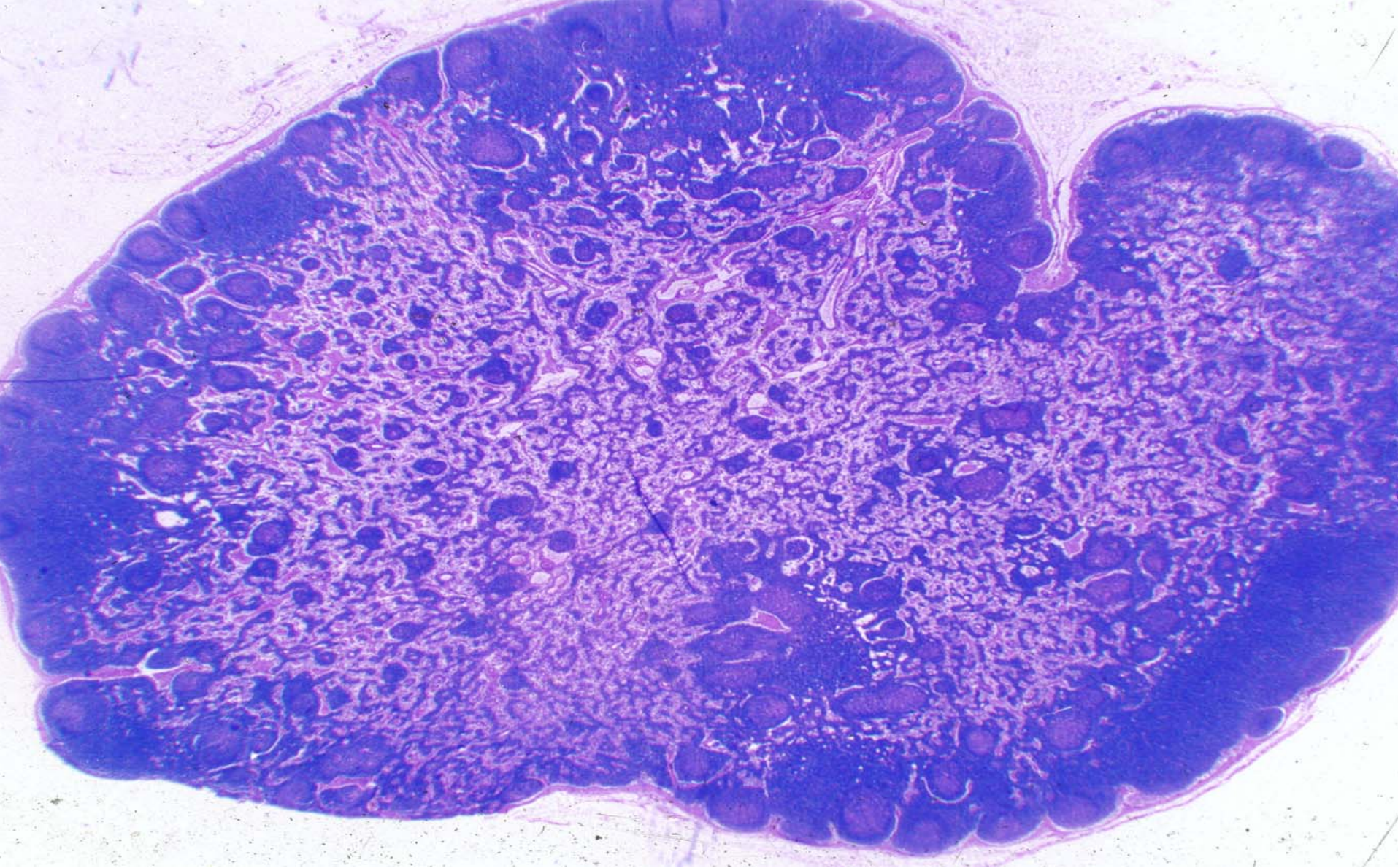
medulla



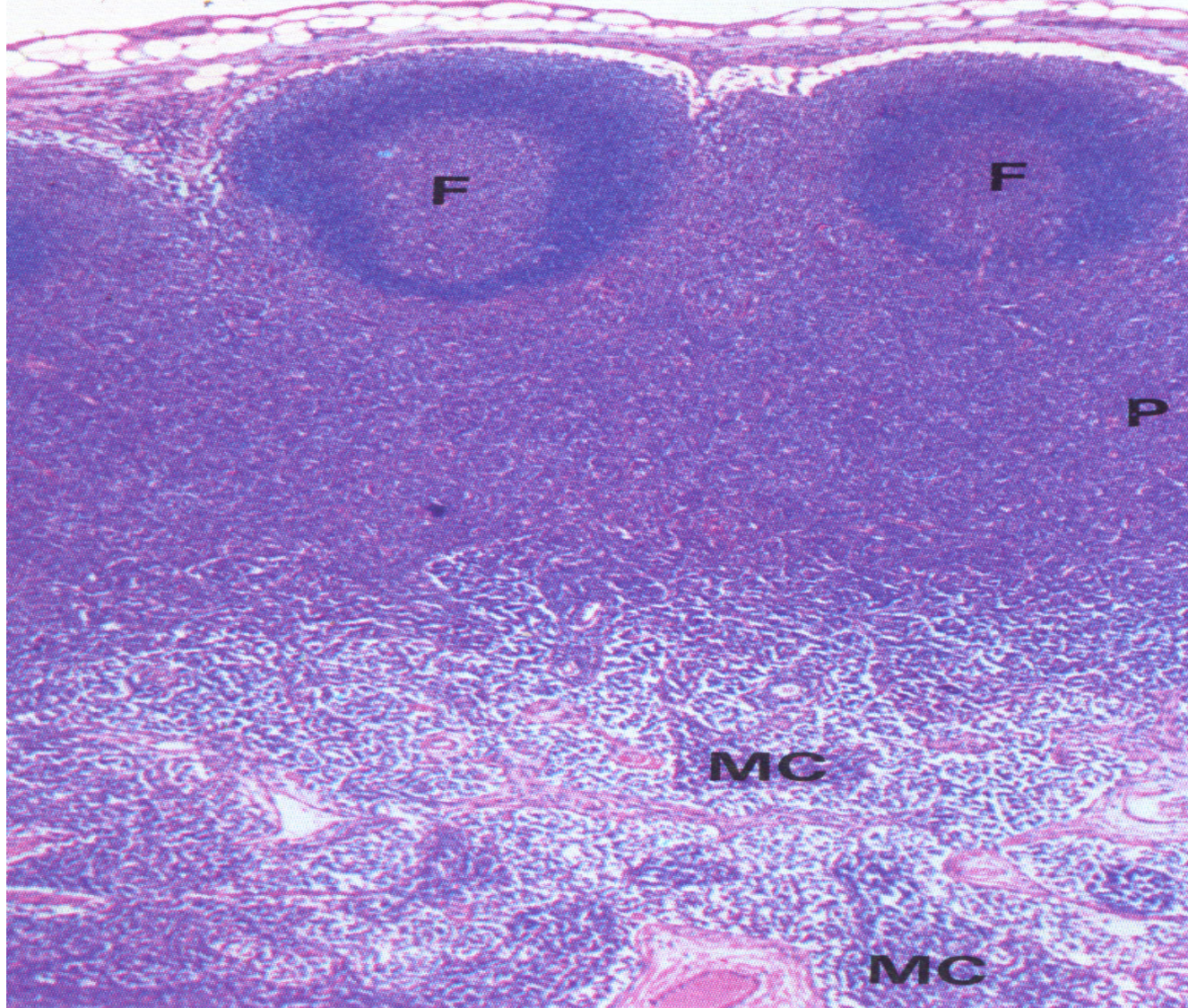
satellite epithelial cell



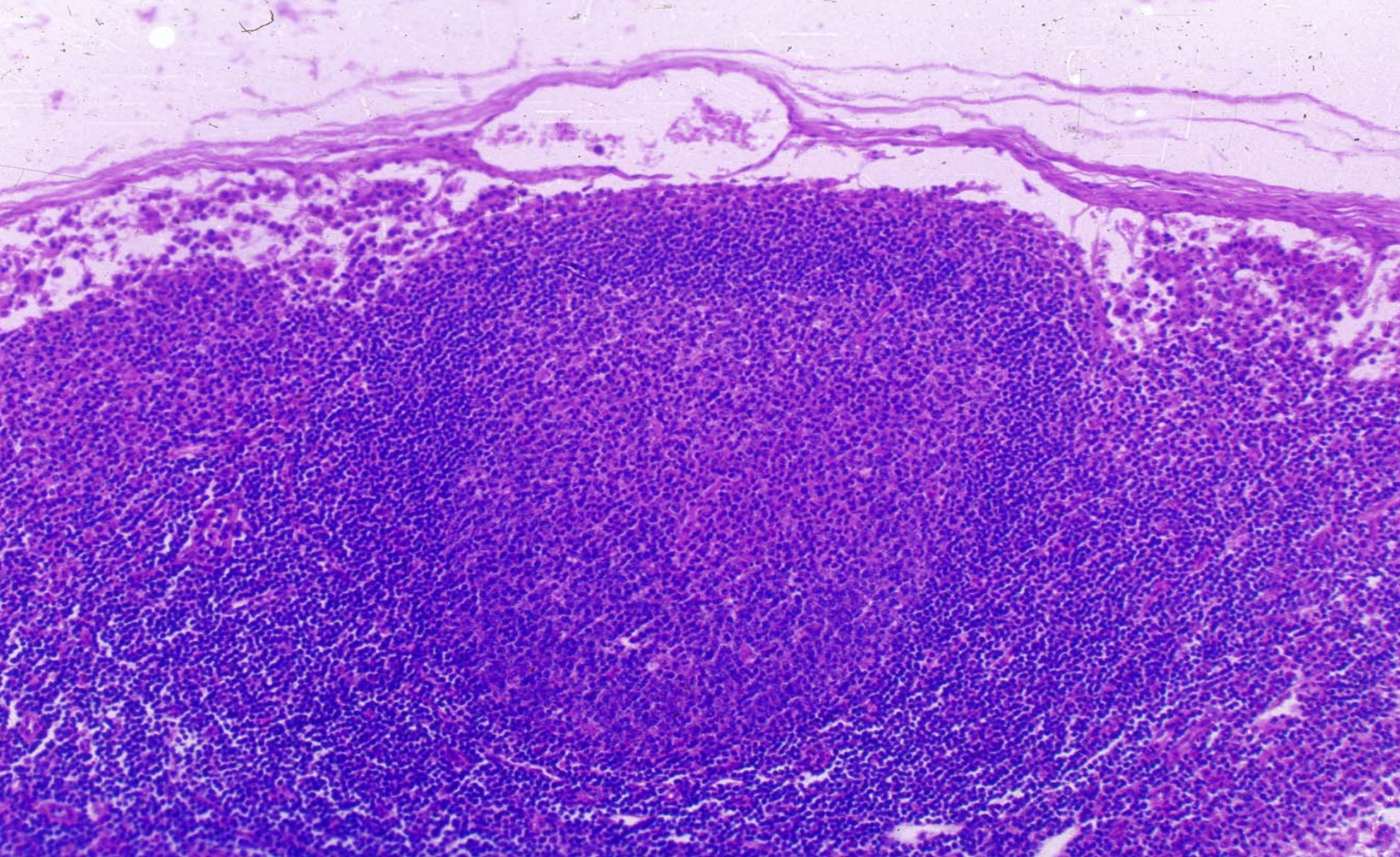
Blood thymus barrier



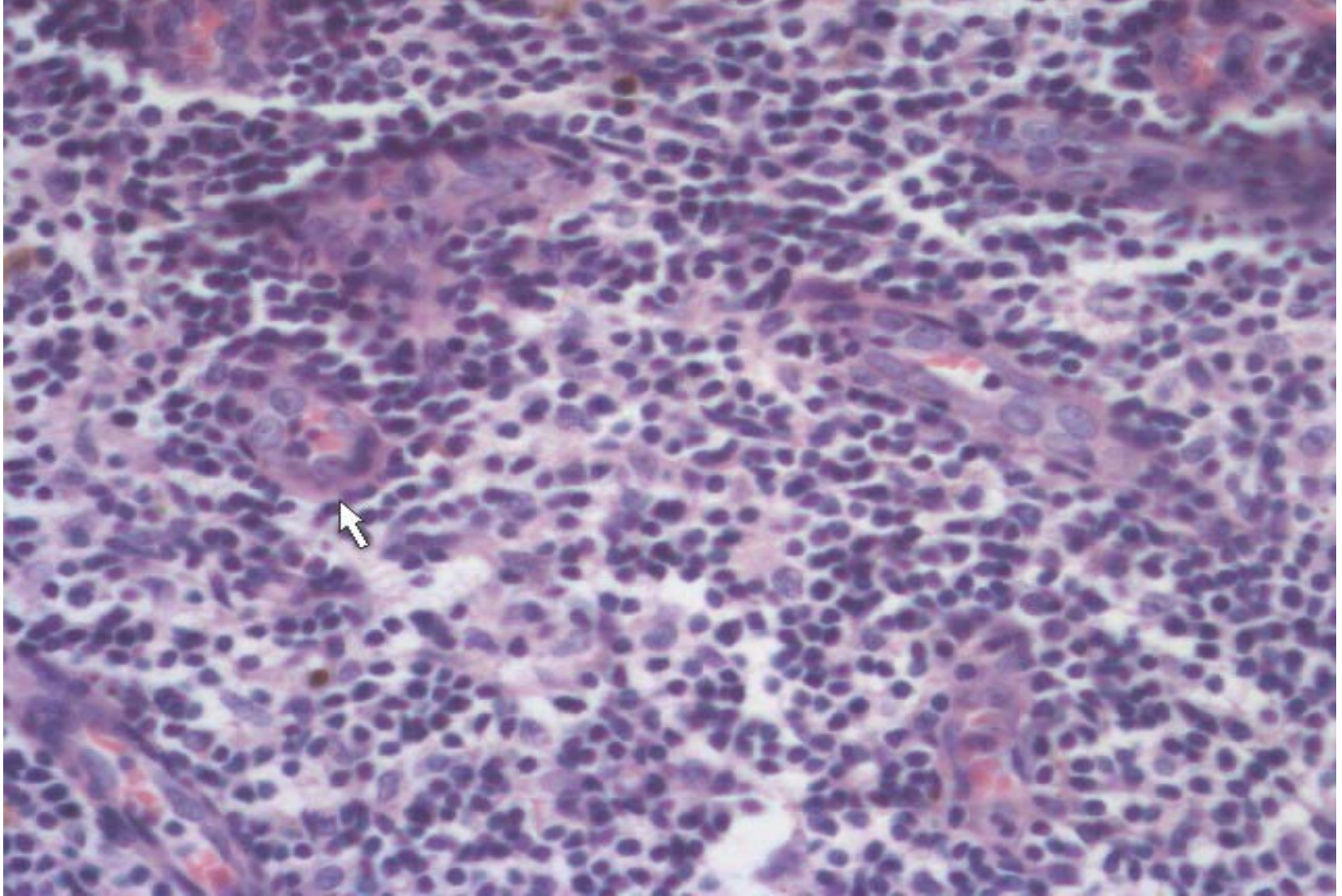
Lymph node



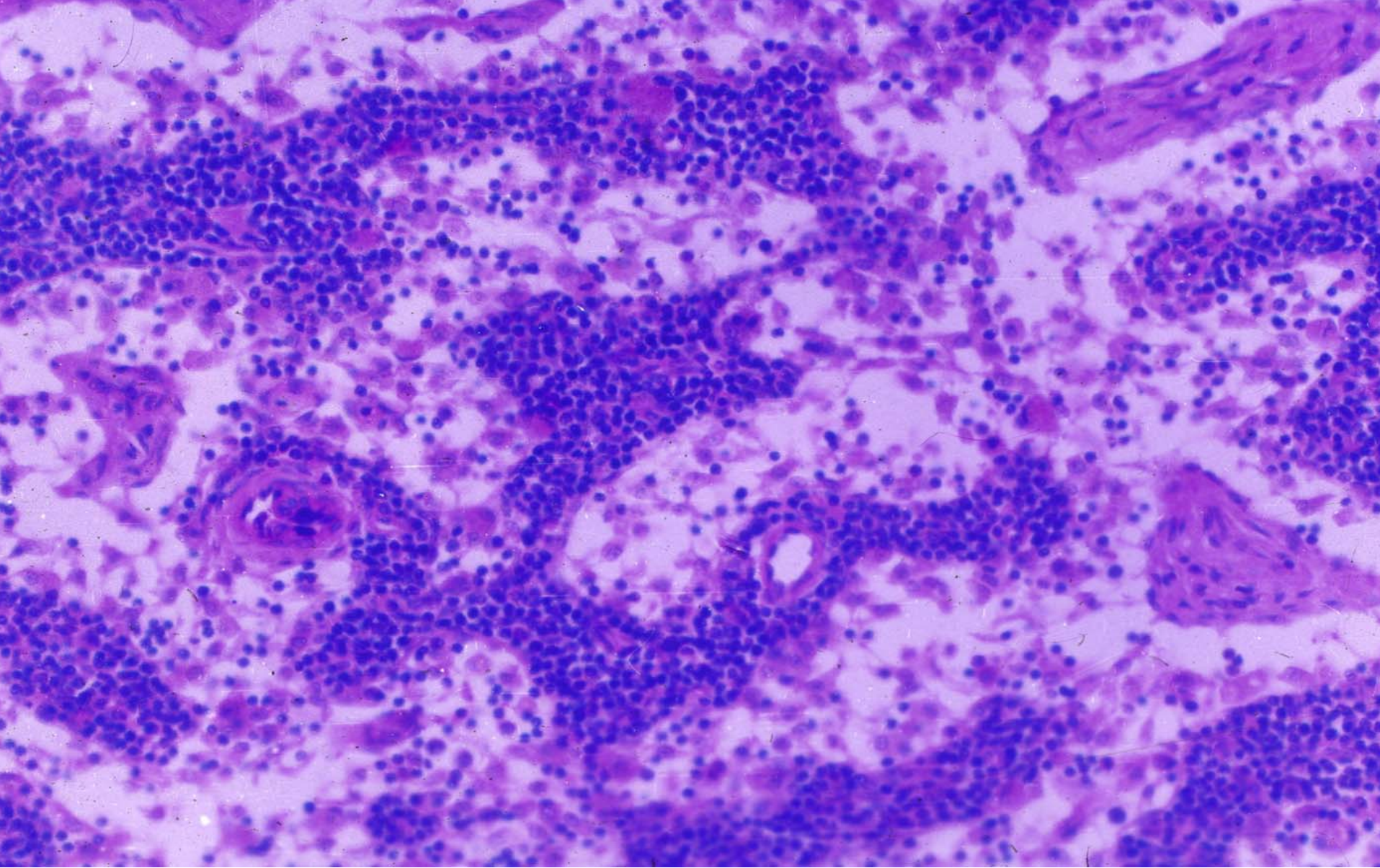
Lymph node



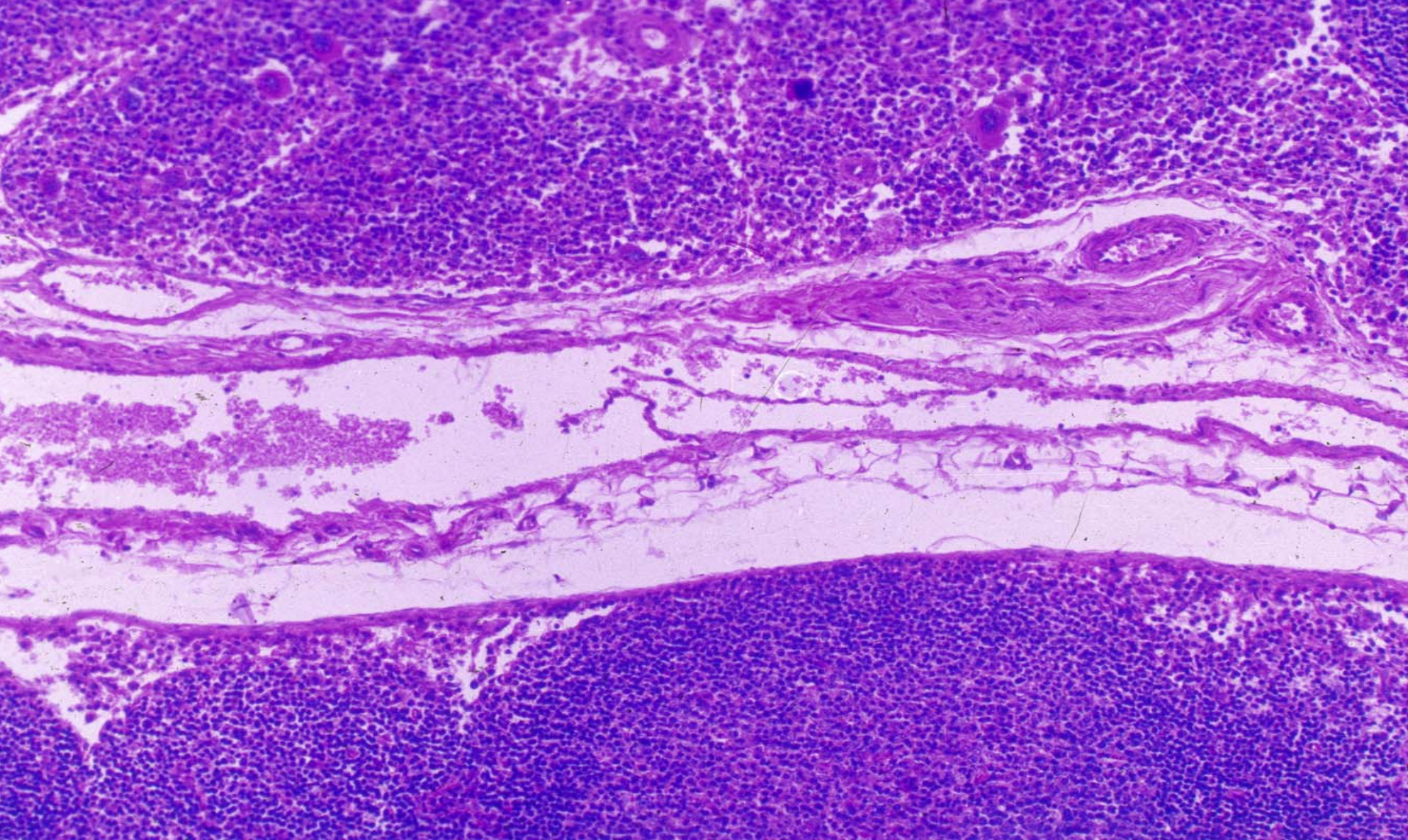
cortex



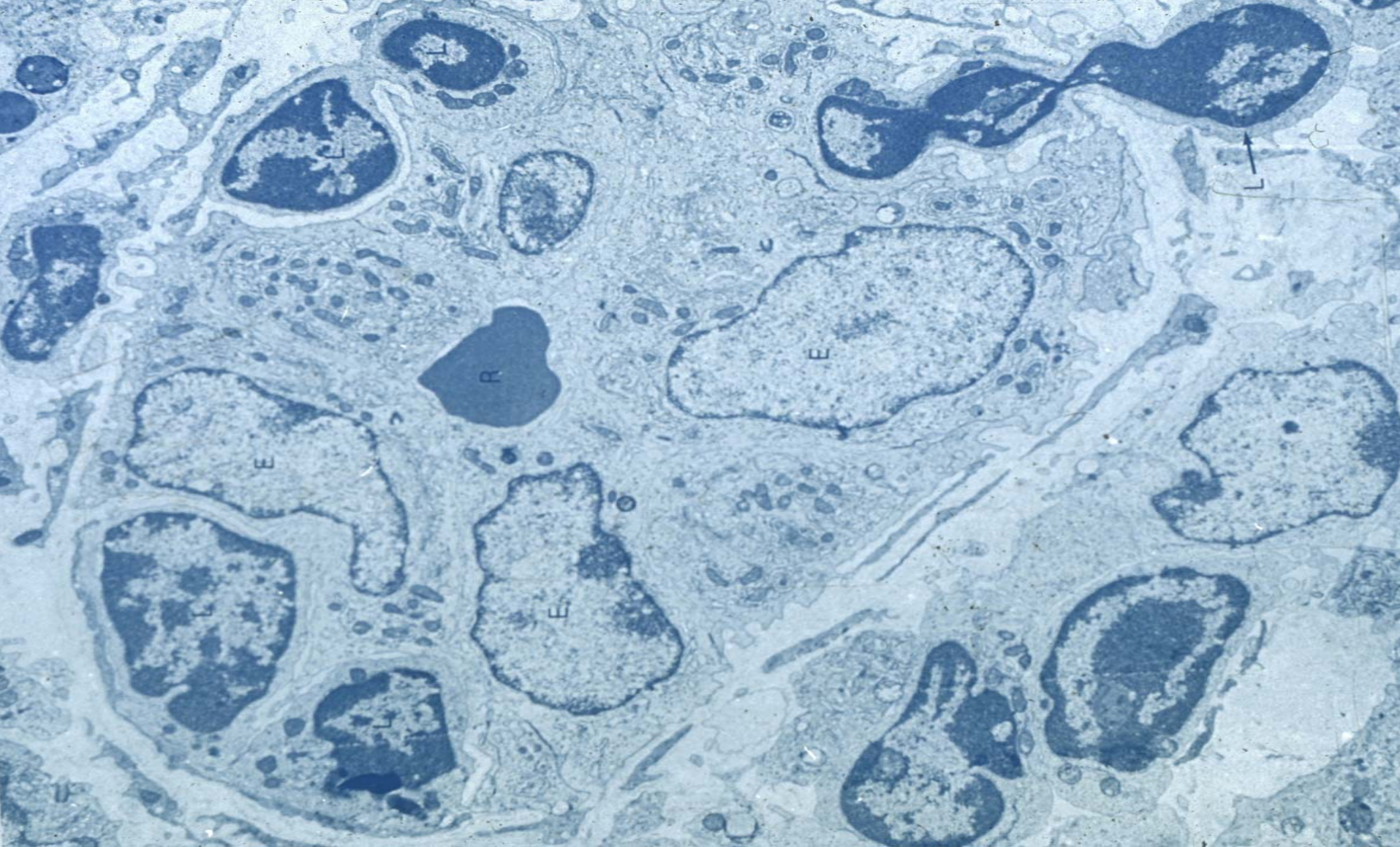
Postcapillary venules



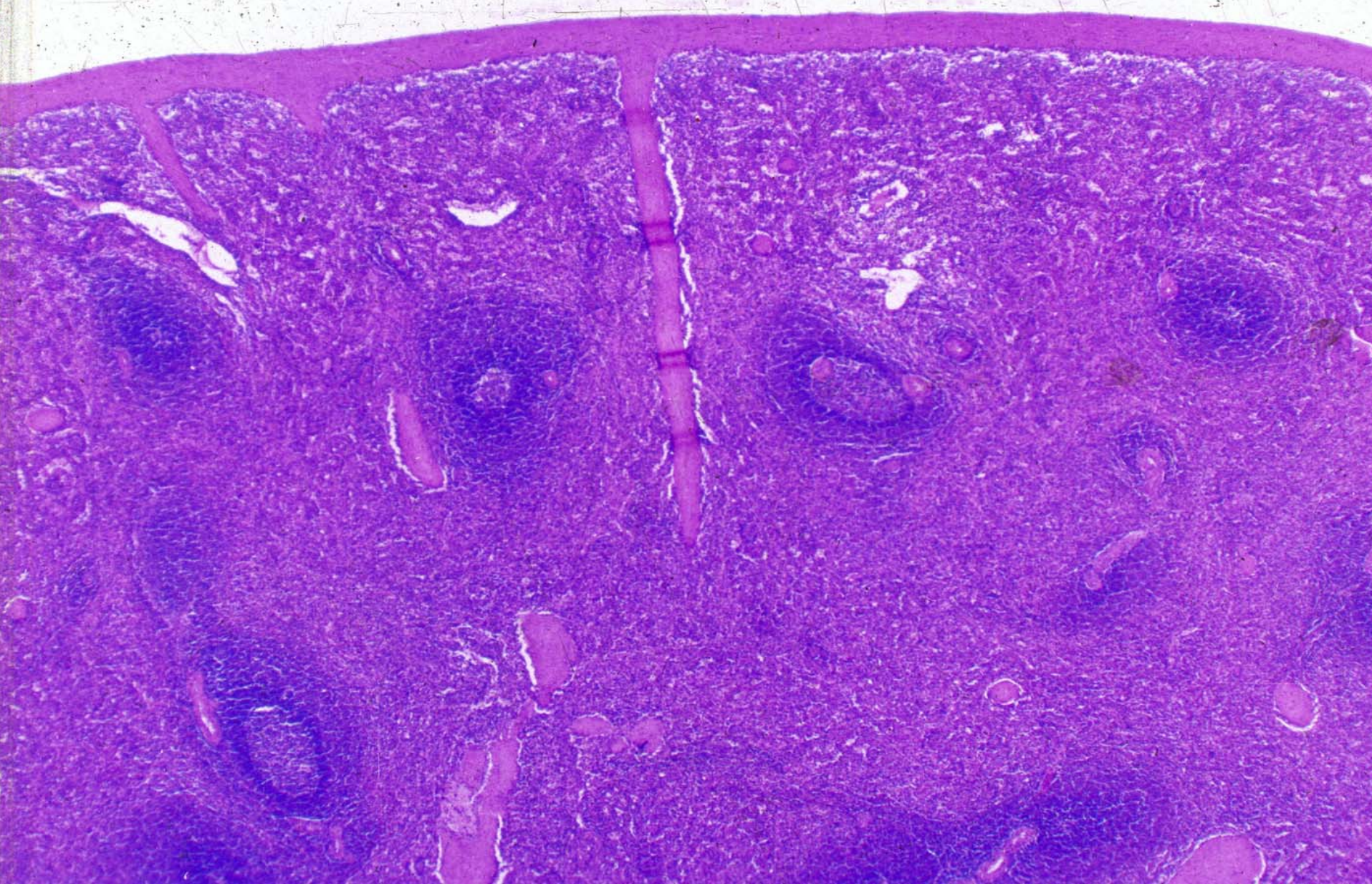
medulla



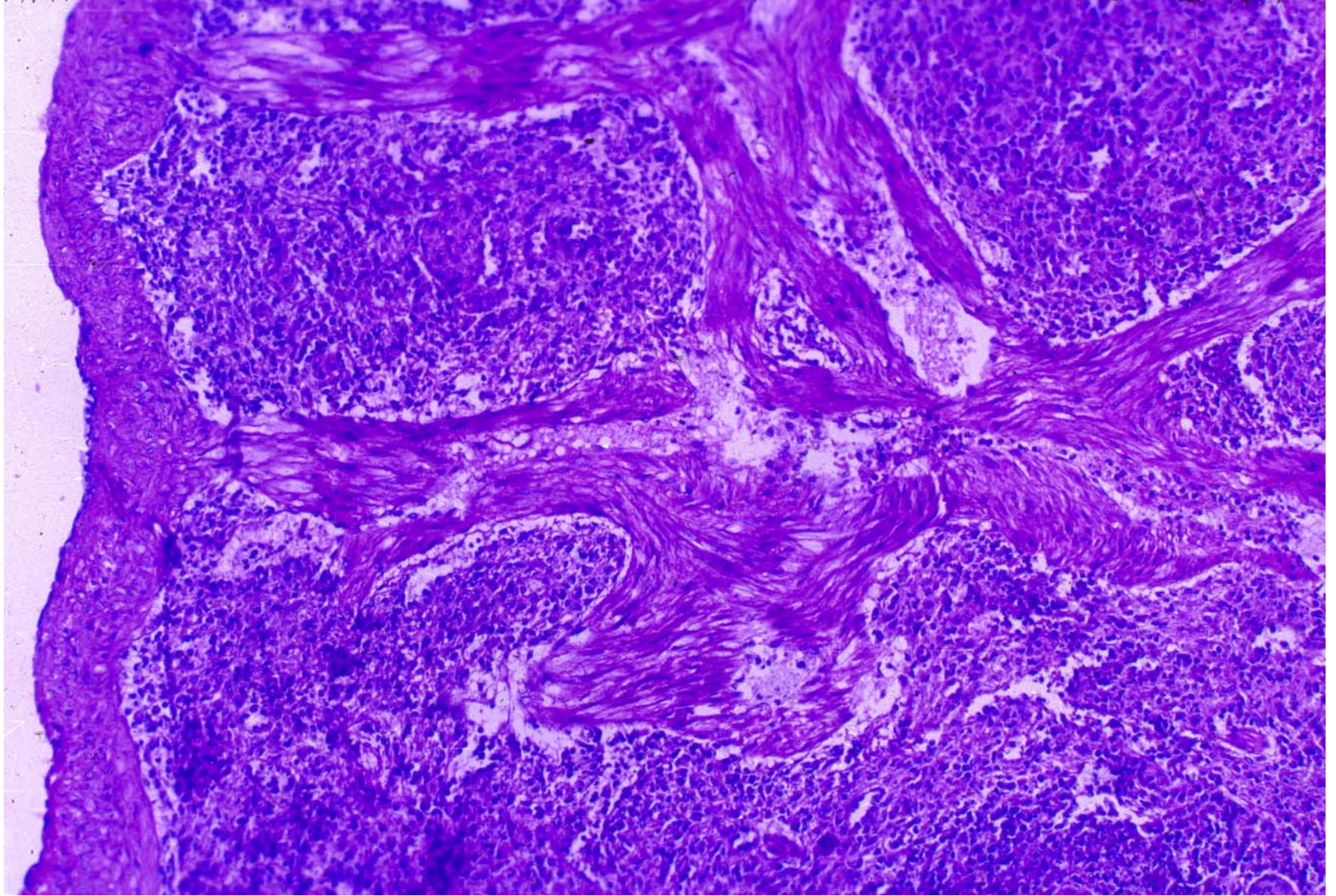
Efferent lymphatic vessel



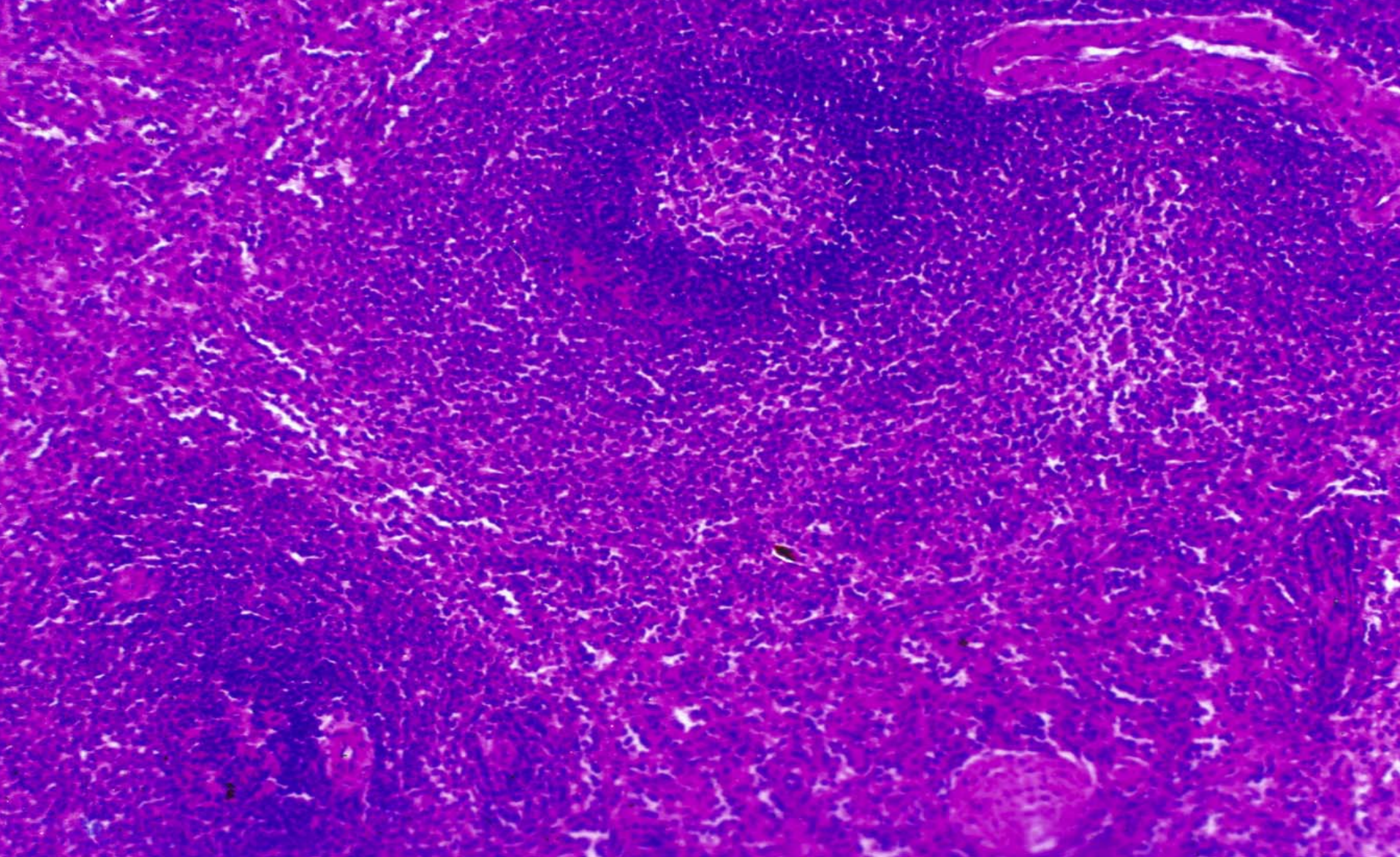
Postcapillary venules



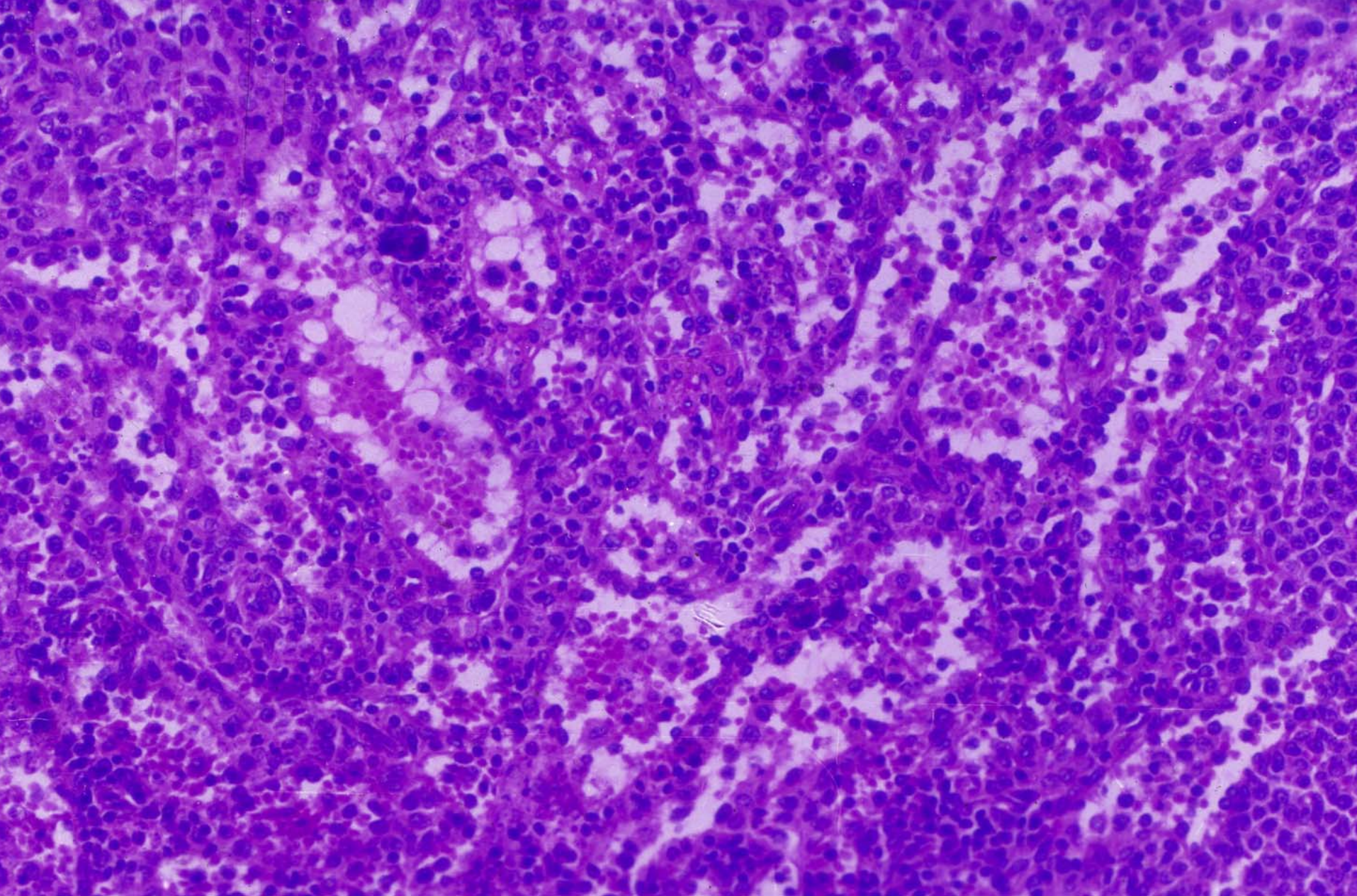
spleen



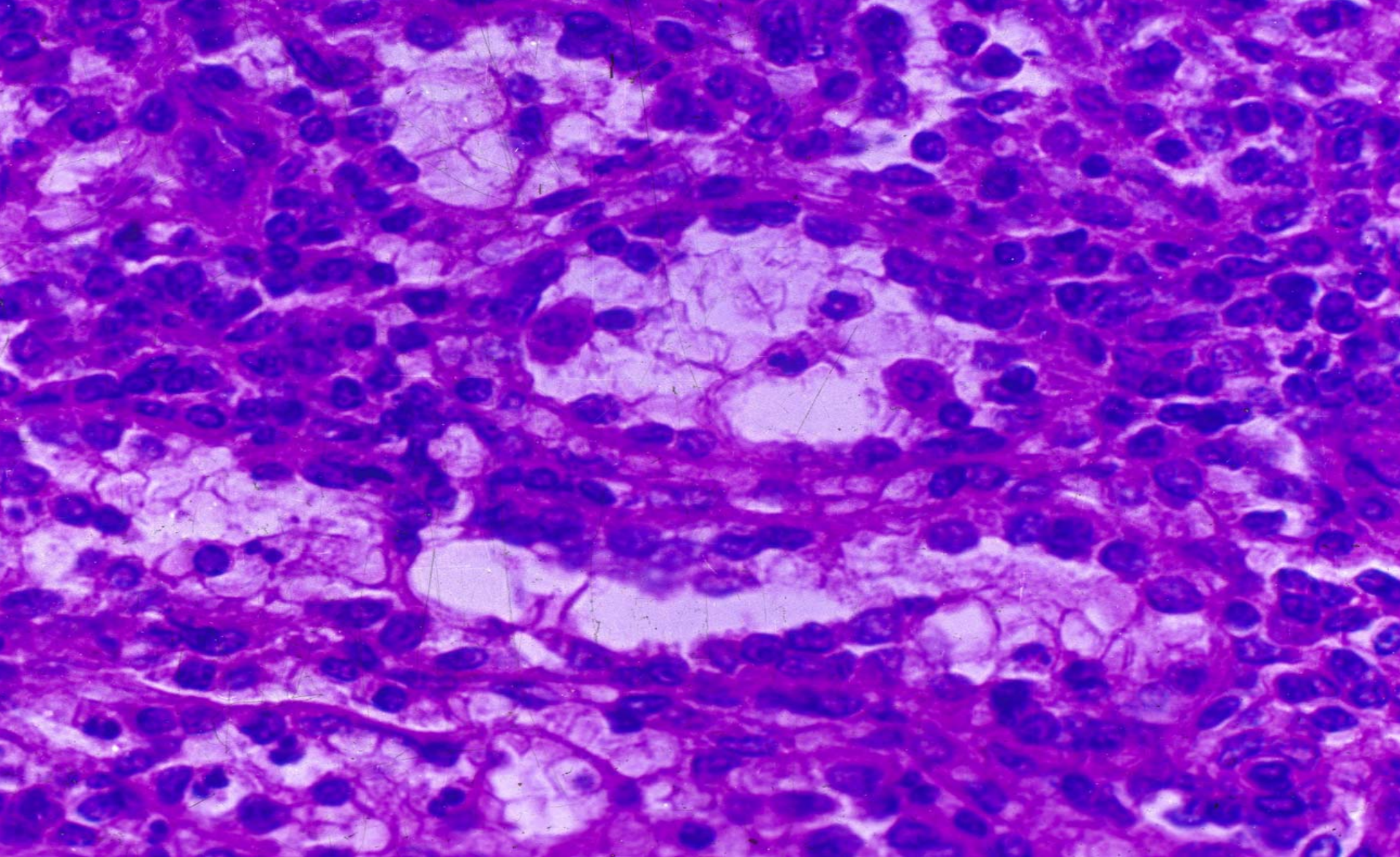
trabecular



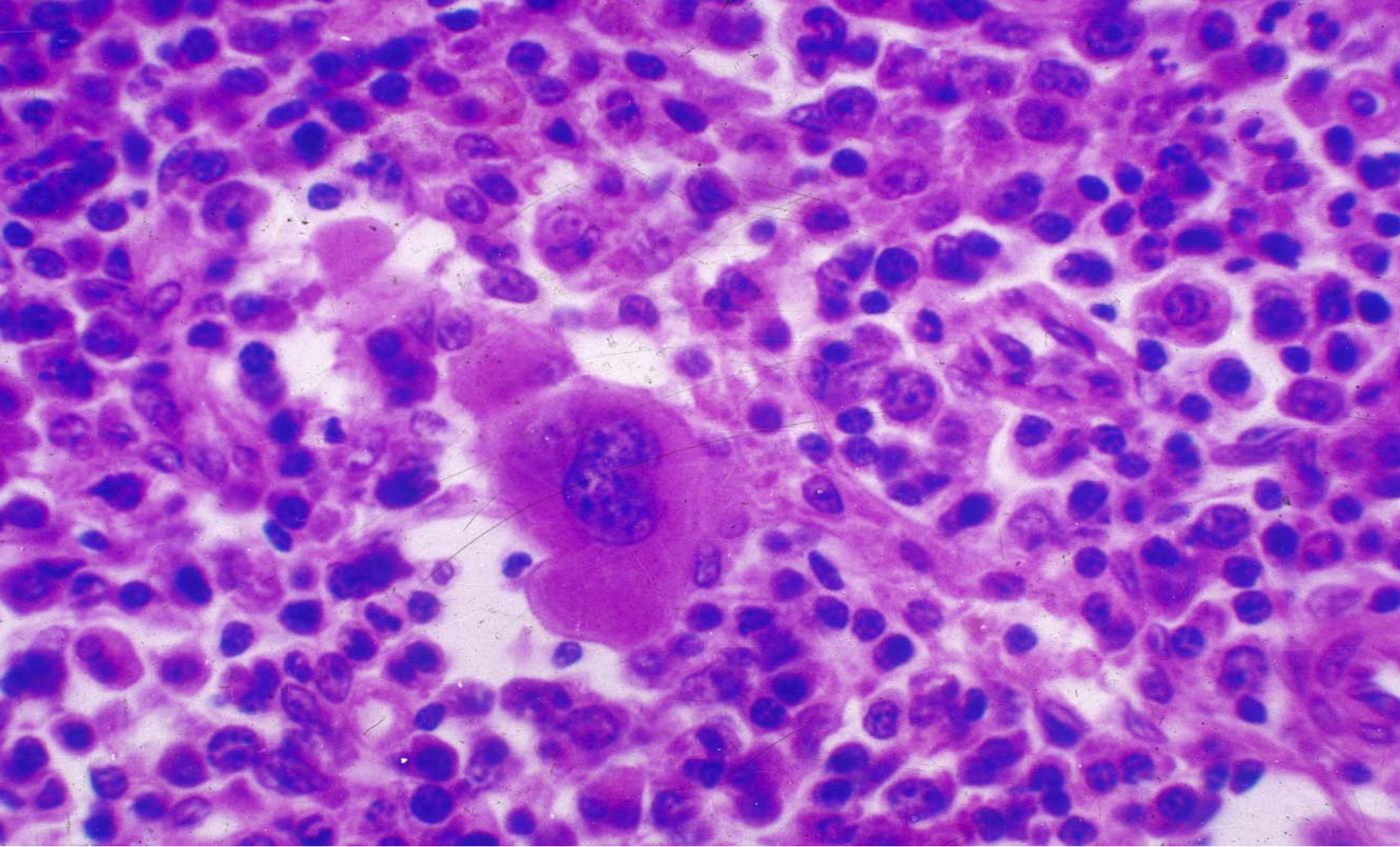
Splenic corpuscle



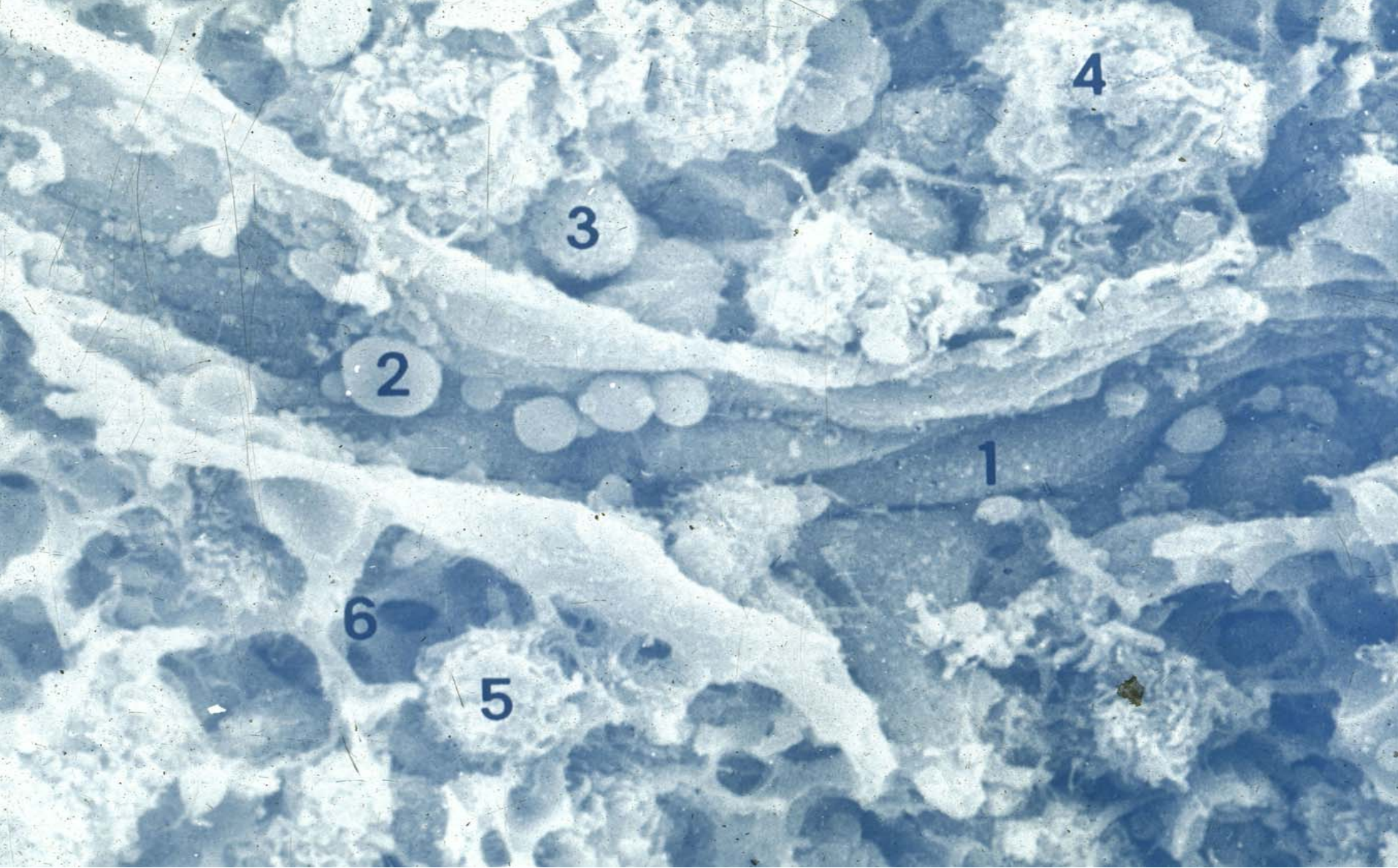
Red pulp



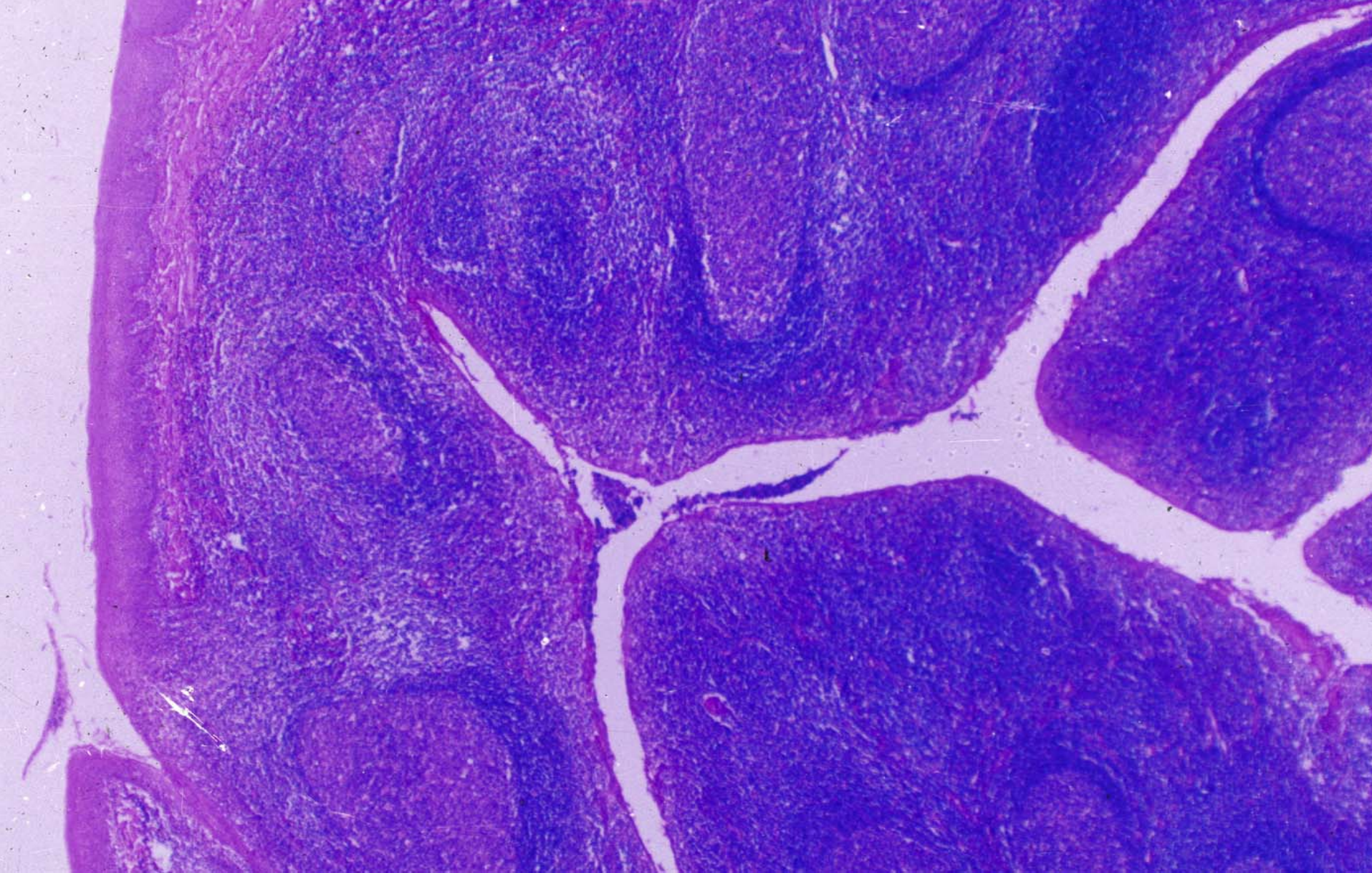
Splenic cord and splenic sinus



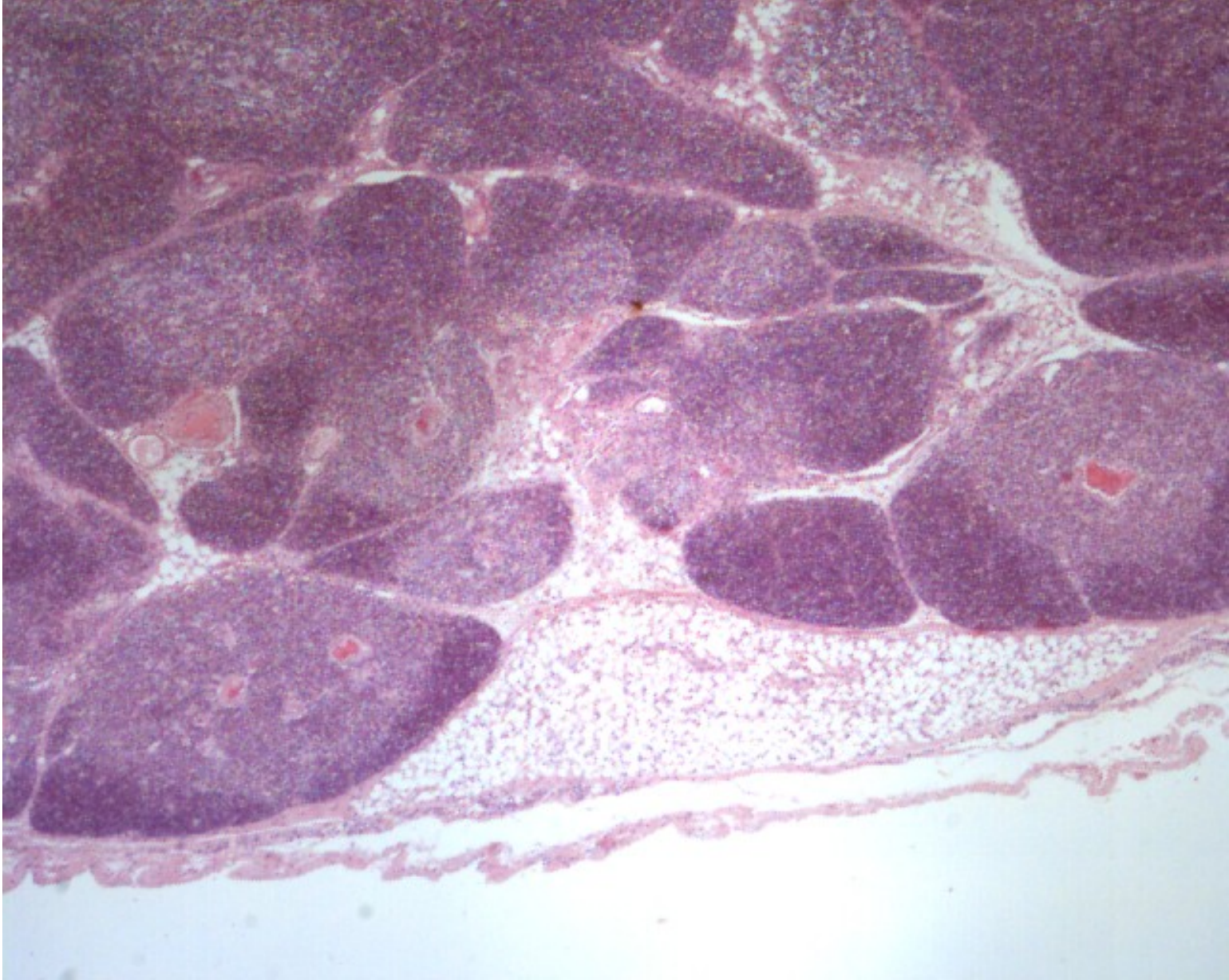
macrophage



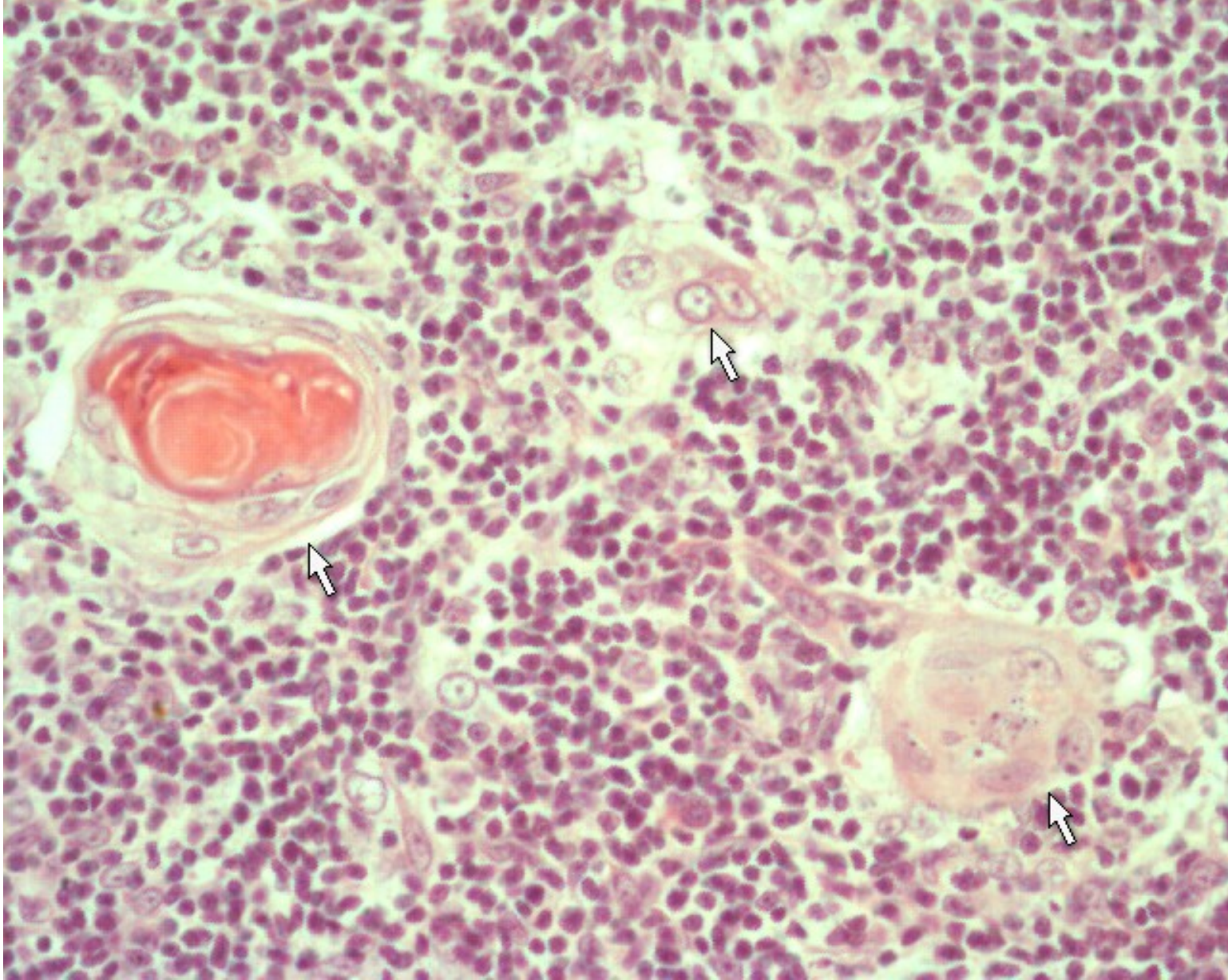
Splenic sinus



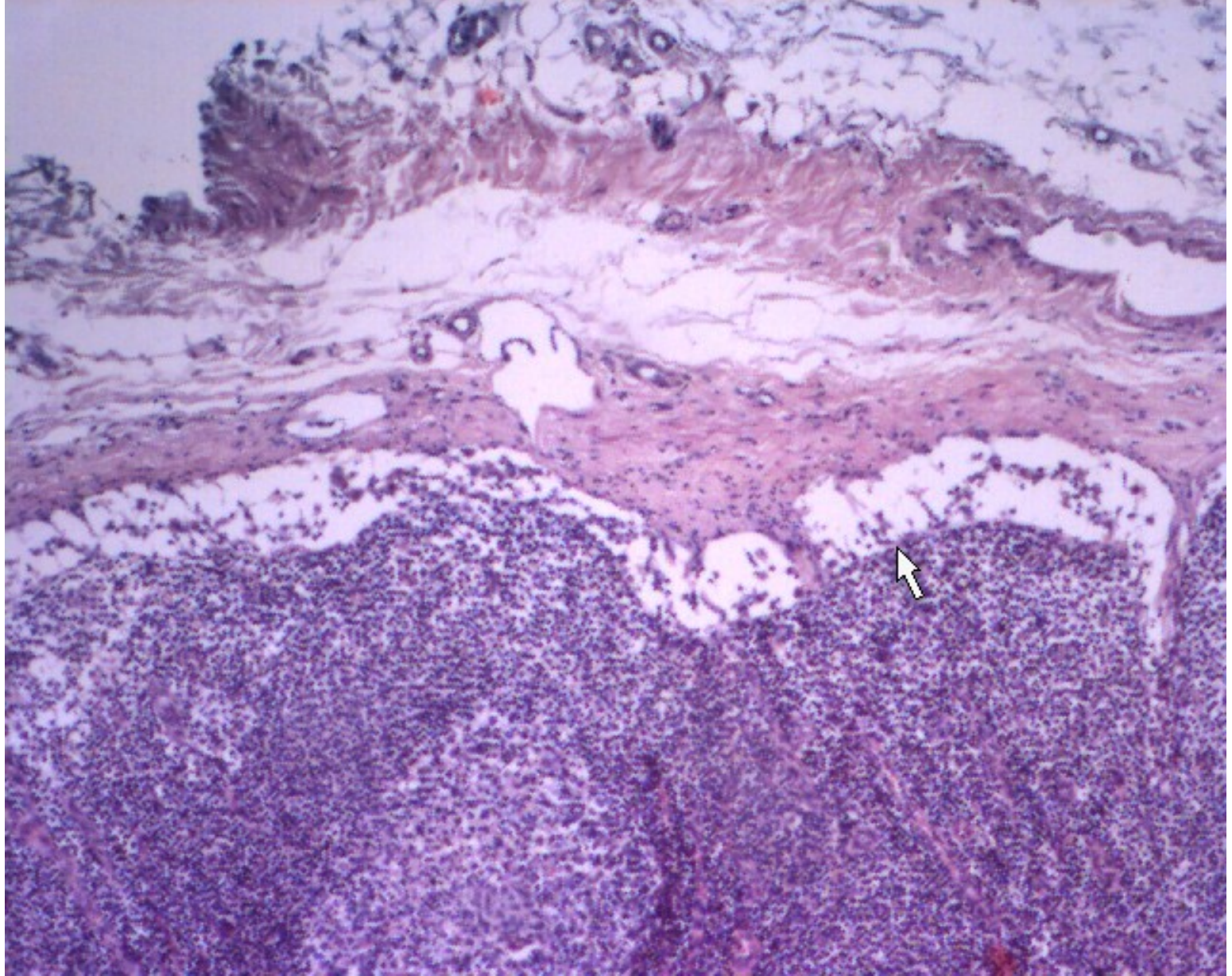
tonsil



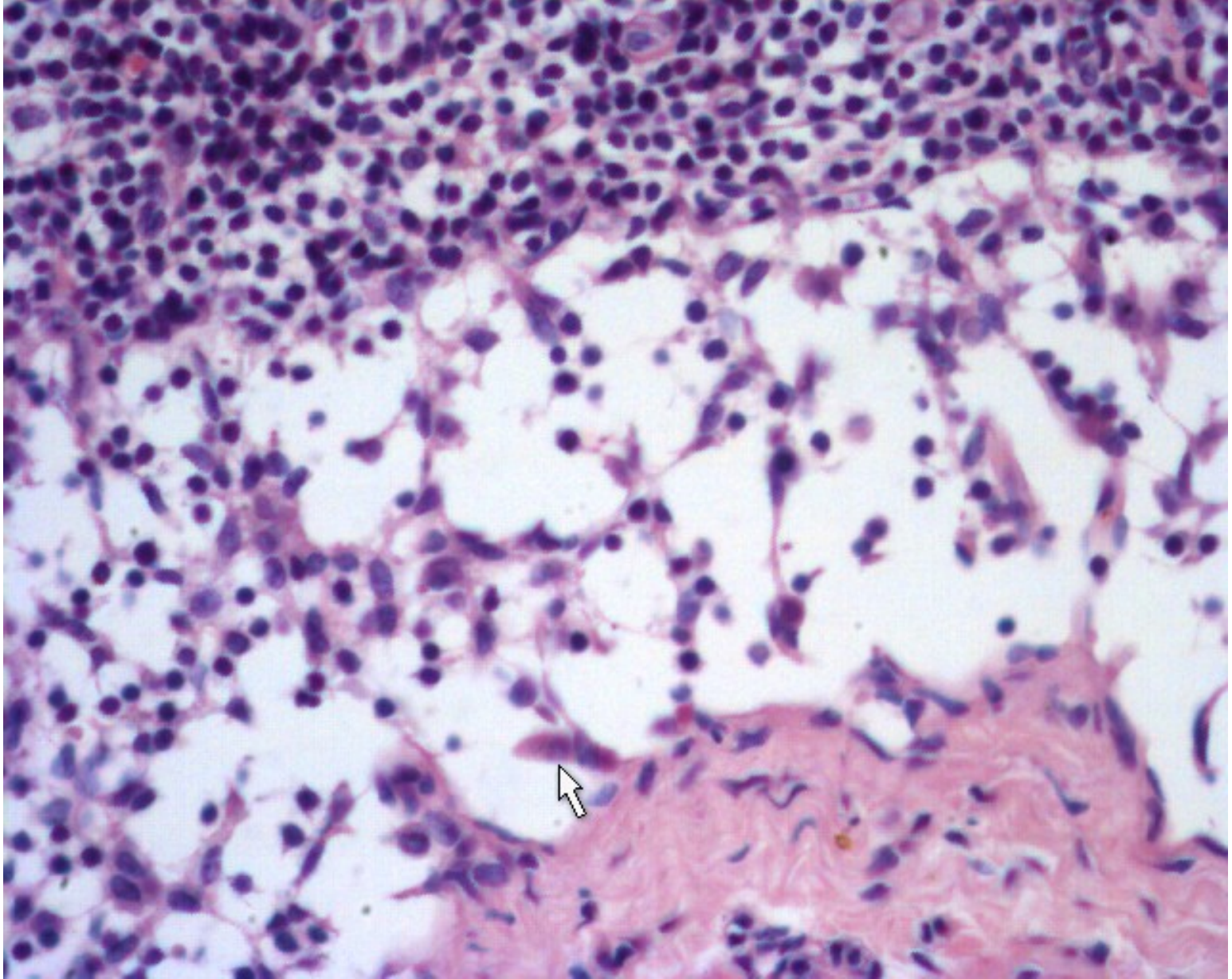
thymus



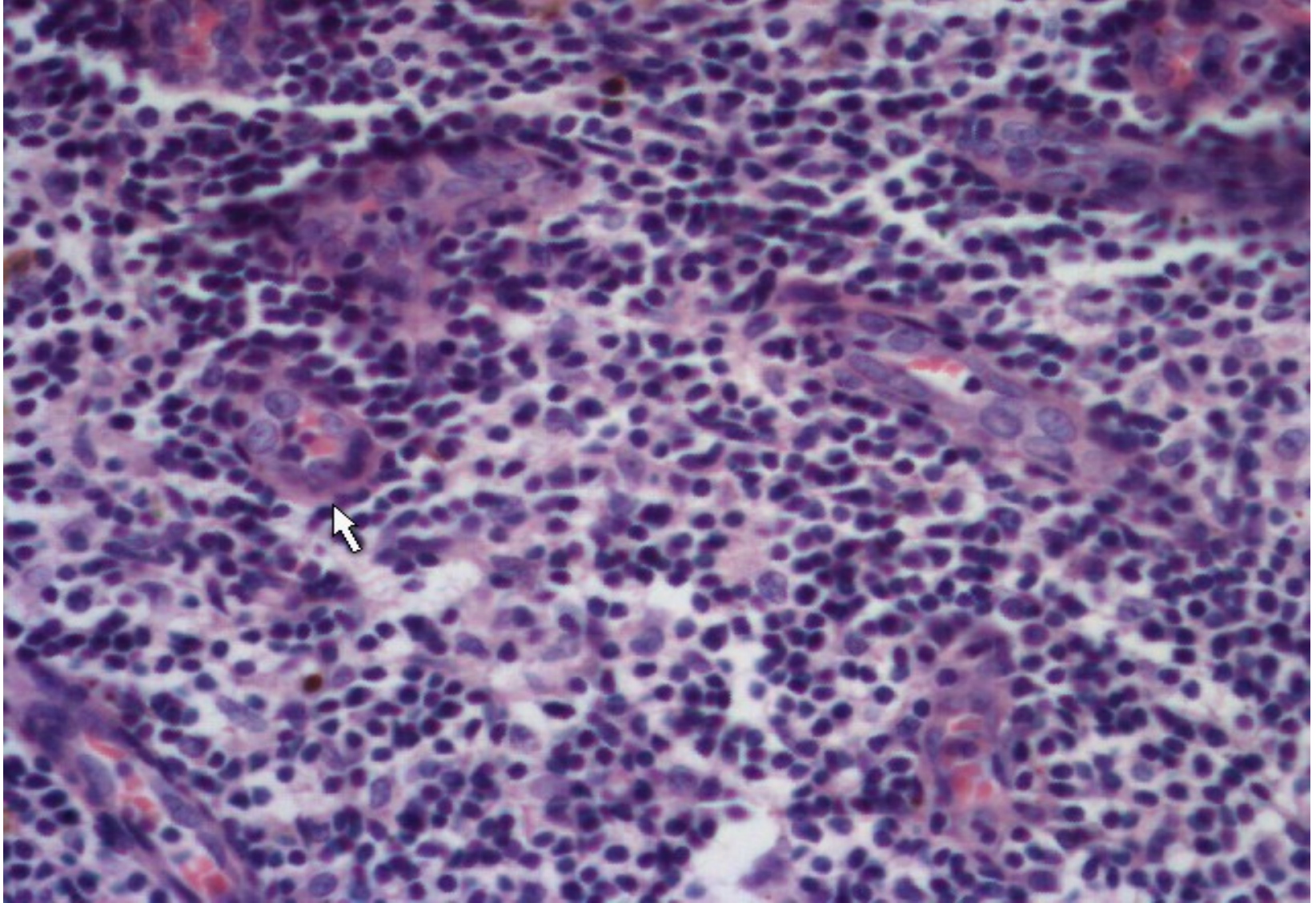
Thymic corpuscle



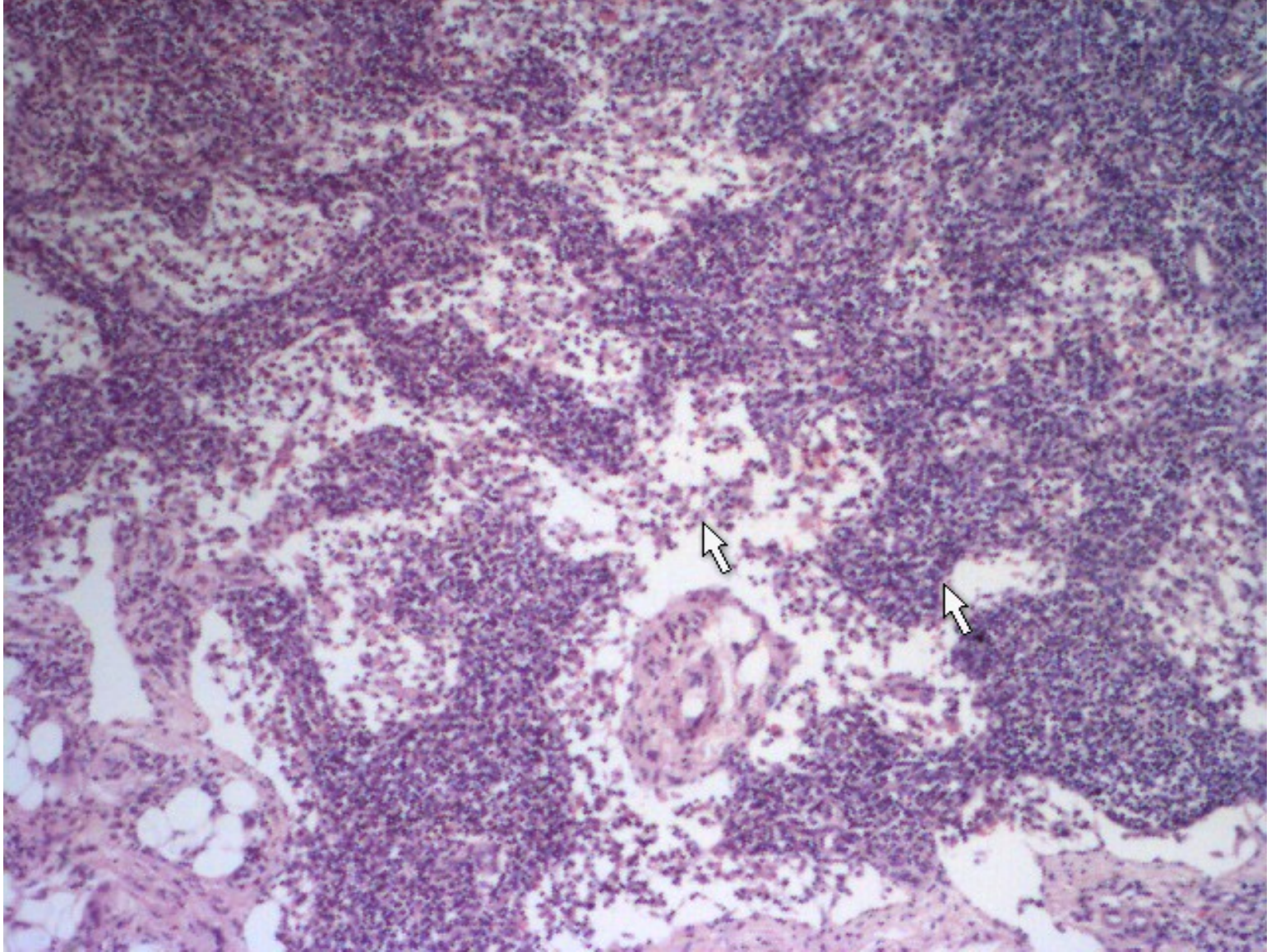
Afferent lymphatic vessel



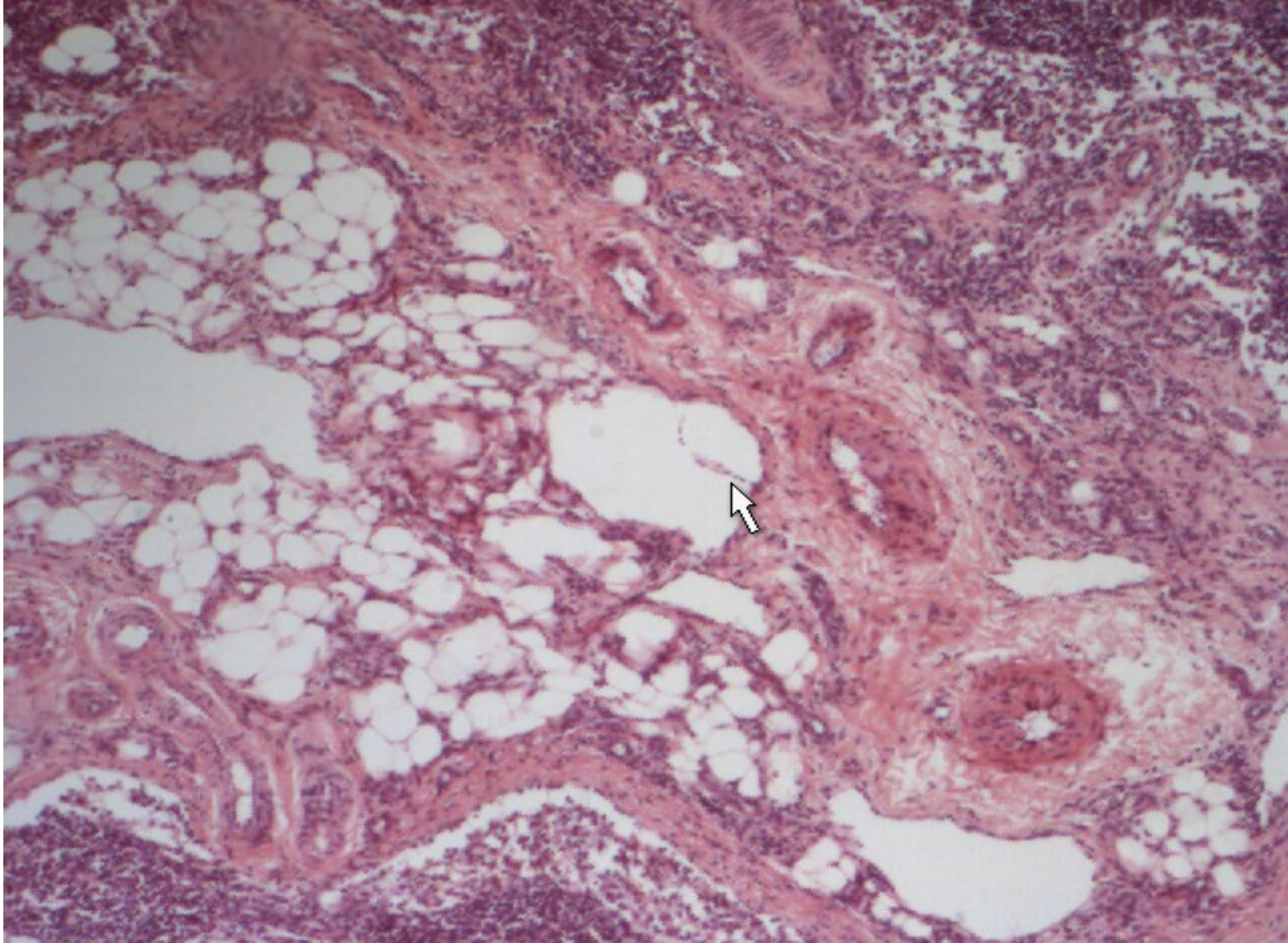
Supcapsular sinus



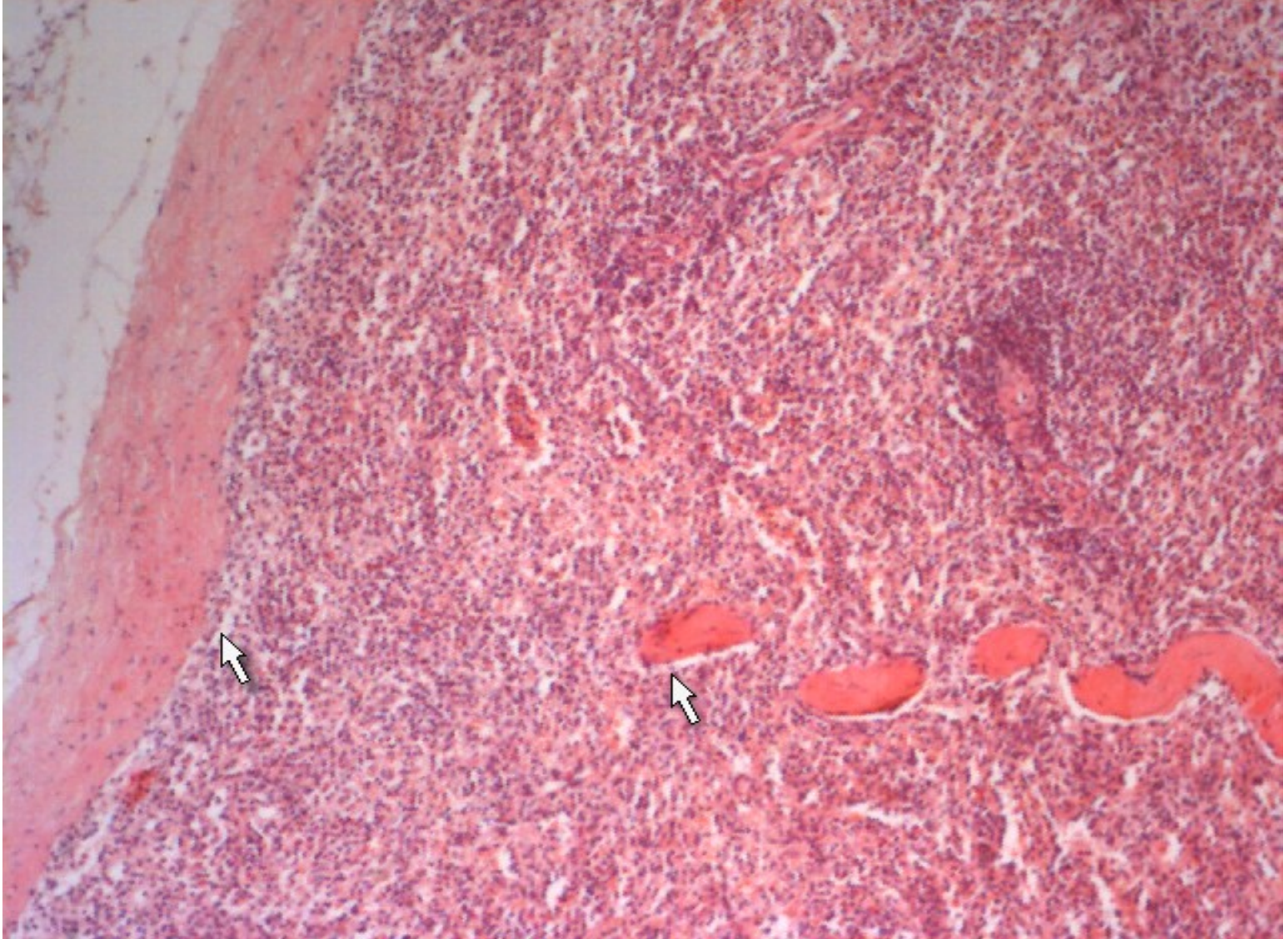
Postcapillary venules



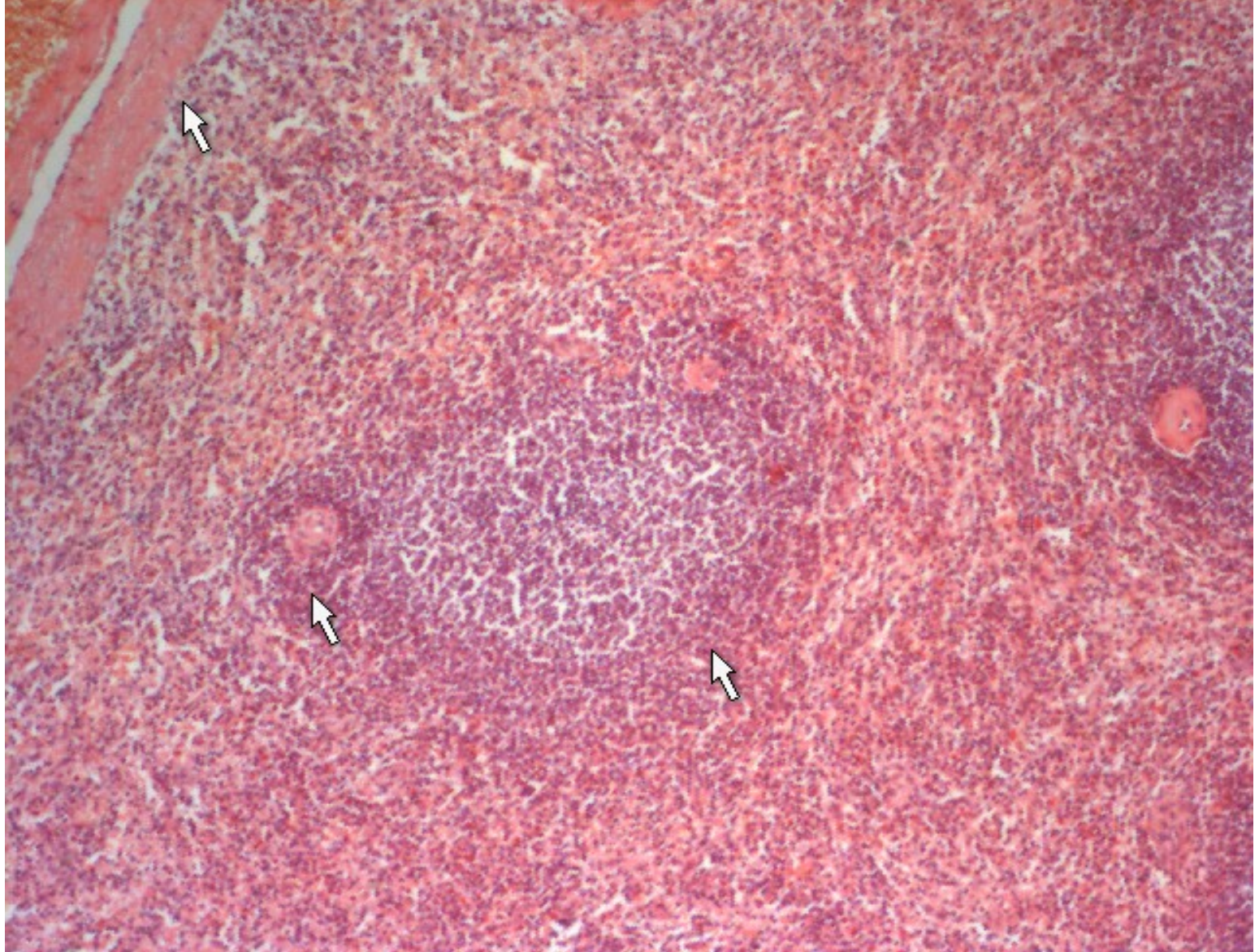
medulla



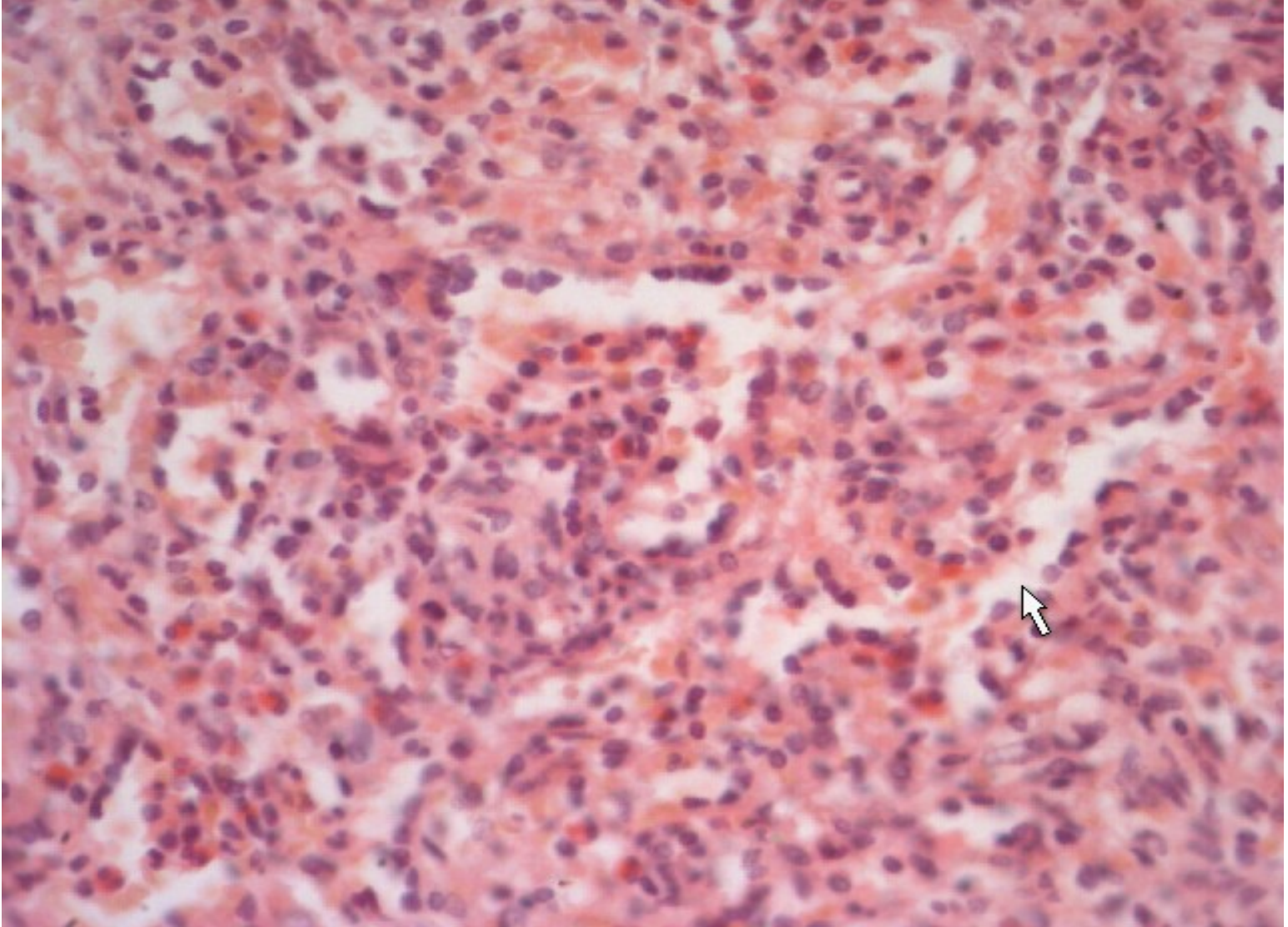
hilus



trabecula



Splenic corpuscle



Splenic cord and splenic sinus