

Digestive glands



Department of Histology and
Embryology of Jilin university

----Jiang Wenhua

1. general description of digestive glands

Small digestive glands

oesophageal glands

gastric glands

pyloric glands

intestinal glands

large digestive glands

salivary glands

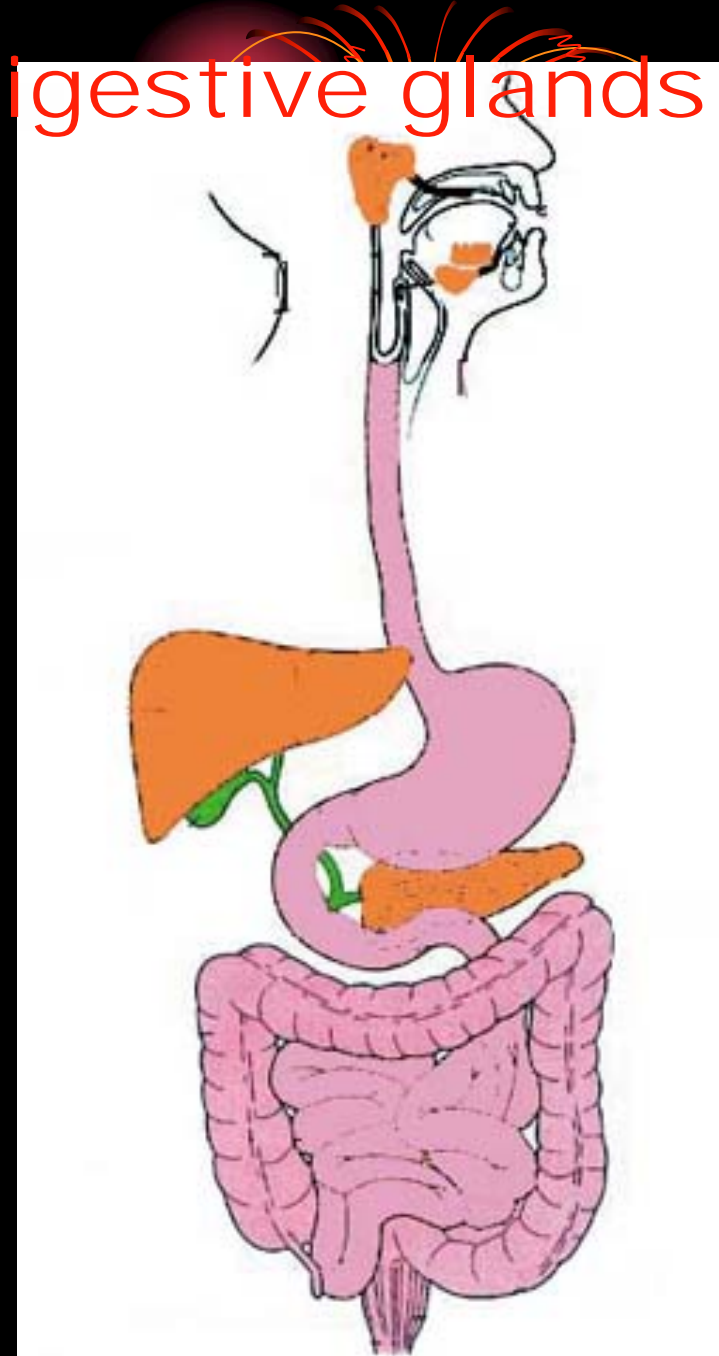
pancreas

liver

Function:

excretion digestive juice

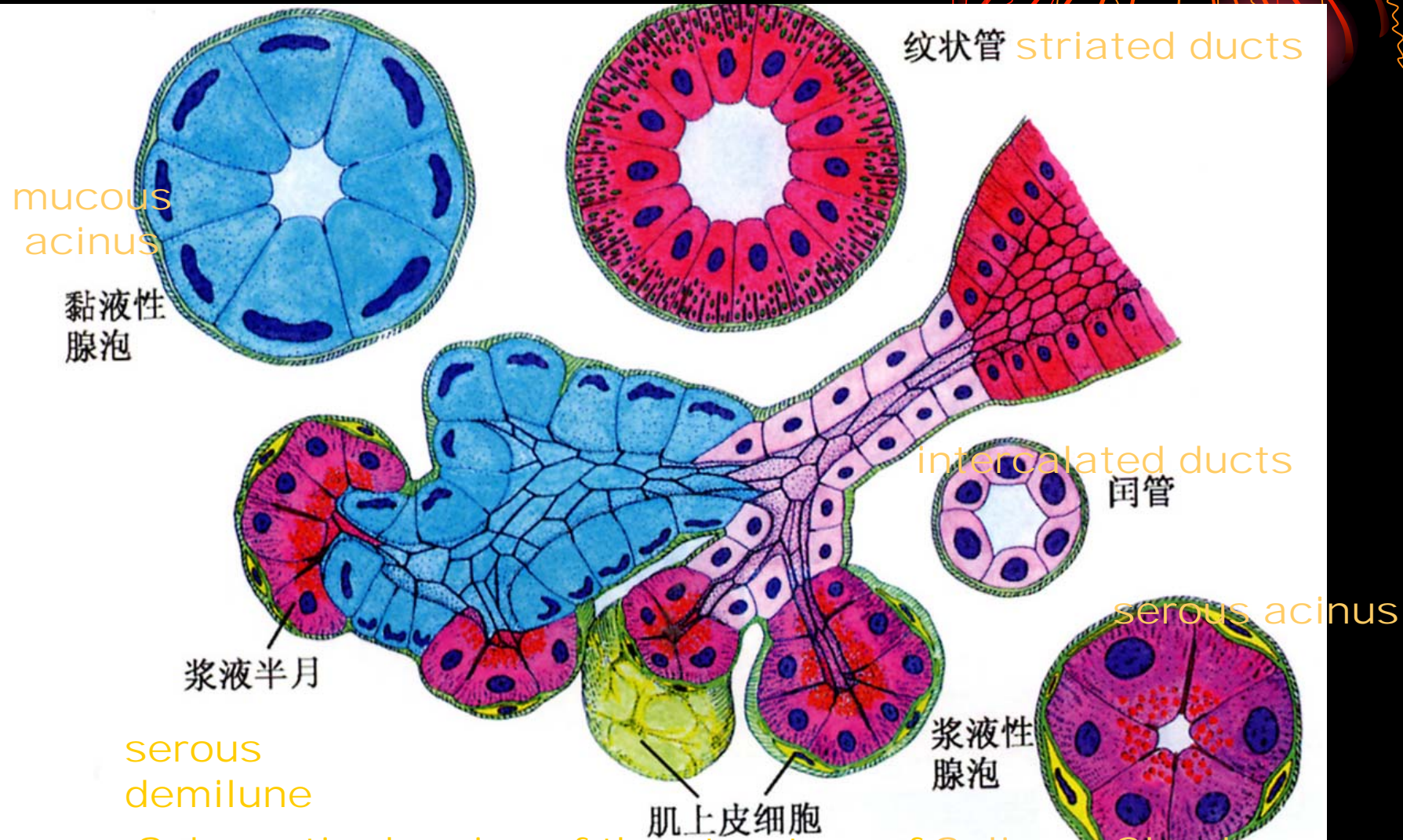
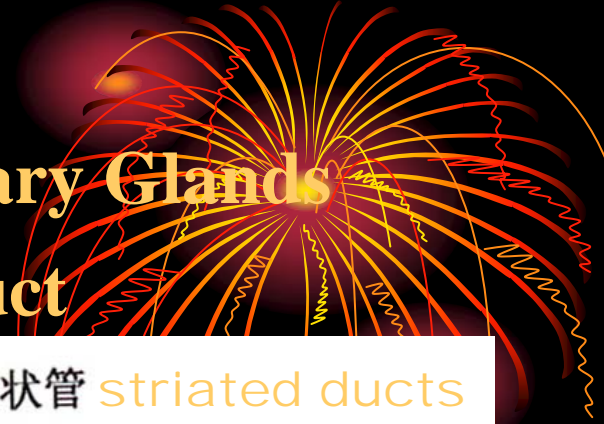incretion



2 salivary glands


2.1. The General Structure of Salivary Glands

being composed of acinus and duct



Schematic drawing of the structure of Salivary Glands

2.1.1 acinus

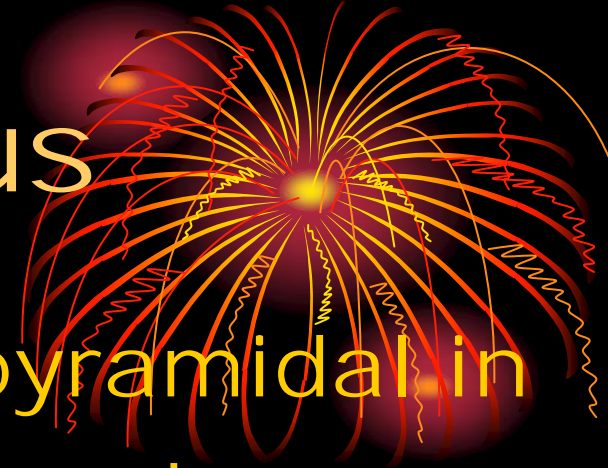

(1) serous acinus

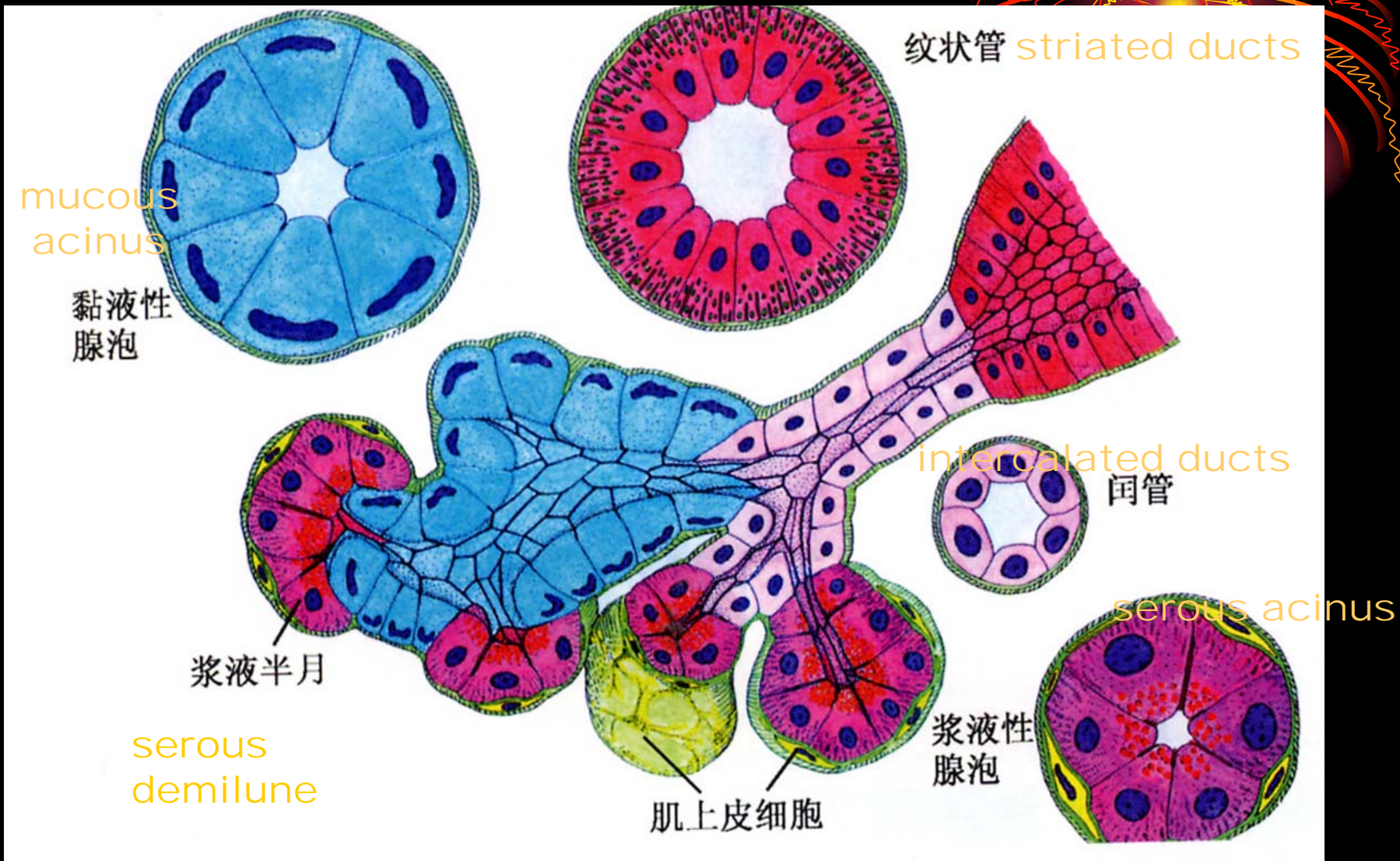
(2) mucous acinus

(3) mixed acinus

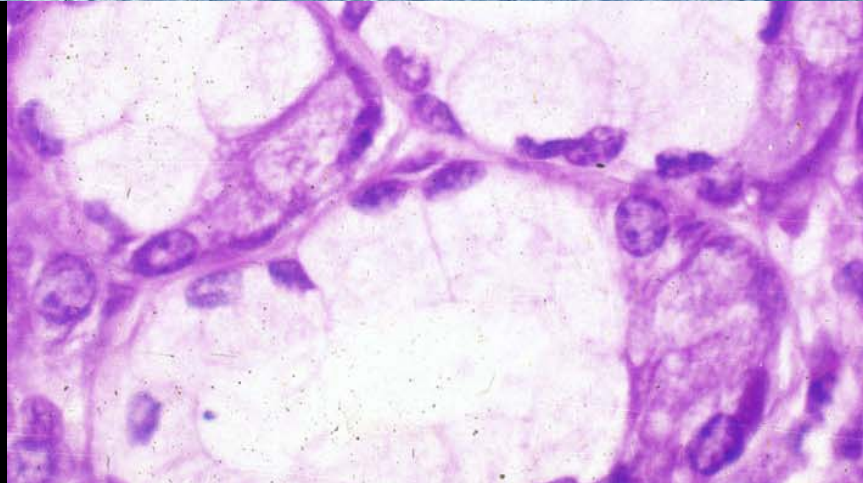
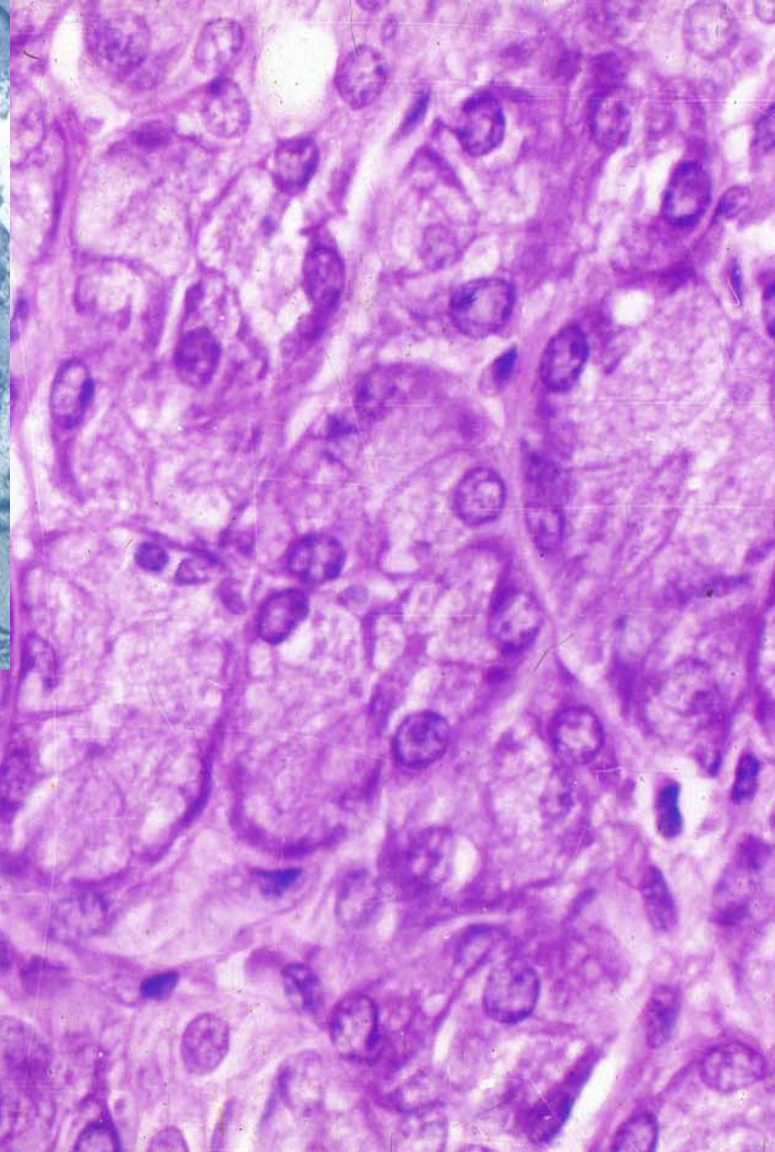
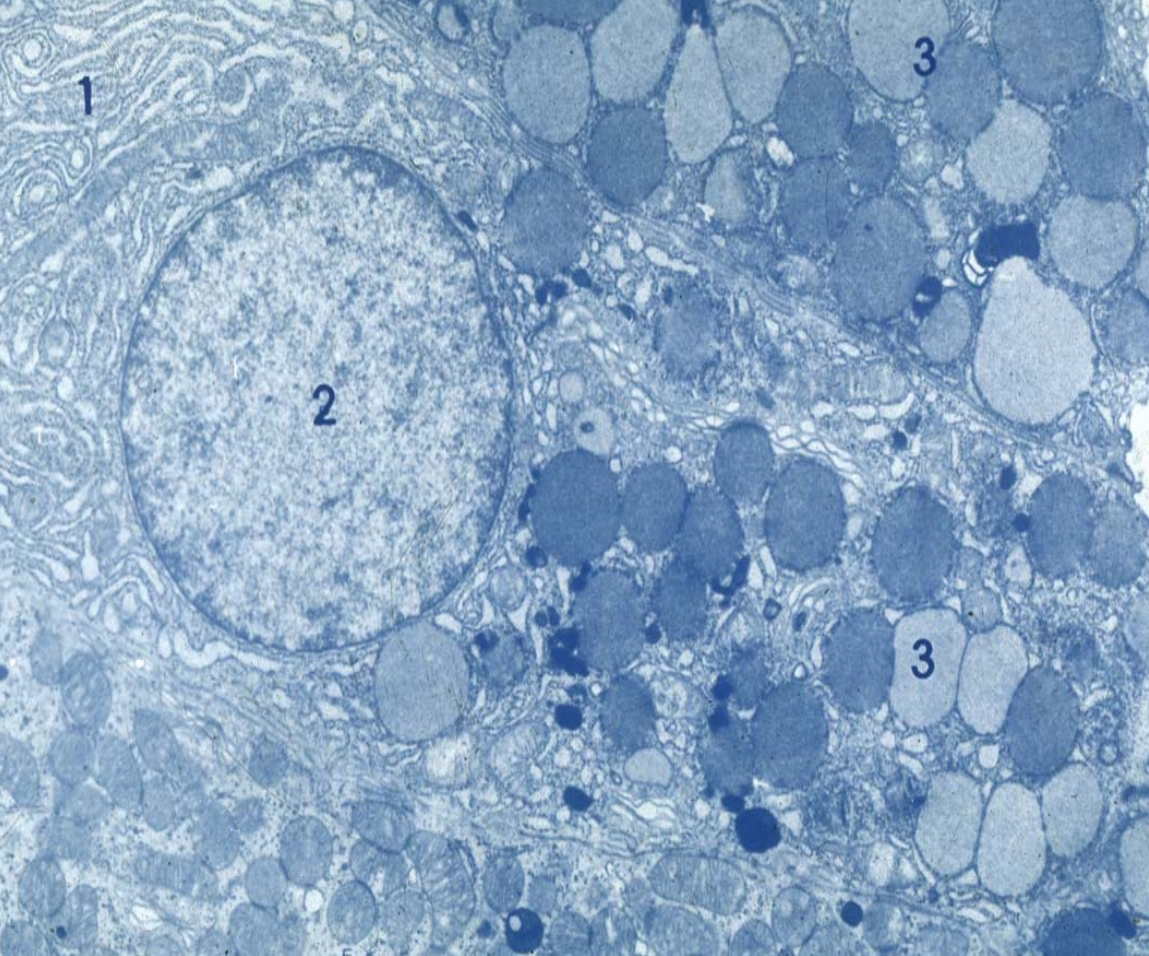
serous acinus



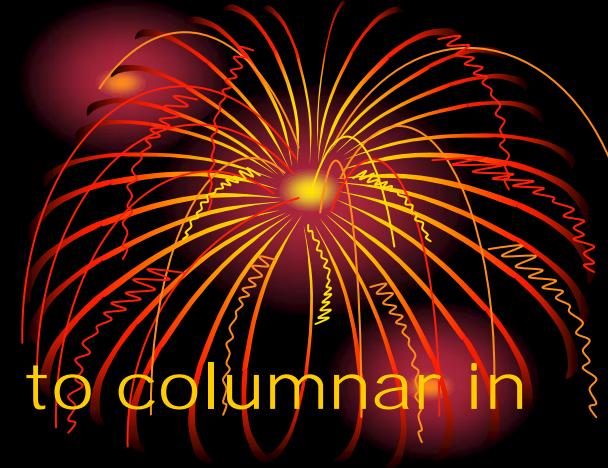- Serous cells are usually pyramidal in shape, with a broad base and a narrow apical surface .They exhibit characteristics of protein-secreting cells. Adjacent secretory cells are joined together and usually form a spherical mass of cells called acinus, with a lumen in the center .



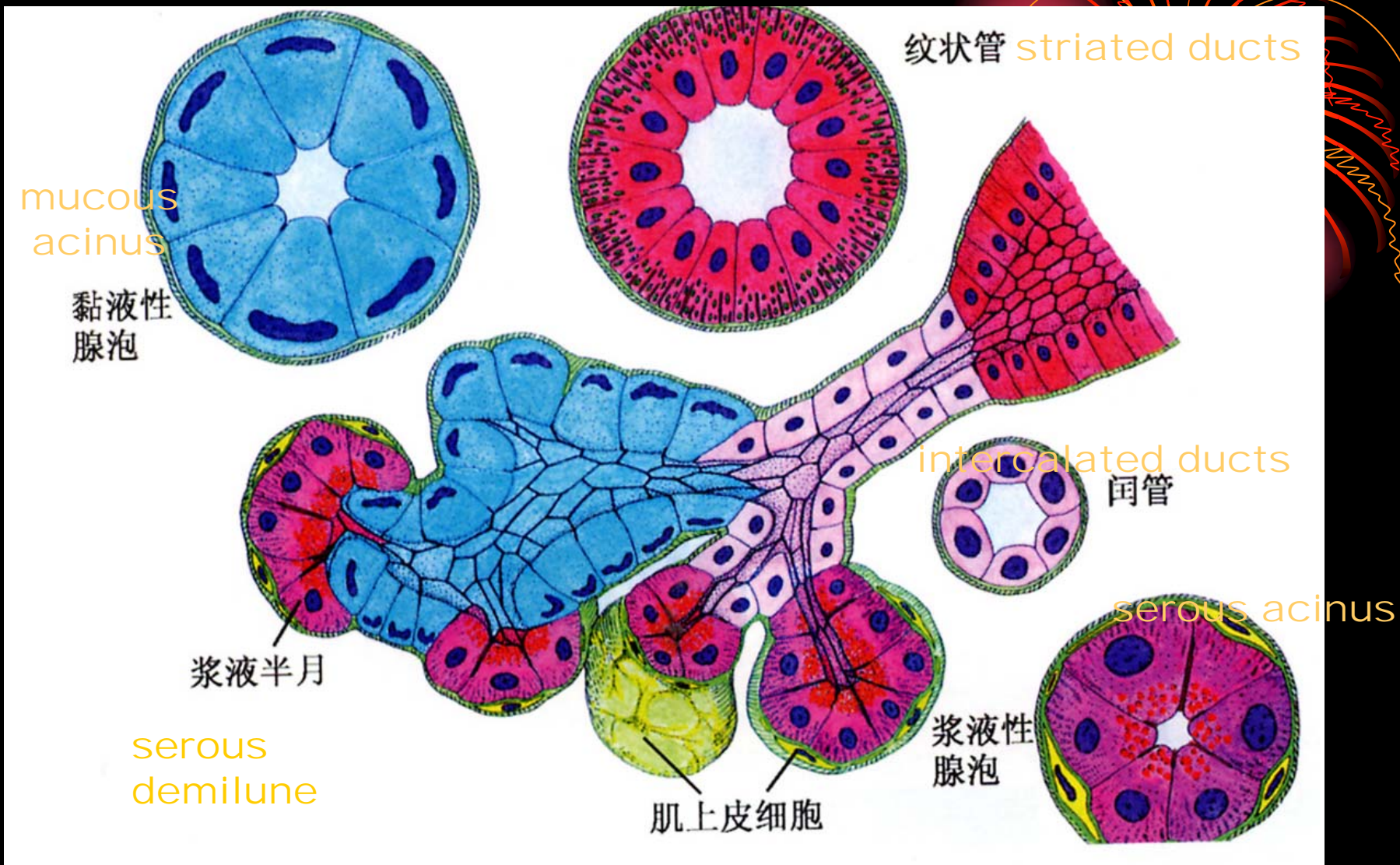Schematic drawing of the structure of Salivary Glands



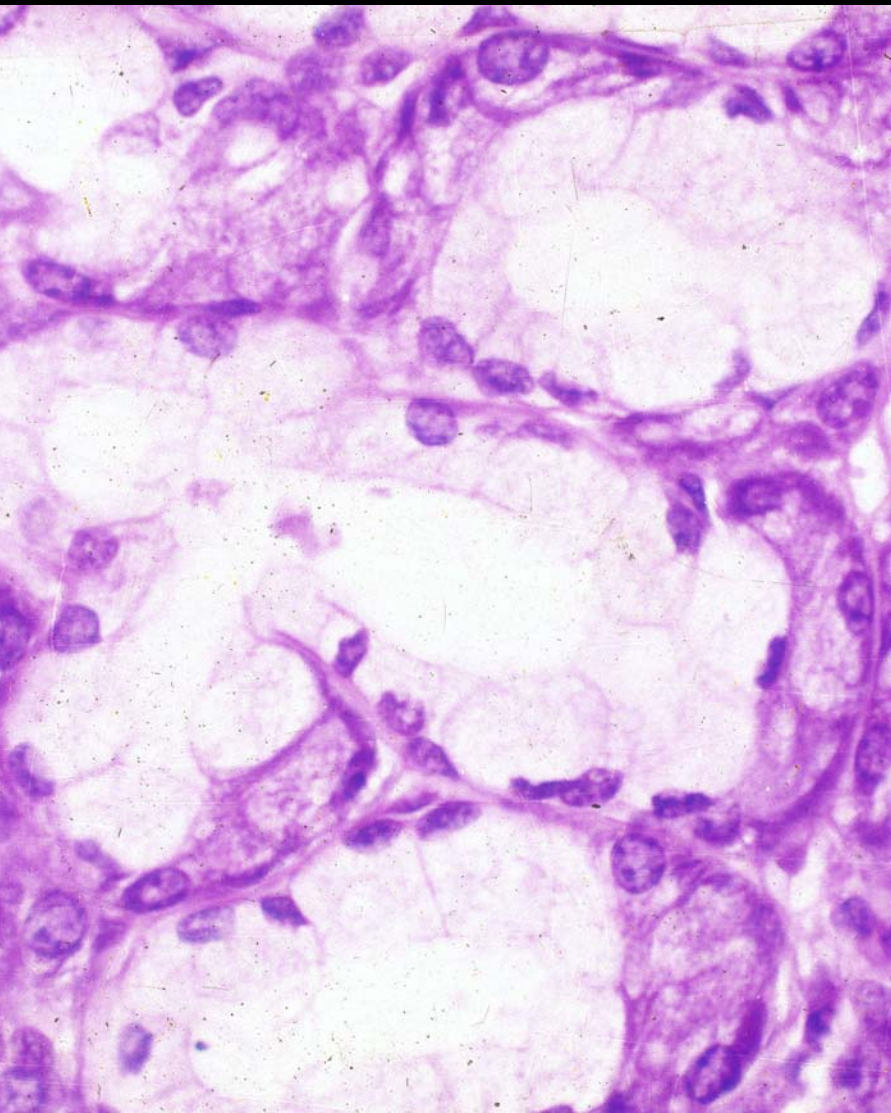
mucous cells



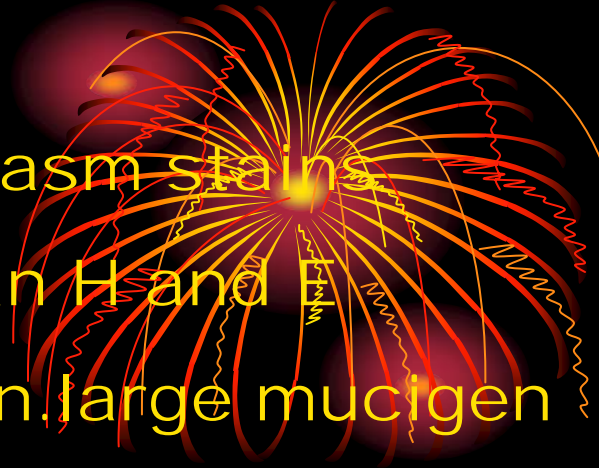Mucous cells are usually cuboidal to columnar in shape; their nuclei are oval and pressed toward the bases of the cells. They exhibit the characteristics of mucus-secreting cells , containing glycoproteins important for the moistening and lubricating functions of the saliva.

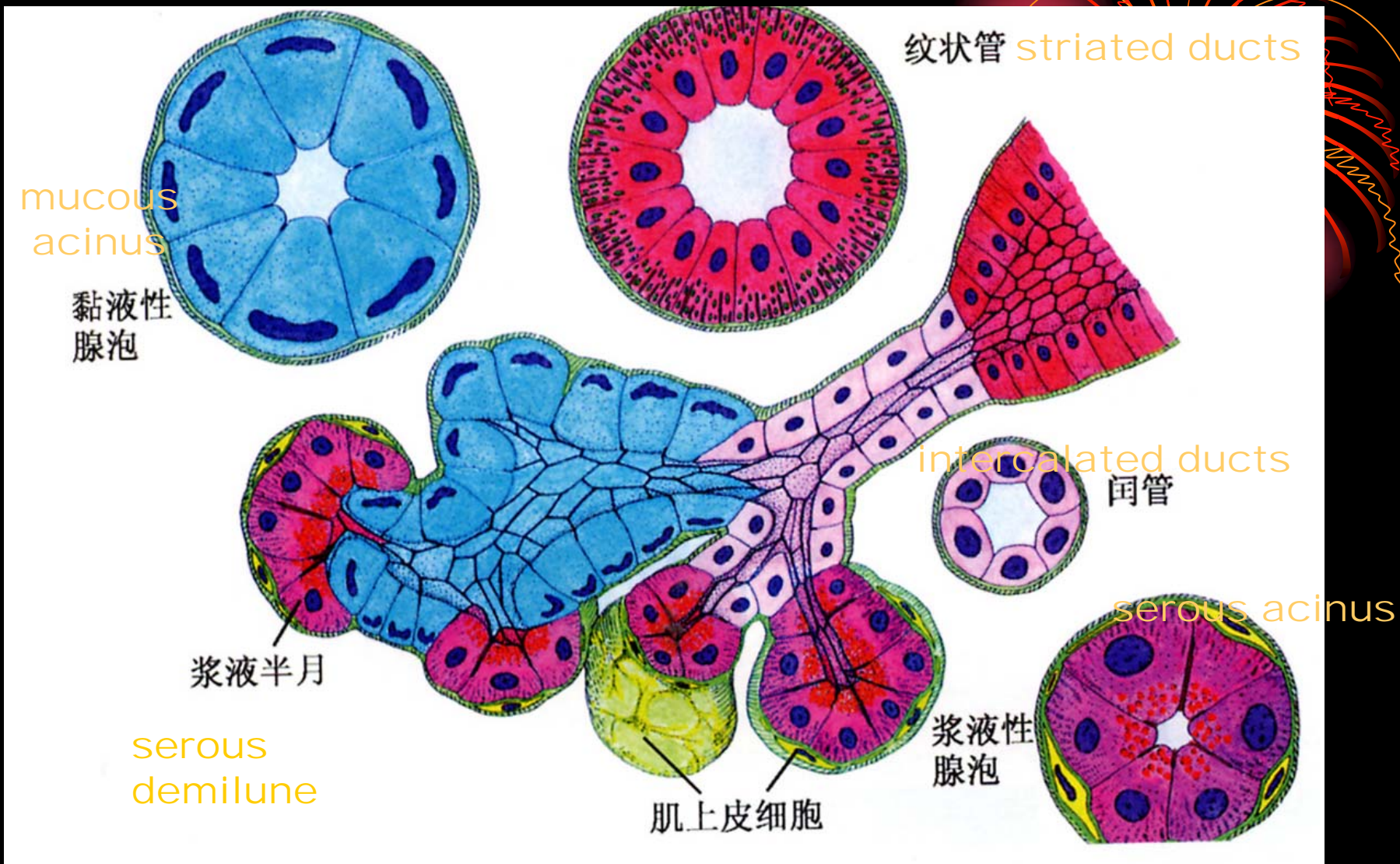


Schematic drawing of the structure of Salivary Glands

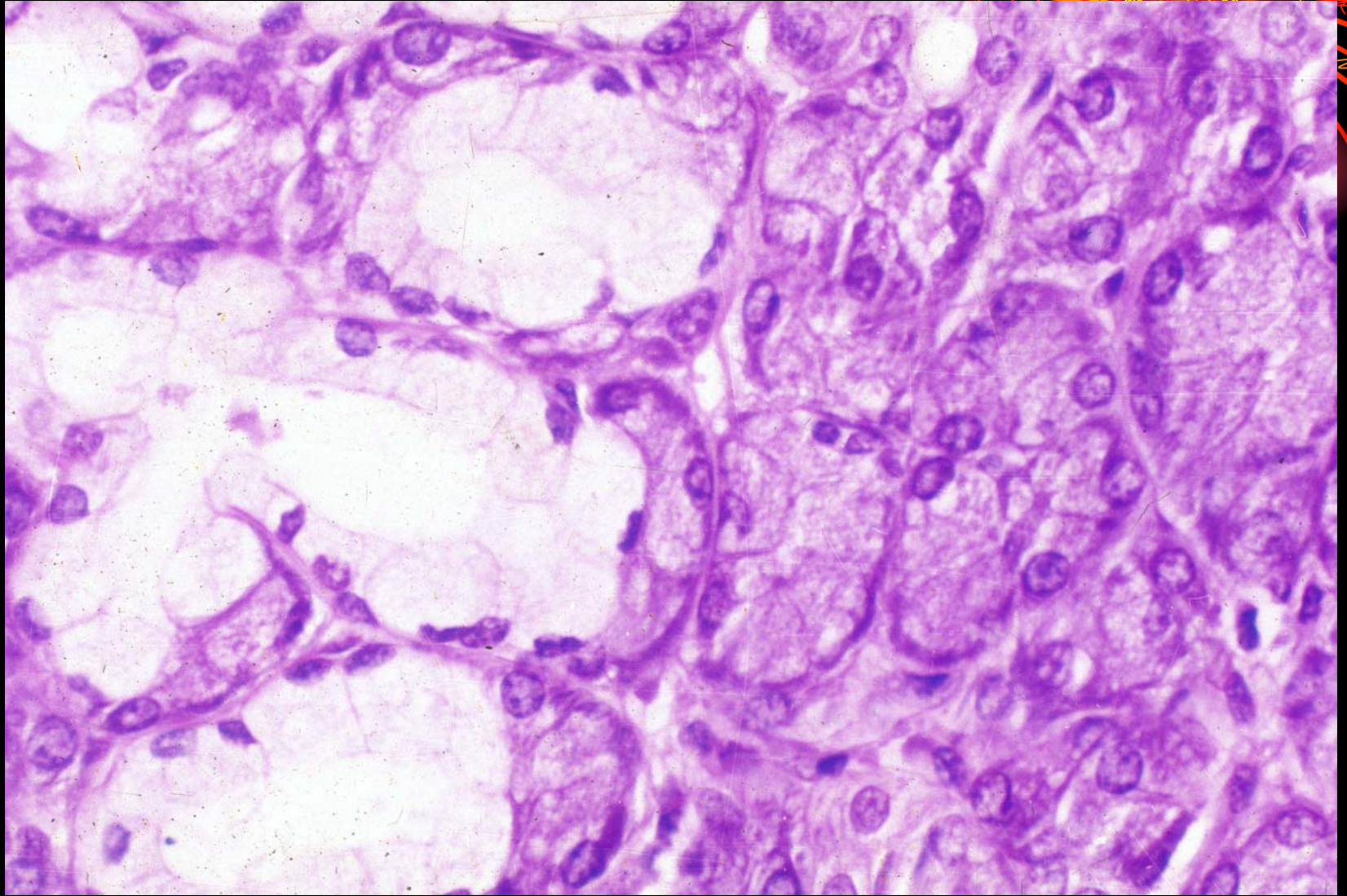


The cytoplasm stain lighter in an H and E preparation. Large mucigen granules are present in the apical cytoplasm, since the mucigen granules are not well preserved in routine preparations. The cytoplasm has a foamy pattern under a light microscope.





Schematic drawing of the structure of Salivary Glands



2.1.2 ducts

(1) intercalated ducts

squamous to low cuboidal epithelium

(2) secretory ducts (striated ducts)

columnar epithelium

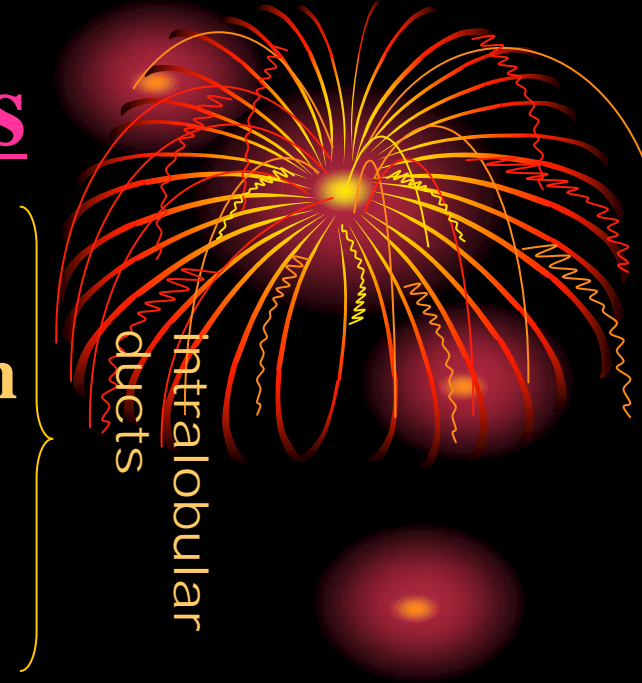function: ion-transporting

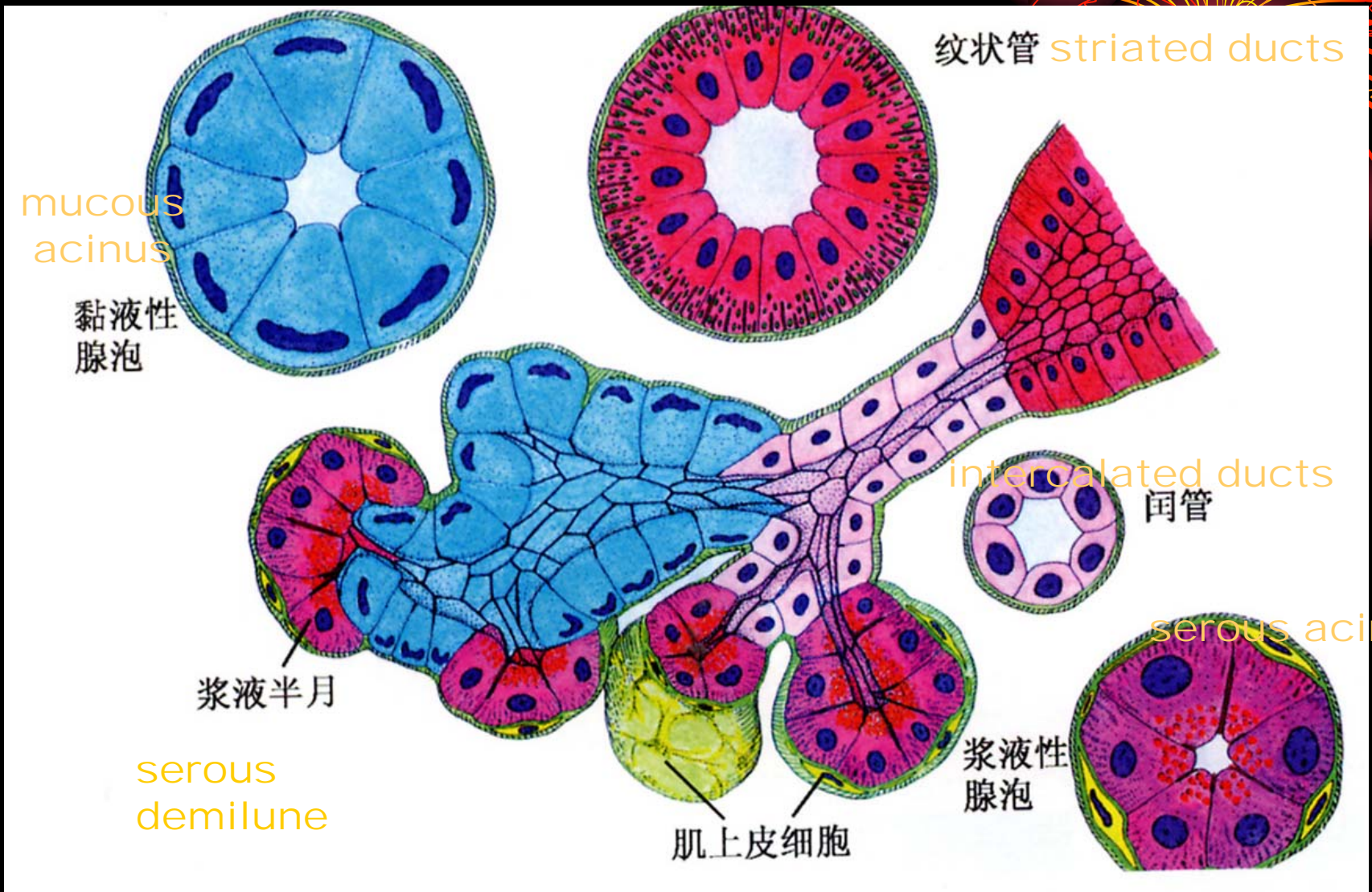
(3) interlobar ducts

stratified cuboidal to columnar epithelium

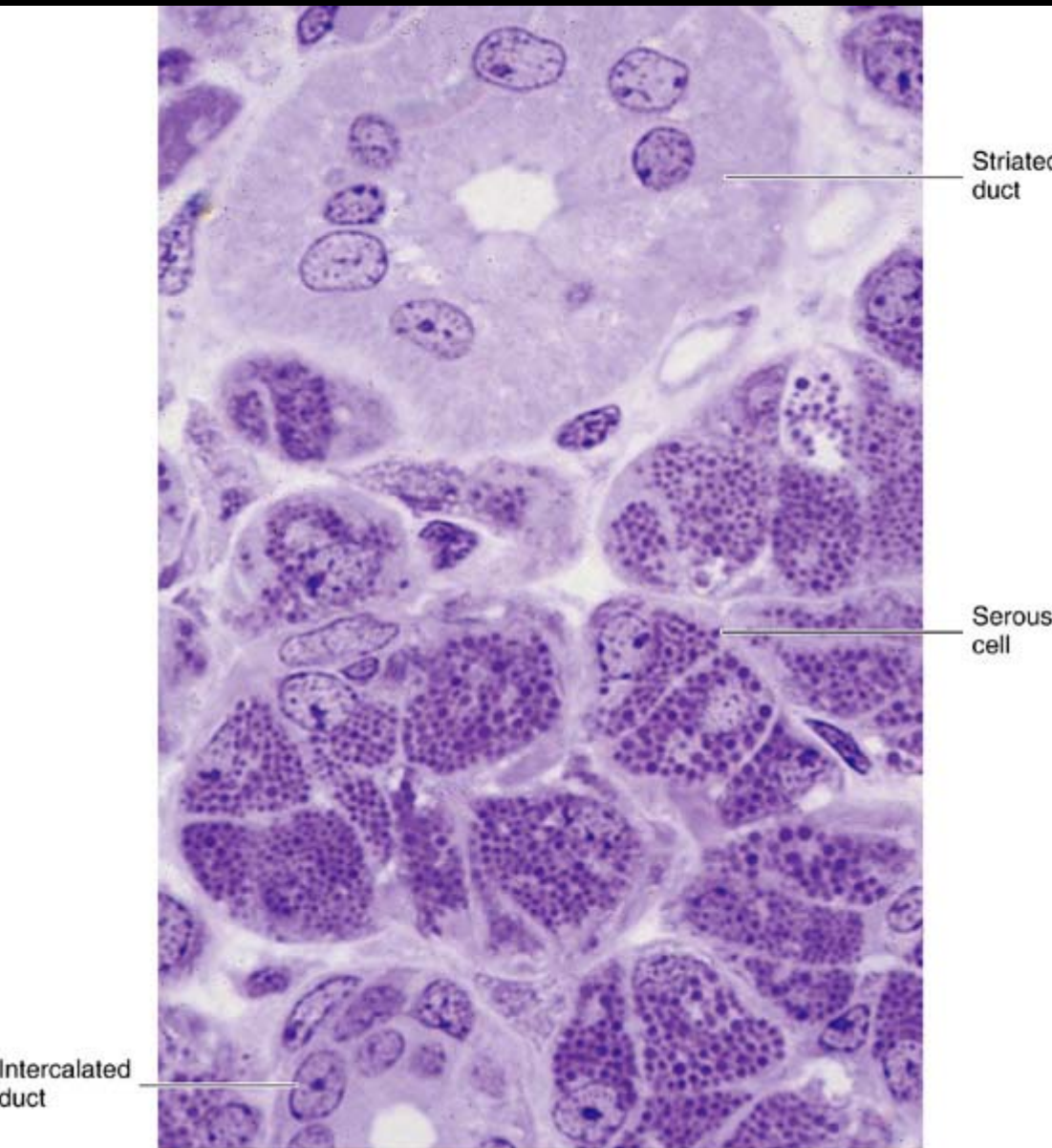
(4) main ducts empties into the oral cavity ,lined with

nonkeratinized-stratified squamous epithelium

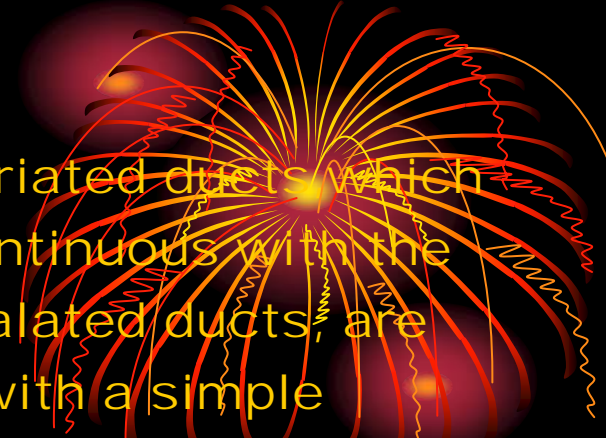




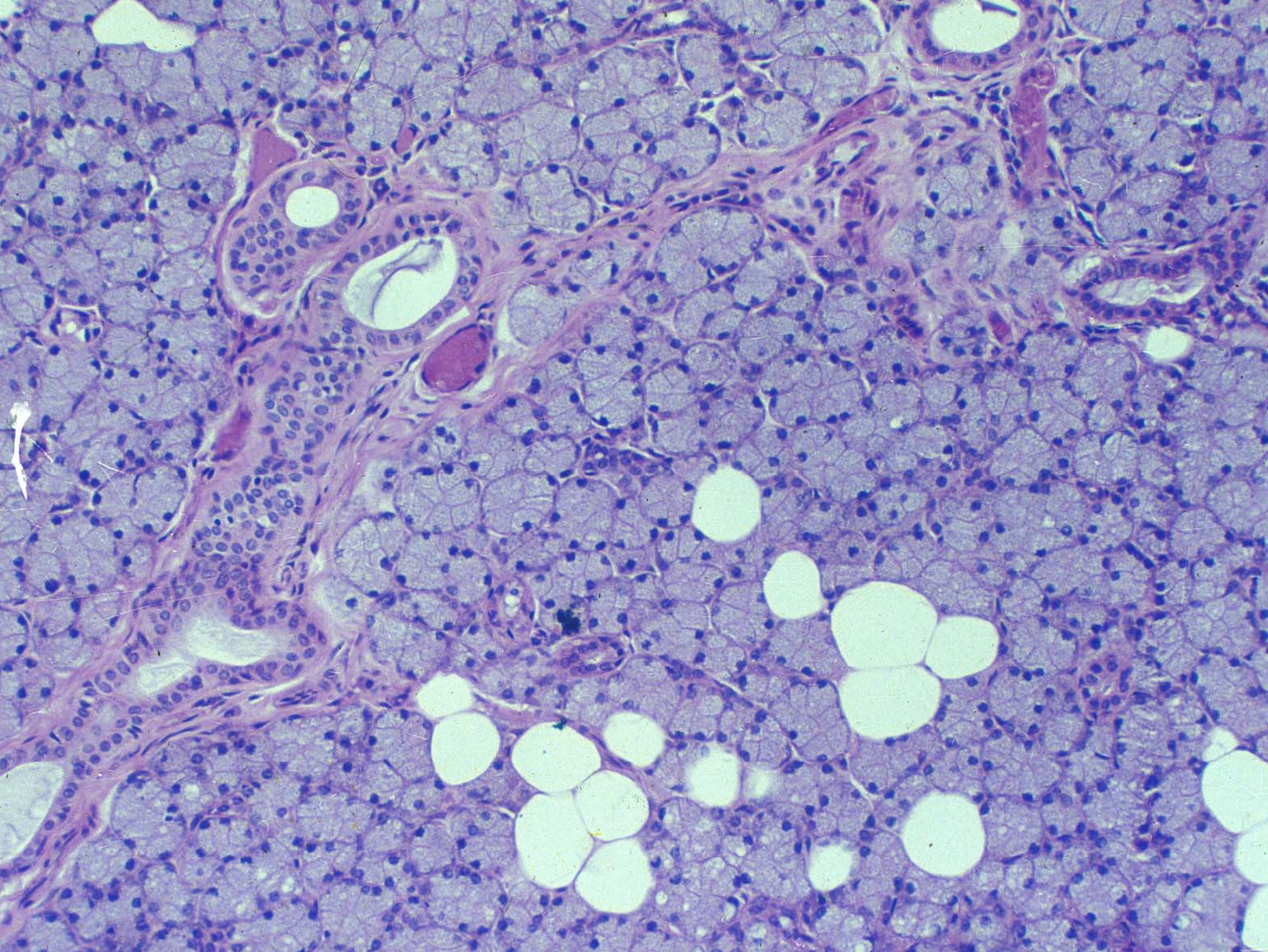
Schematic drawing of the structure of Salivary Glands




The striated ducts which are continuous with the intercalated ducts, are lined with a simple columnar epithelium. as the secretion from the acini passes through the striated ducts, the epithelium can re-absorb sodium and water from the lumen to the interstitium, and transport potassium into the saliva, thus changing the consistency of the saliva



Photomicrograph of a parotid gland
Intralobular (intercalated and striated) ducts are also present.

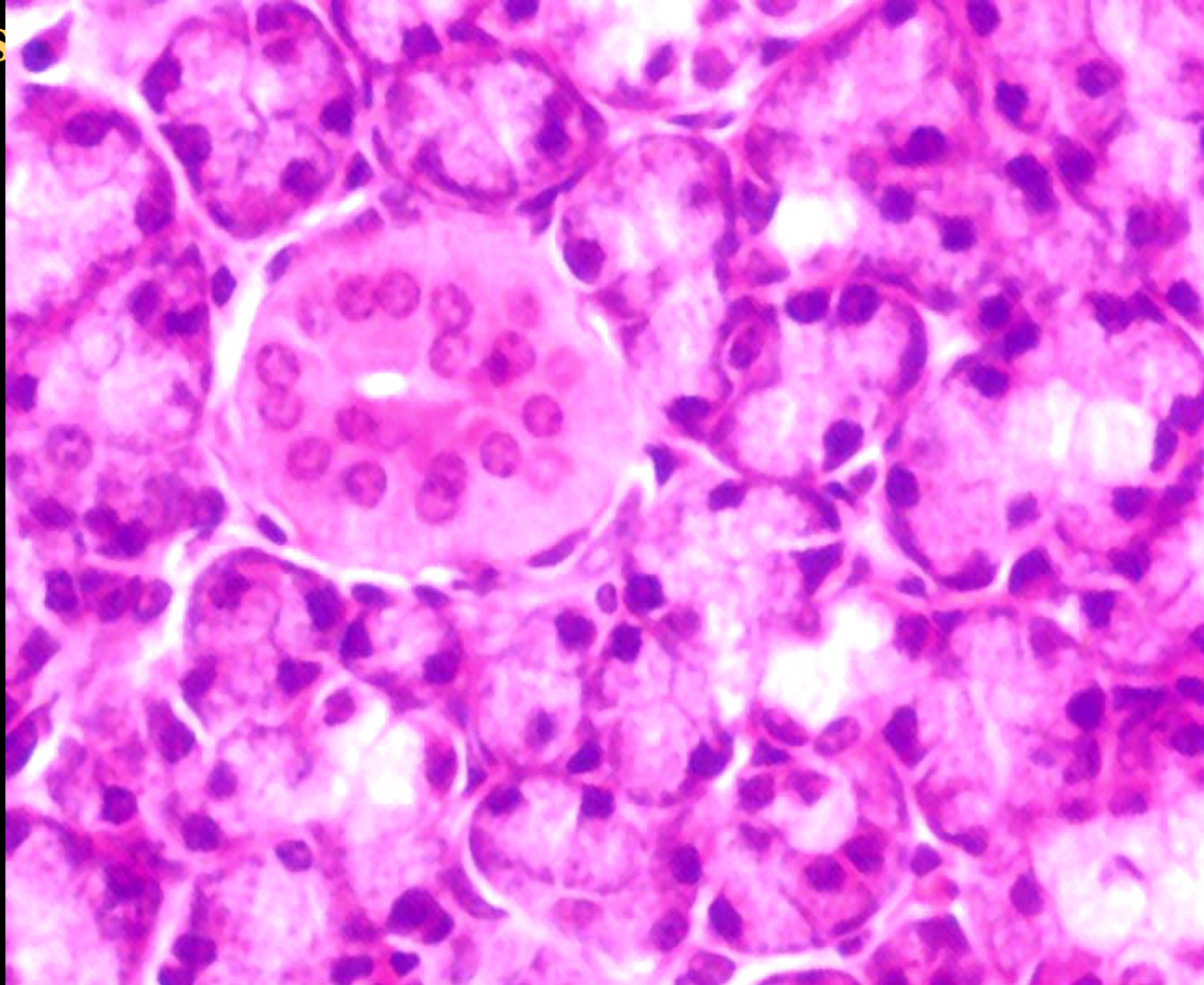


2. Structure Characteristics of Three pair of Salivaries

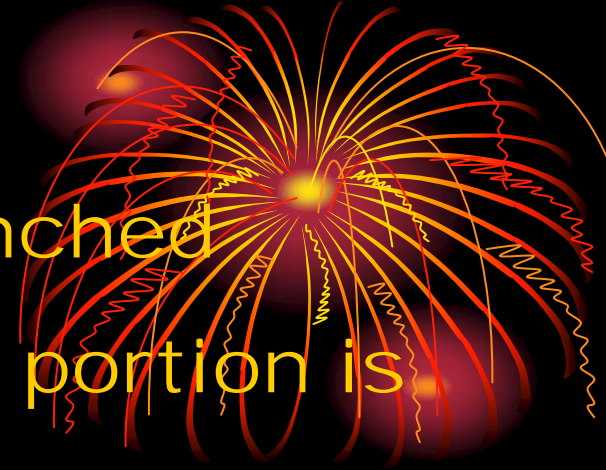

2.1 Parotid glands serous acinus

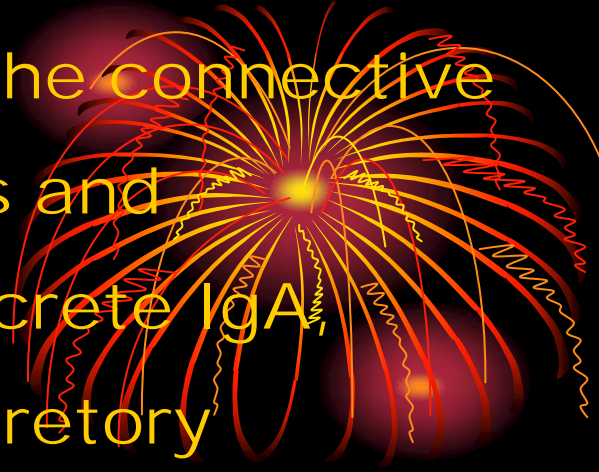Secretion: Ptyalin



- The parotid gland is a branched acinar gland; its secretory portion is composed exclusively of serous cells containing secretory granules that are rich in proteins and have a high amylase activity. This activity is responsible for most of the hydrolysis of ingested carbohydrates.

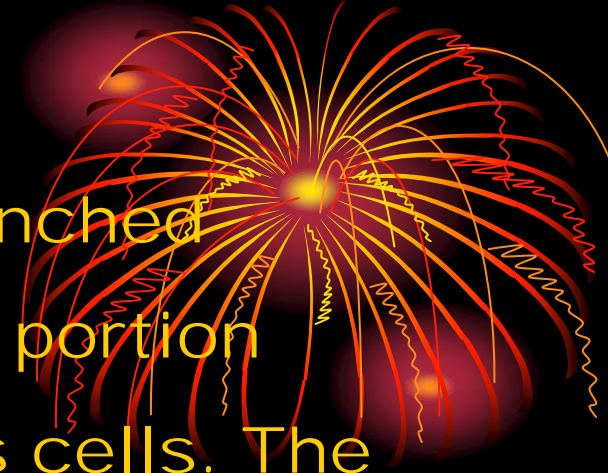

- As in other large salivary glands, the connective tissue contains many plasma cells and lymphocytes. The plasma cells secrete IgA, which forms a complex with a secretory component synthesized by the serous acinar, intercalated duct, and striated duct cells. The IgA-rich secretory complex released into the saliva is resistant to enzymatic digestion and constitutes an immunologic defense mechanism against pathogens in the oral cavity.

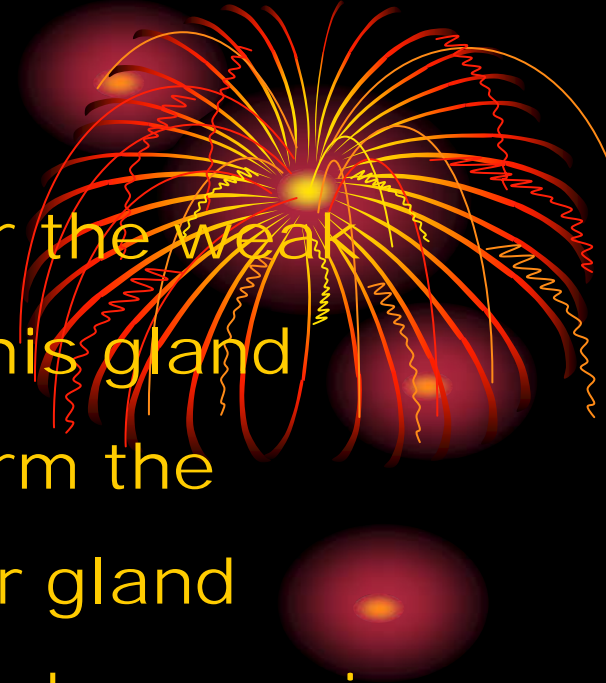


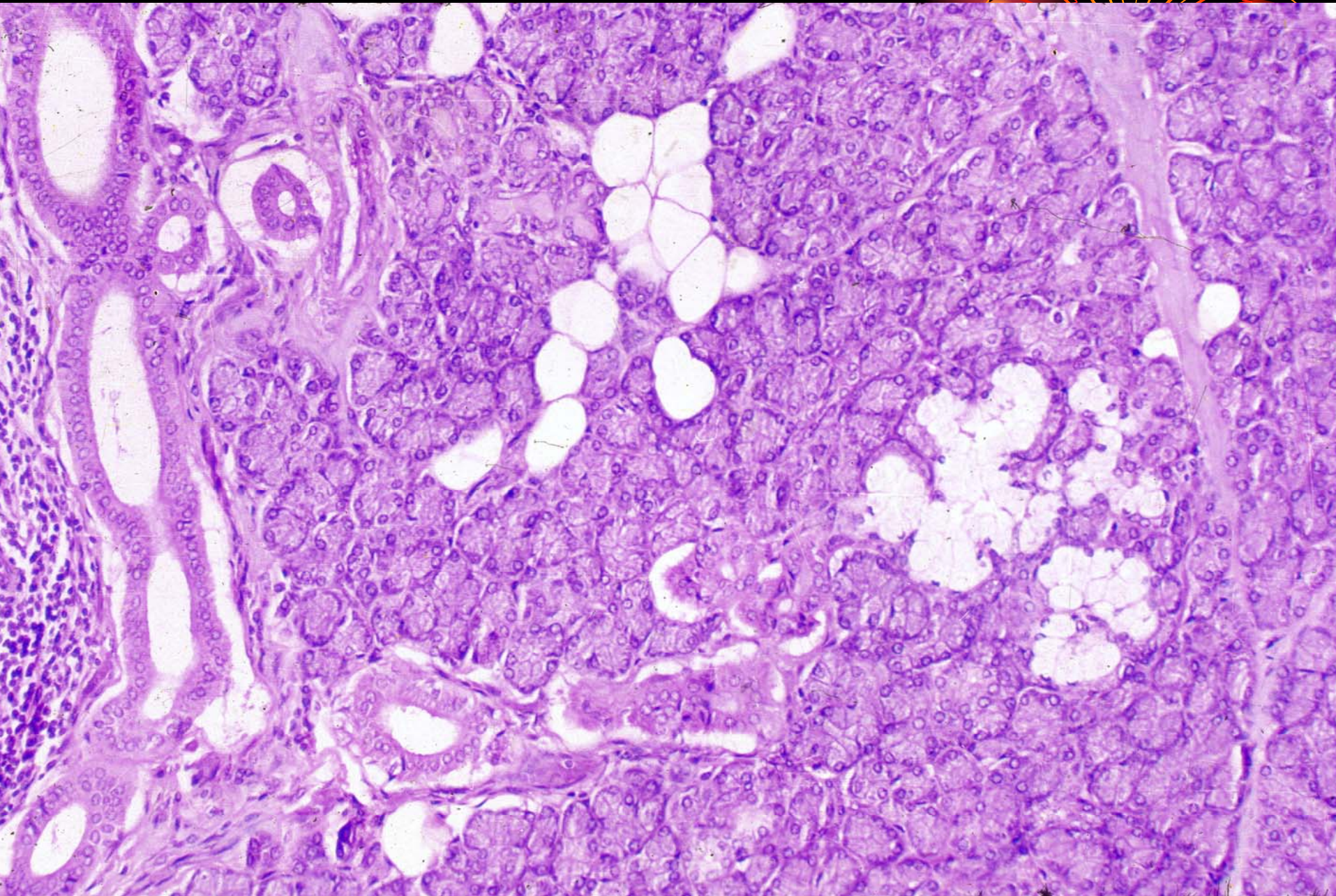
2.2 submandibular glands :

- The submandibular gland is a branched tubuloacinar gland ; its secretory portion contains both mucous and serous cells. The serous cells are the main component of this gland and are easily distinguished from mucous cells by their rounded nuclei and basophilic cytoplasm. In humans, 90% of the endpieces of the submandibular gland are serous acinar, whereas 10% consist of mucous tubules with serous demilunes.




- Serous cells are responsible for the weak amylolytic activity present in this gland and its saliva. The cells that form the demilunes in the submandibular gland secrete the enzyme lysozyme, whose main activity is to hydrolyze the walls of certain bacteria.





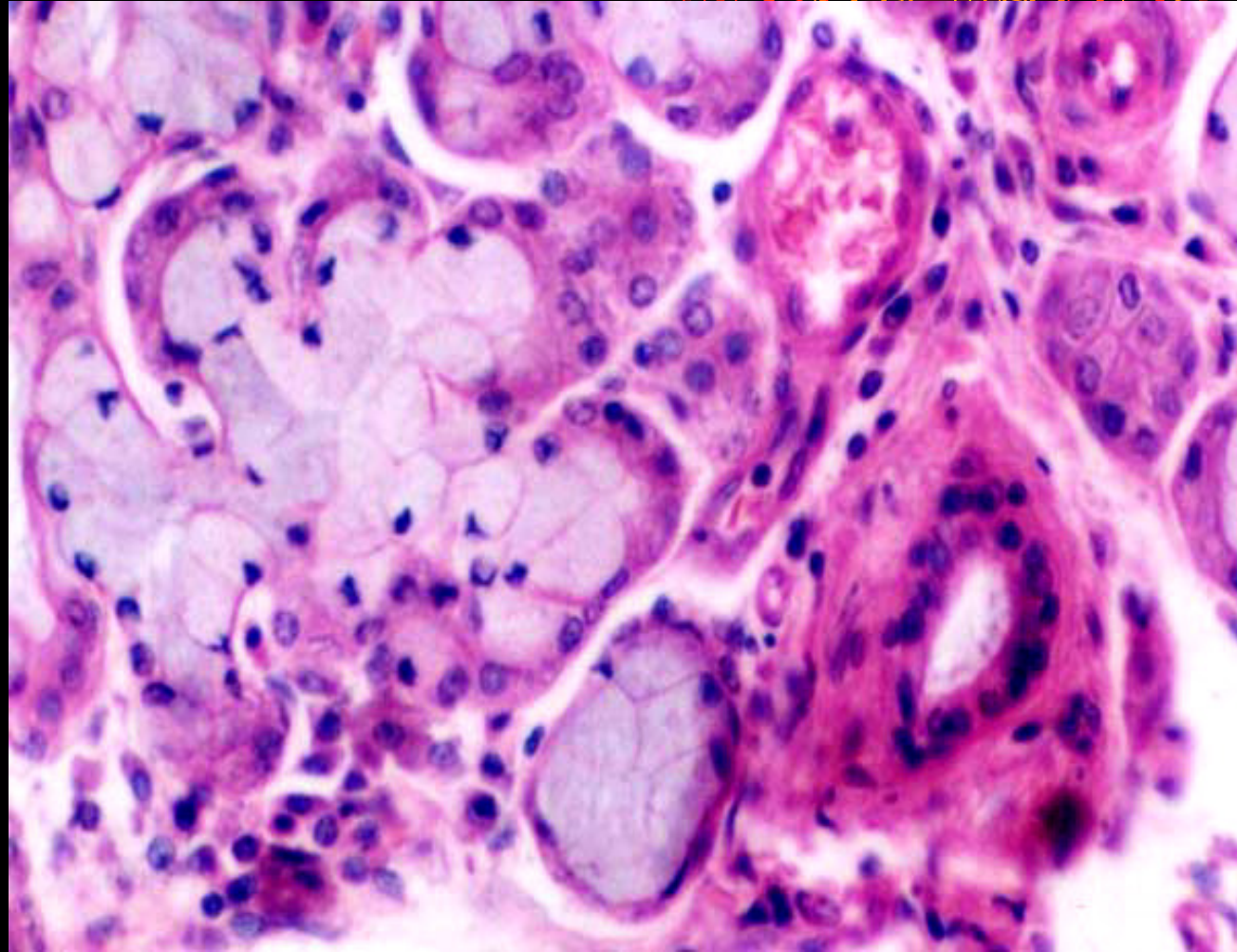
2.3 Sublingual glands

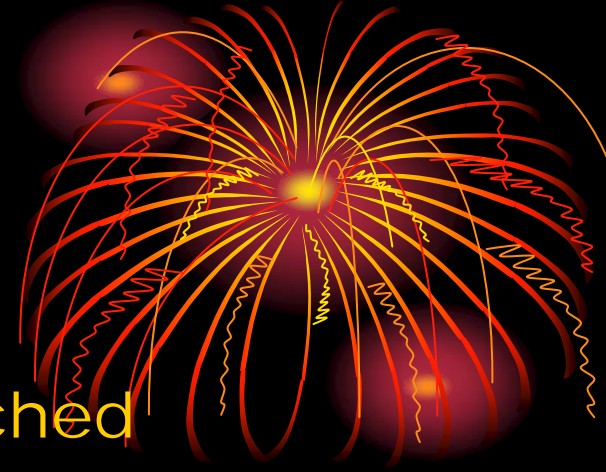

**main mucous type
and mixed type**

Secretion:

mainly mucous





- The sublingual gland, like the submandibular gland, is a branched tubuloacinar gland formed of serous and mucous cells. Mucous cells predominate in this gland; serous cells are present exclusively on demilunes of mucous tubules . As in the submandibular gland, cells that form the demilunes in this gland secrete lysozyme.

saliva

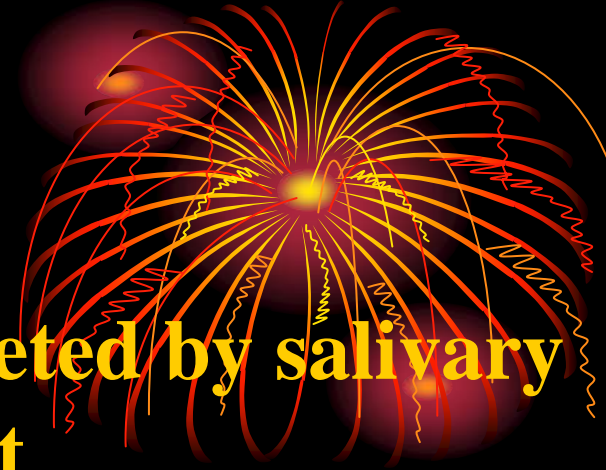
Saliva is a complex fluid that secreted by salivary glands. It contain much ingredient

Water of mucous--to lubricate cavity

**Salivary amylase --to hydrolyze starch or
carbohydrate**

Lysozyme--to hydrolyze the bacteria

it has digestive, lubricating and protective function



3 pancreas

1. The general structure of pancreas

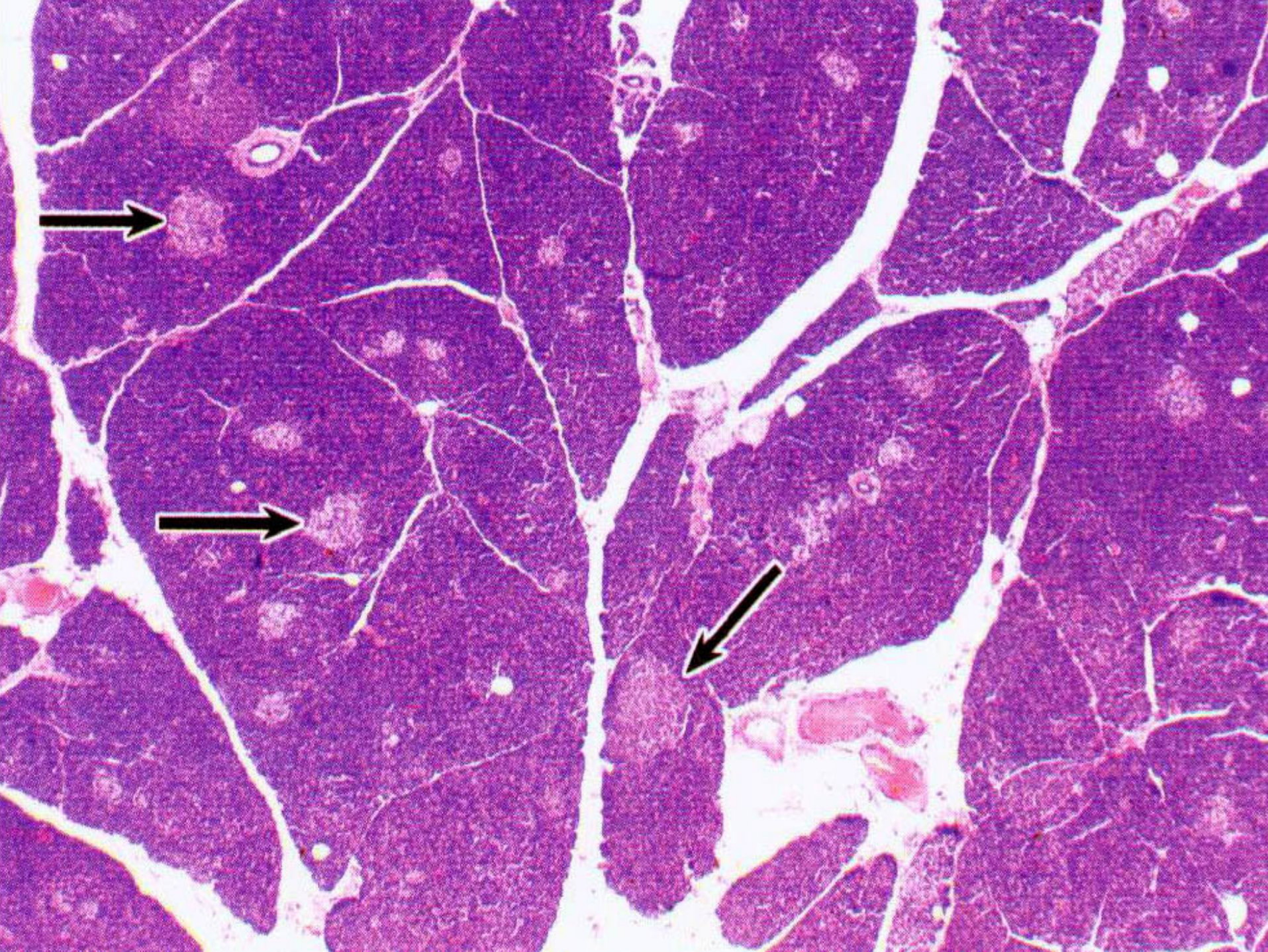


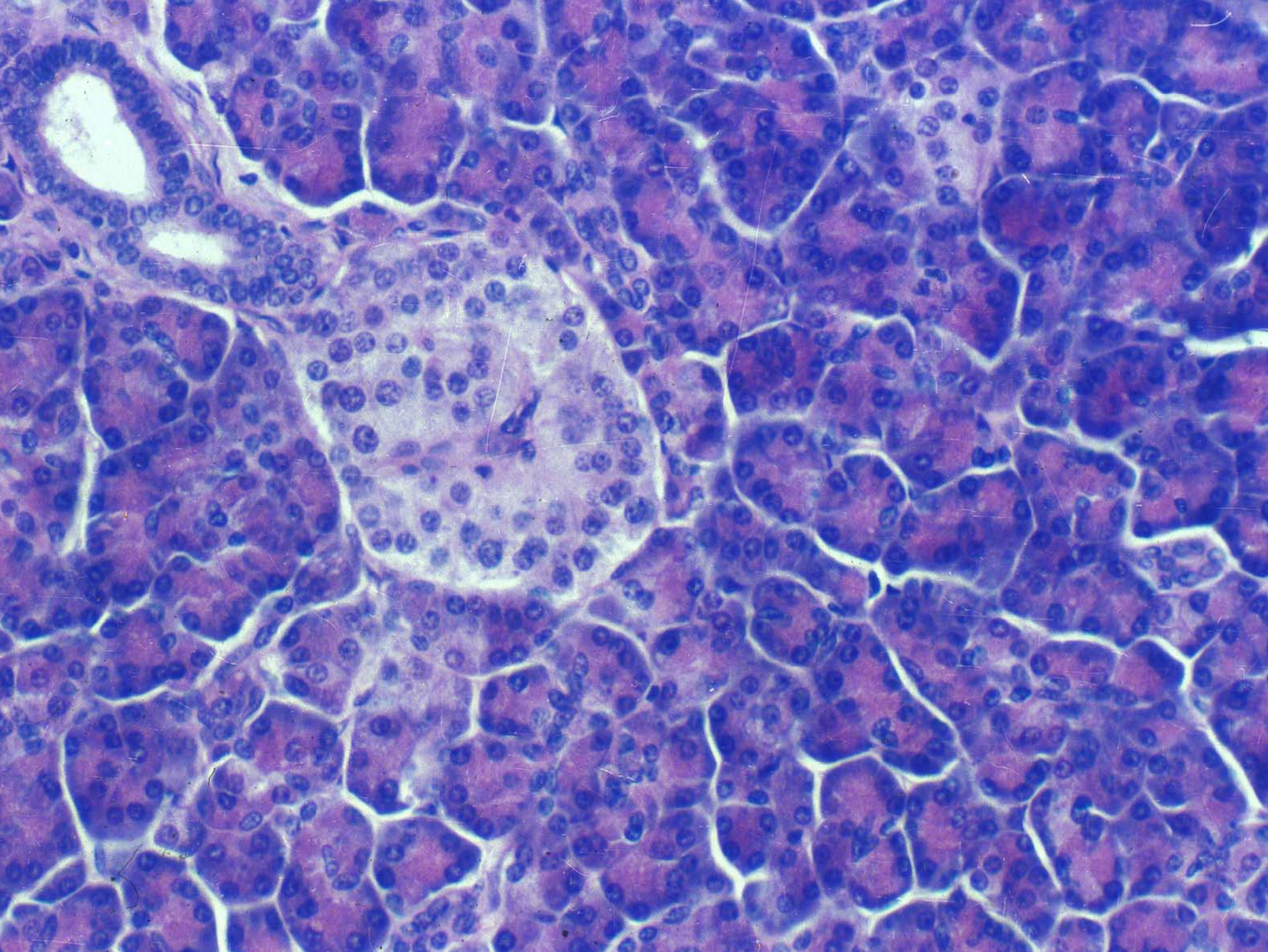
capsule : lamellar connective tissue

lobules:

Parenchyma : exocrine portion {
Acini
ducts

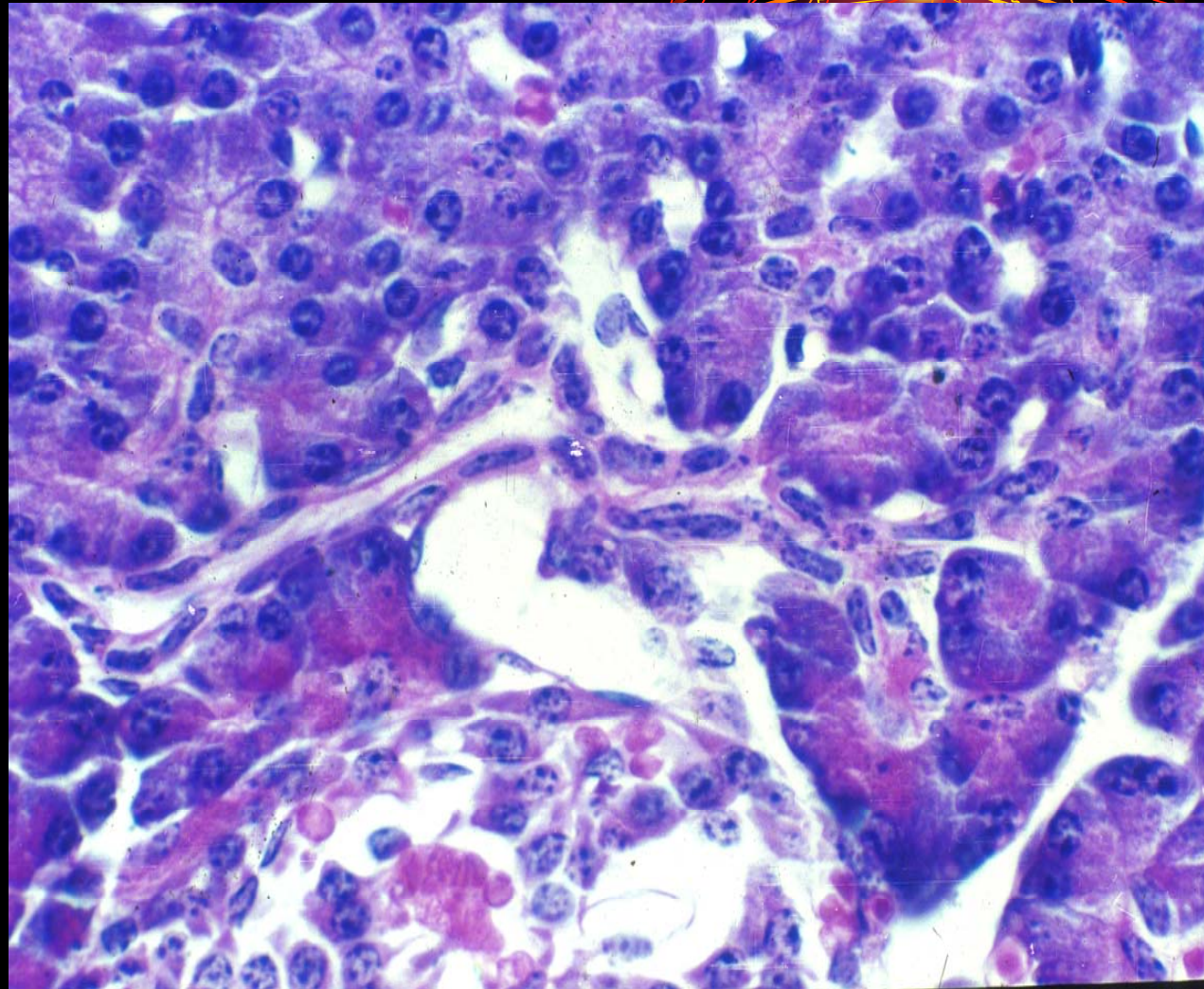
endocrine portion (pancreatic islets)





3.1 exocrine portion of the pancreas

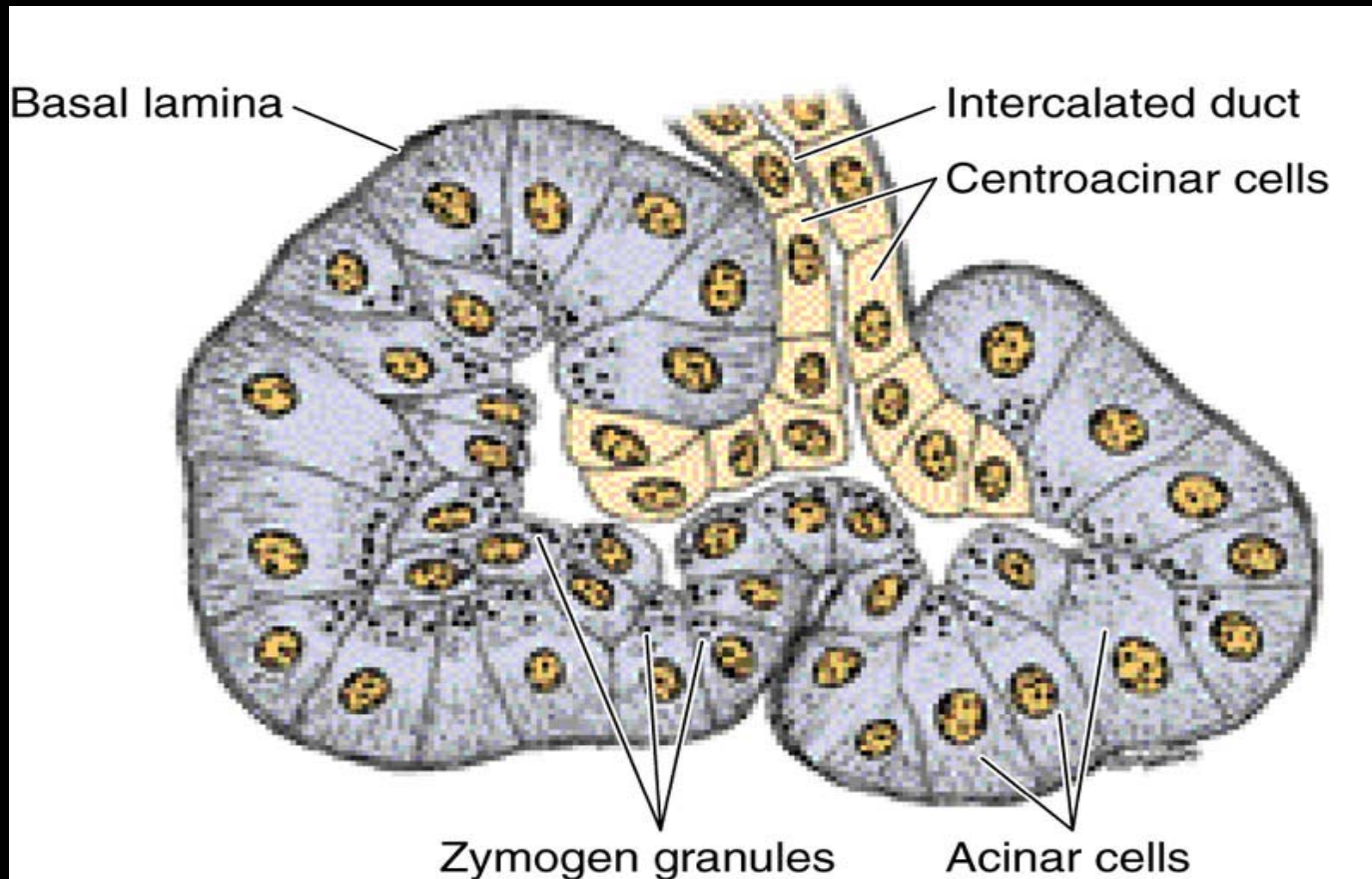
The exocrine portion of the pancreas is a compound acinar gland composed of secretory acini and ducts.



3.1.1 acini

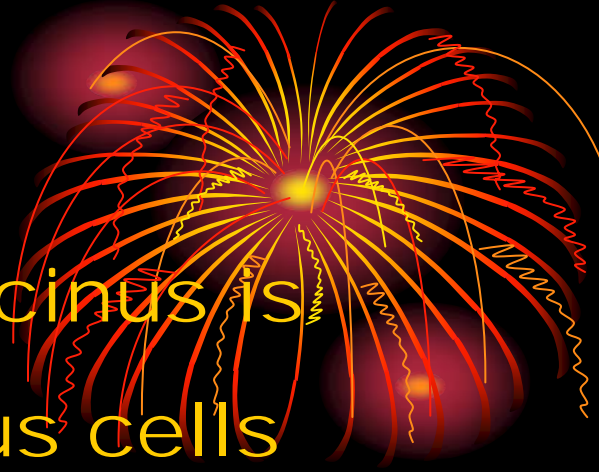
Structure: serous cells
typical protein-secreting cells

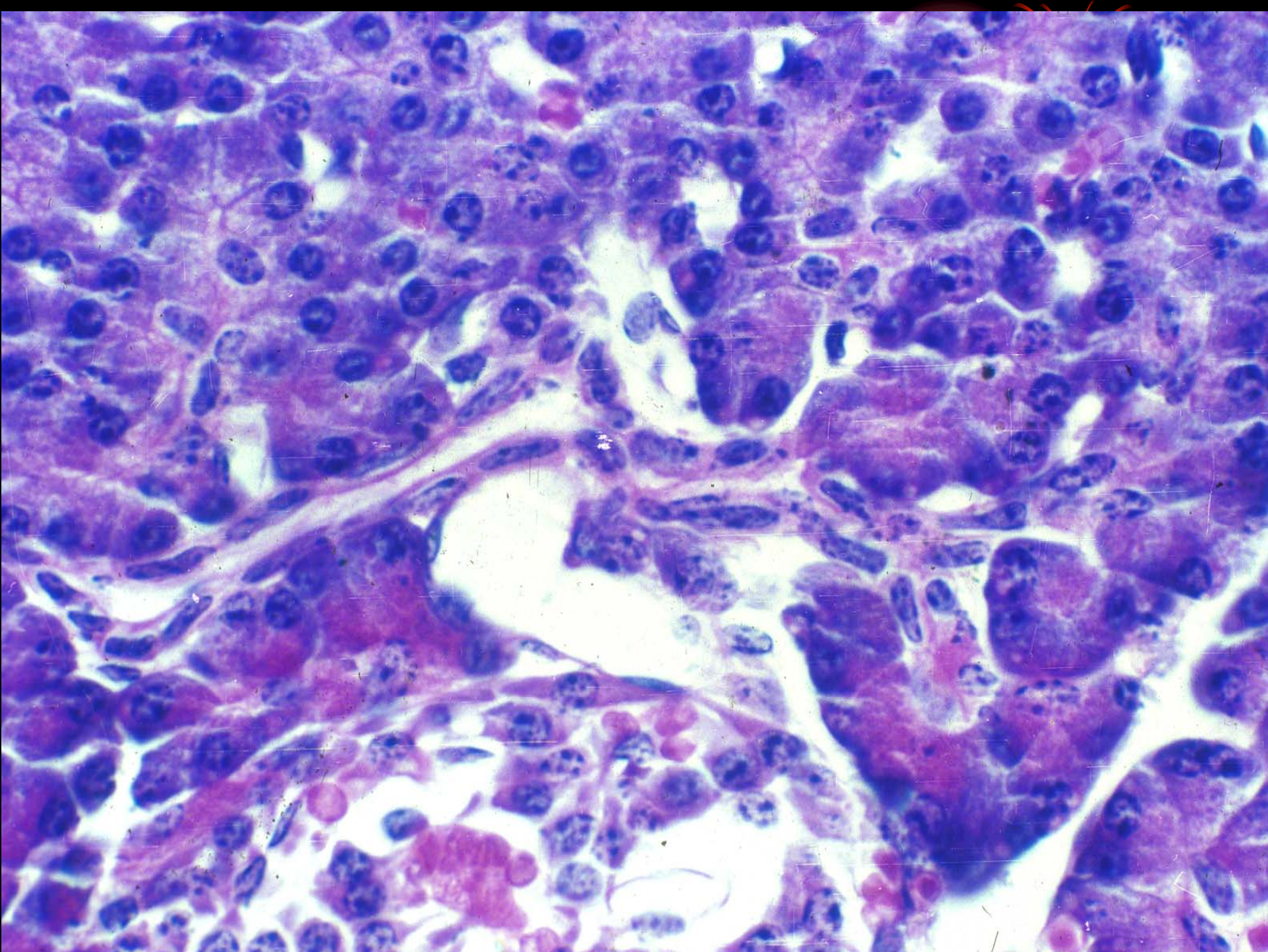
Function: Producing digestive enzymes (trypsin, amylase, lipase, ribonuclease,

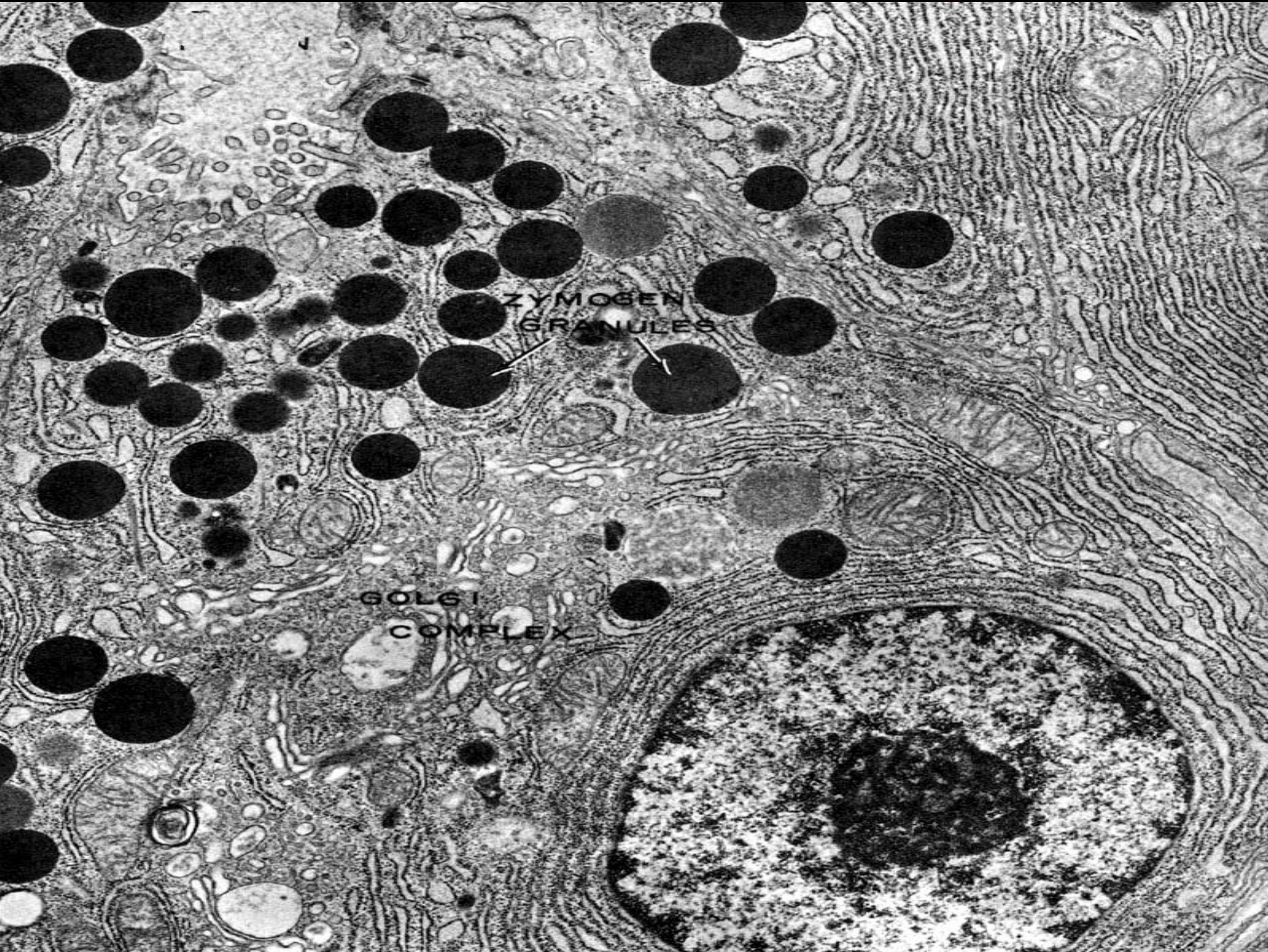


Schematic drawing of the structure of pancreatic acini

- The exocrine pancreatic acinus is composed of several serous cells surrounding a lumen . These cells are highly polarized, with a spherical nucleus, and are typical protein-secreting cells.





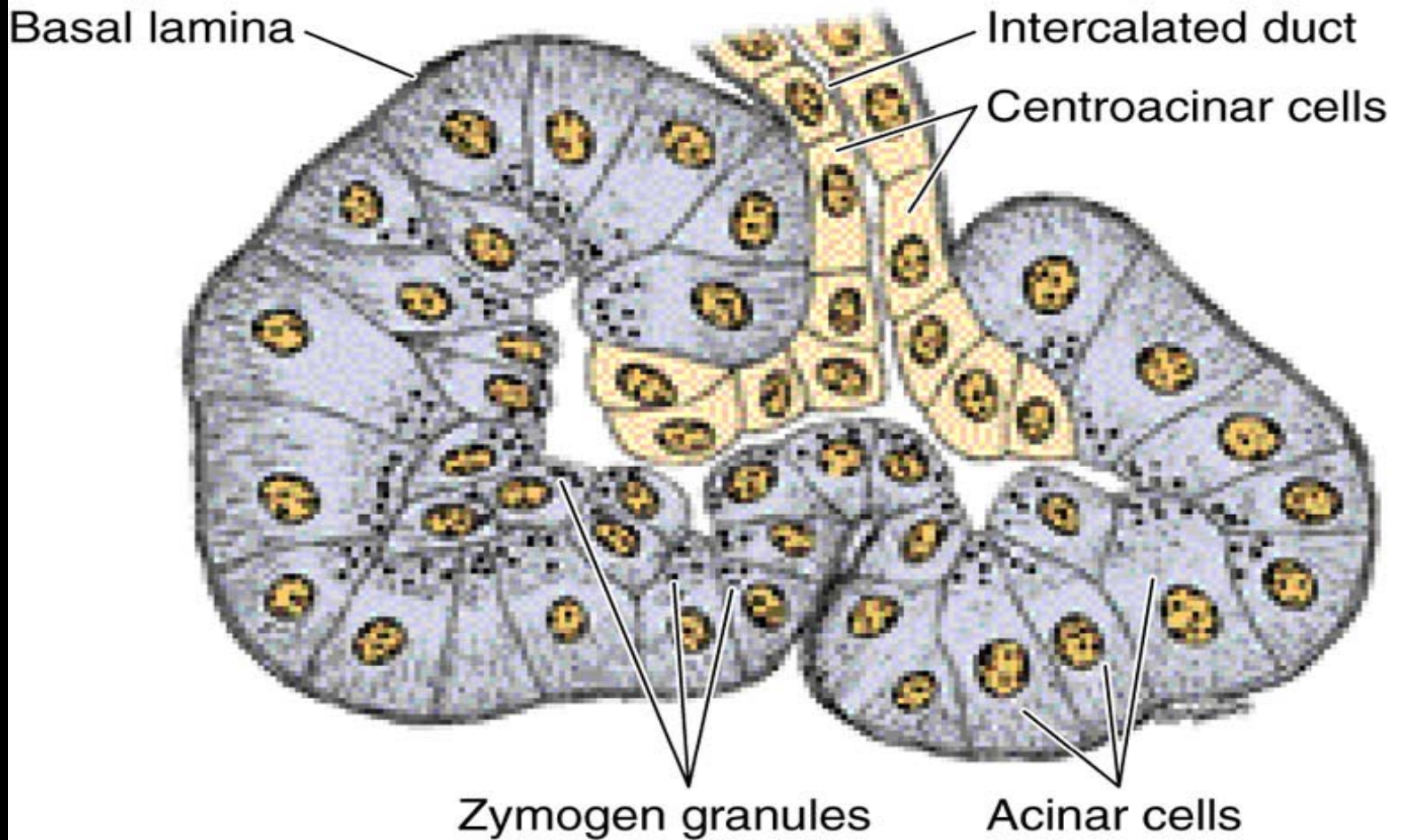
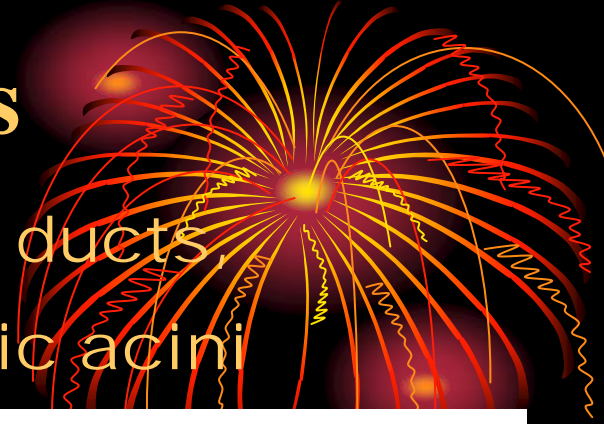

ZYMOGEN
GRANULES

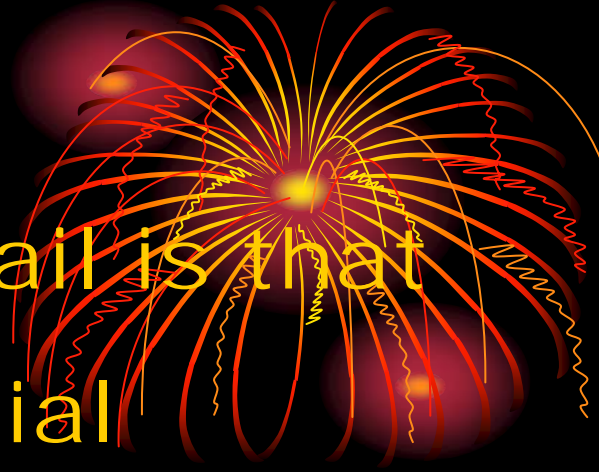GOLGI
COMPLEX

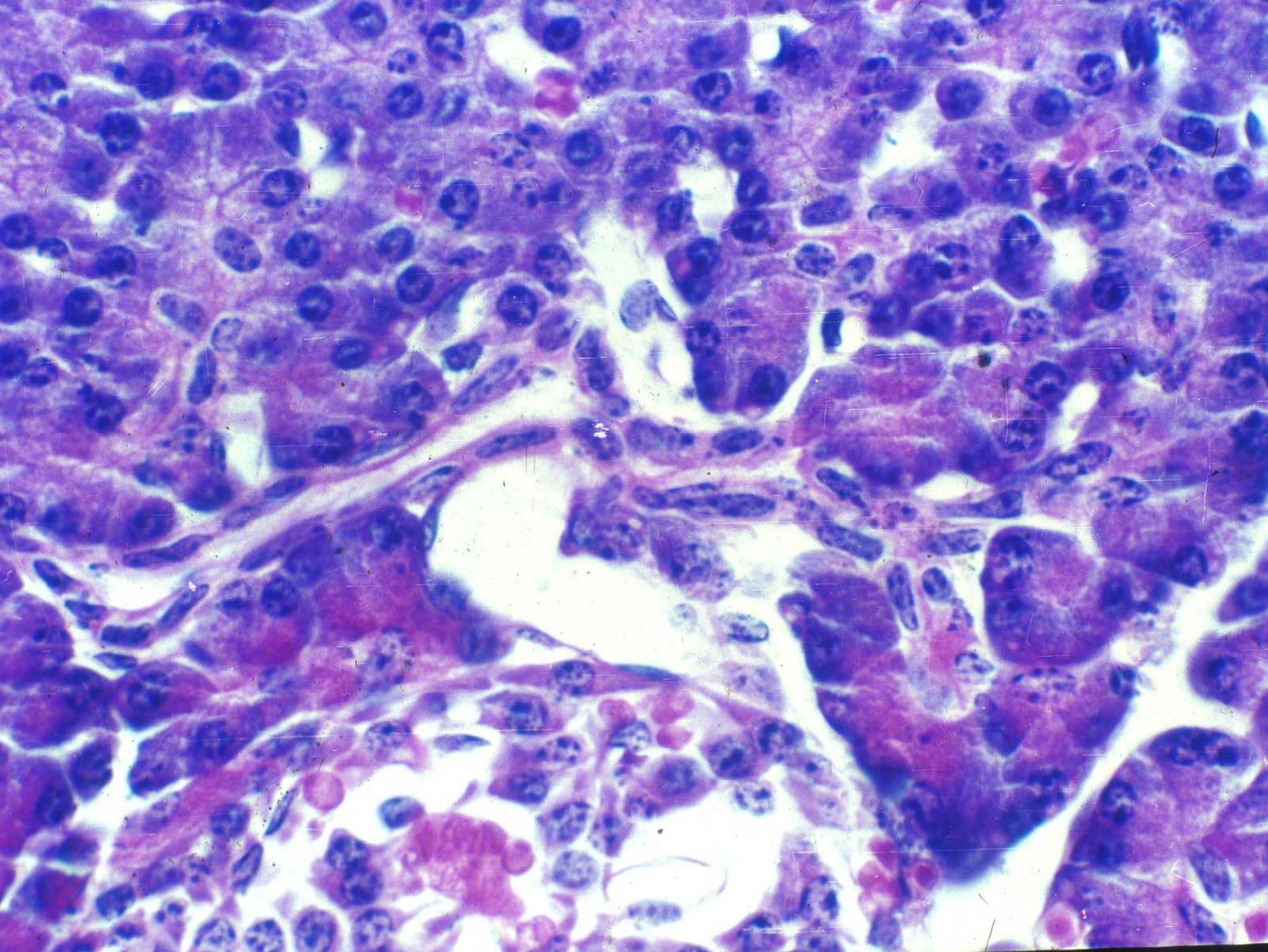
centroacinar cells

The beginnings of intercalated ducts,
the characteristics of pancreatic acini



- The characteristic detail is that in the pancreas the initial portions of intercalated ducts penetrate the lumens of the acini. The cells surrounded by a pale cytoplasm. These cells are found **only** in pancreatic acini.





3.1.2 ducts

intercalated ducts (a simple squamous or cuboidal epithelium)



intralobular ducts (a simple cuboidal epithelium)



interlobular ducts (a simple columnar epithelium)




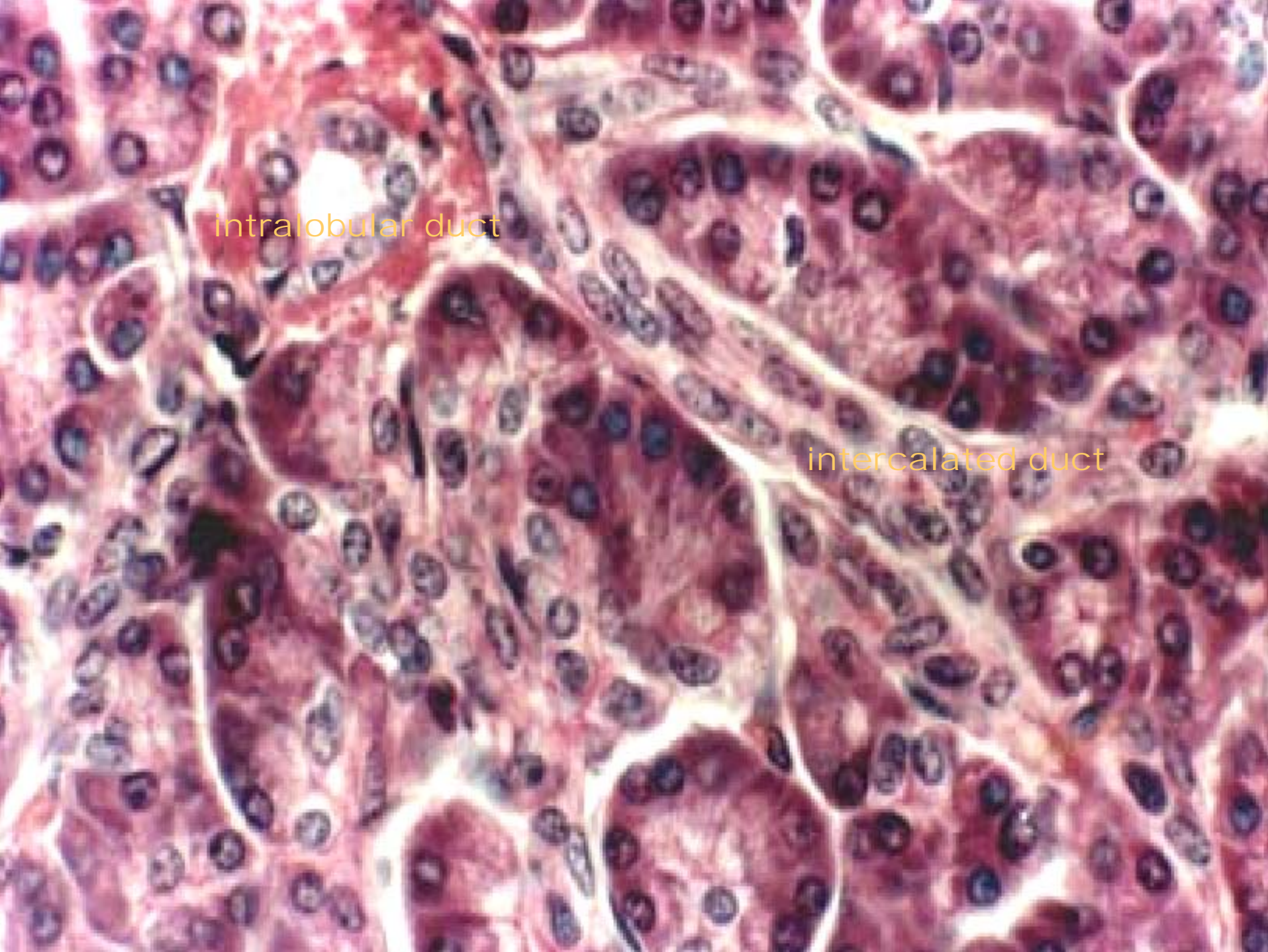
The pancreatic duct (a simple high columnar epithelium and goblet cells)



The pancreatic duct opens into a recess of the duodenal lumen

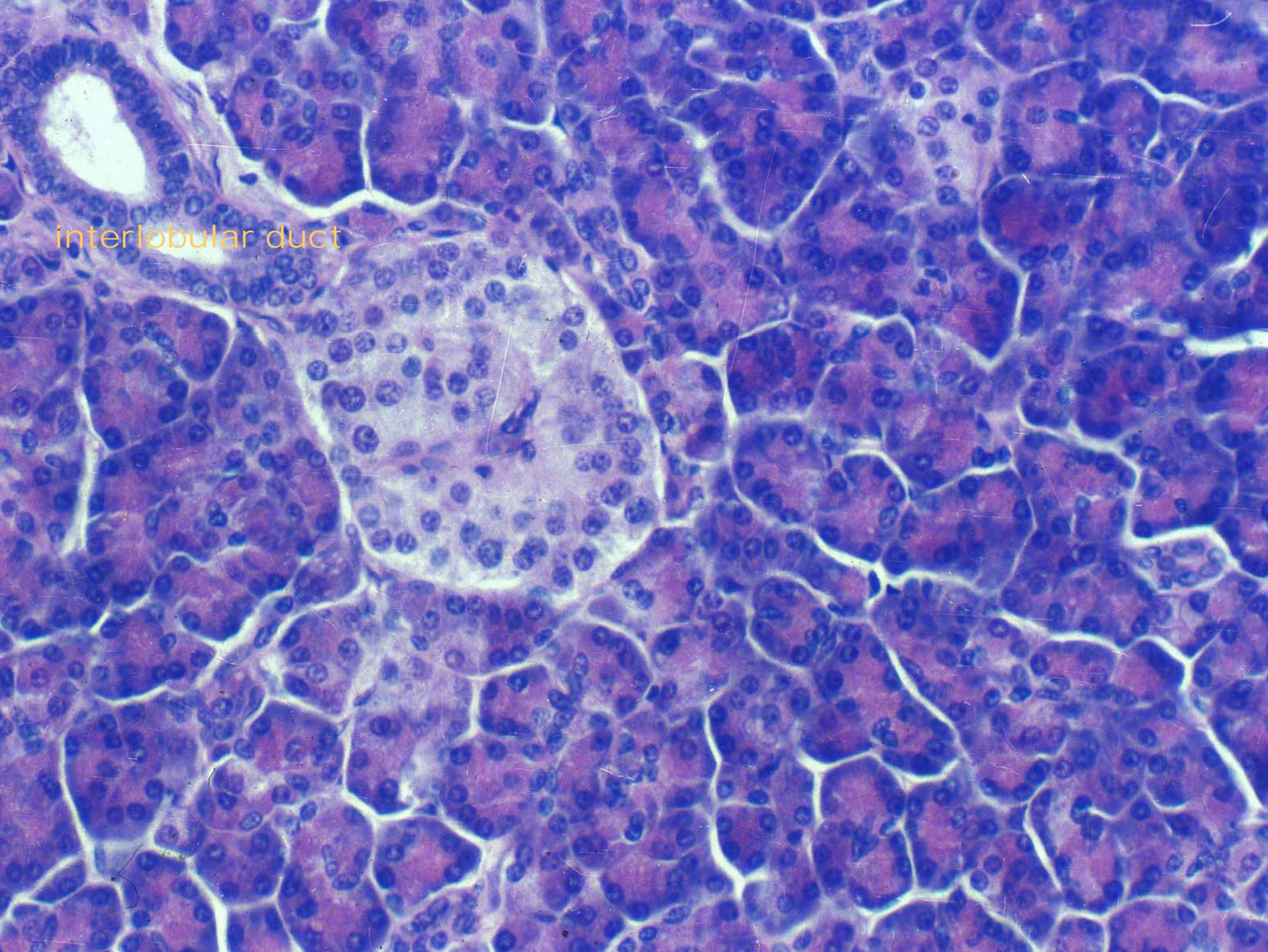
Function: excrete water and electrolytes





intralobular duct

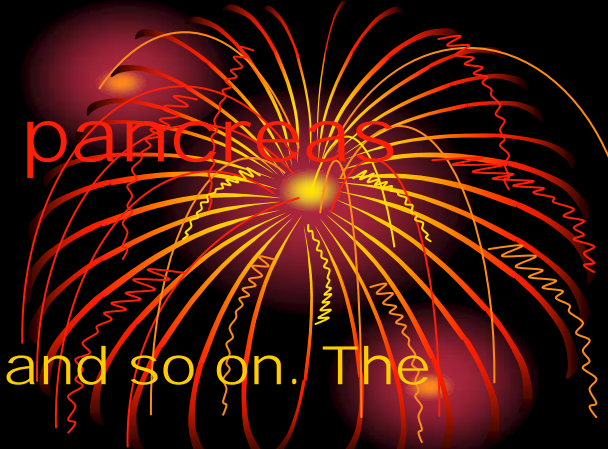intercalated duct



interlobular duct

Function of the exocrine pancreas

- water and electrolytes
- several proteases ,amylase, lipases and so on. The majority of the enzymes are stored as proenzymes in the secretory granules of acinar cells, being activated in the lumen of the small intestine after secretion. This is very important for the protection of the pancreas.
- *Medical Application*
- In acute pancreatitis, the proenzymes may be activated and digest the whole pancreas, leading to very serious complications.



3.2 endocrine portion of the pancreas

pancreatic islets

appear as rounded clusters of cells

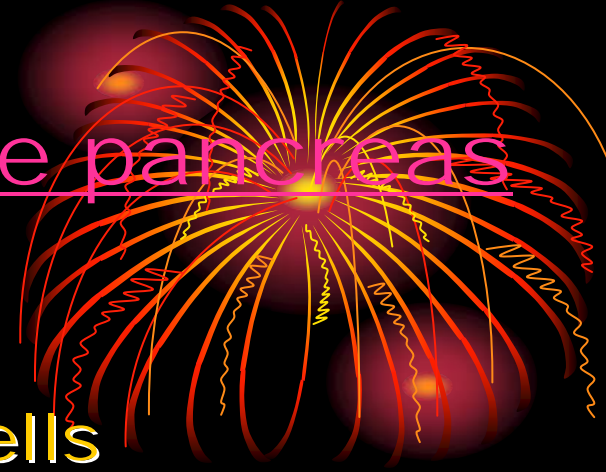
scattered among the exocrine acini

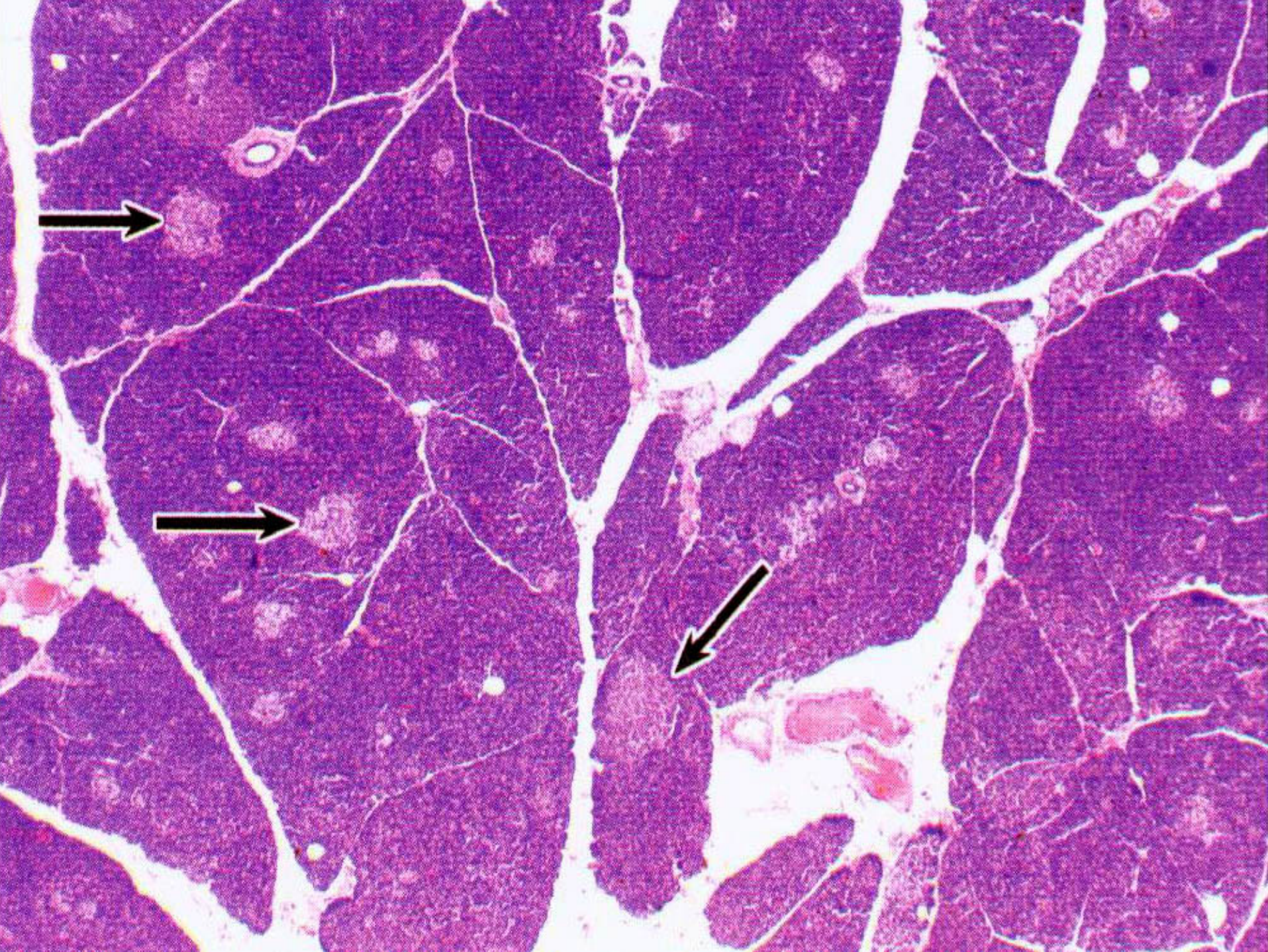
vary in size according to the number of cells

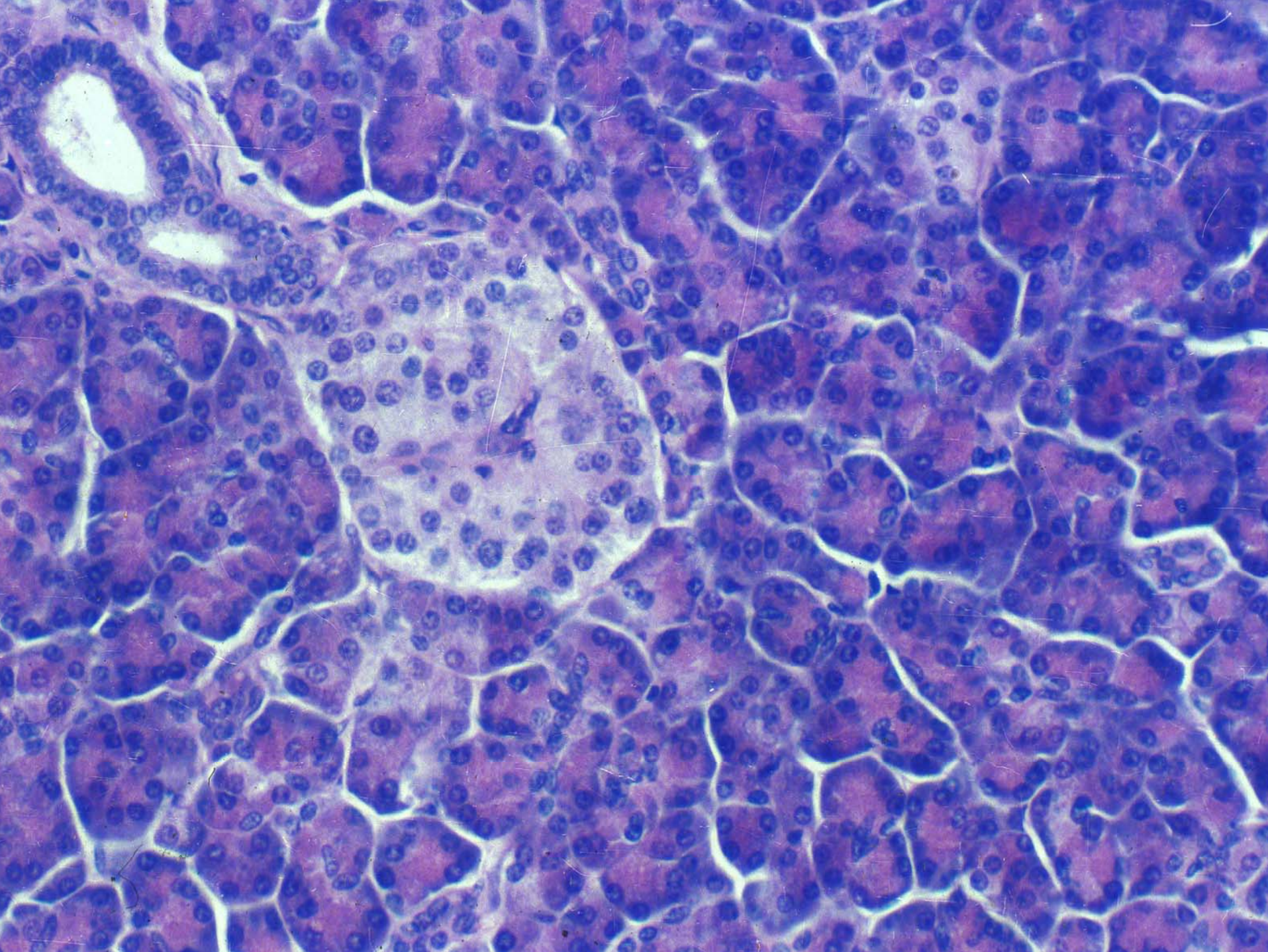
abundant fenestrated capillaries

three different cell-types by Mallory staining

Function: secrete multihormones







3.2.1 A-cells

Constitute 20% of the islet cell population

Large in size

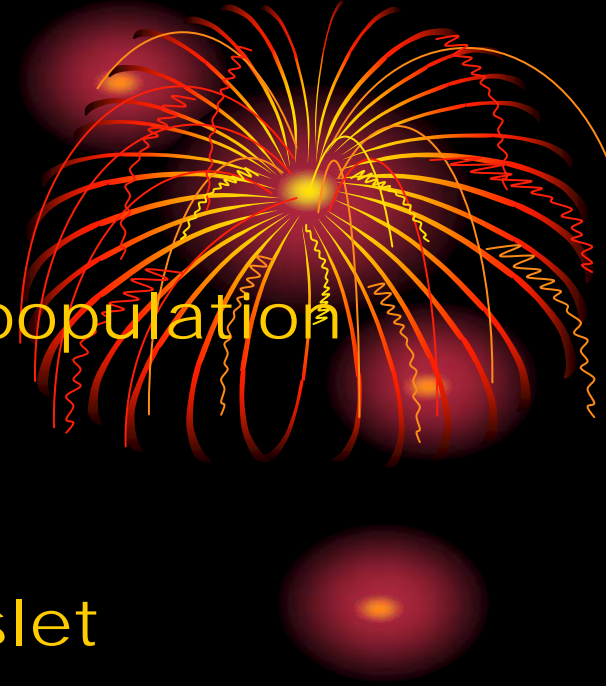
located at the periphery of an Islet

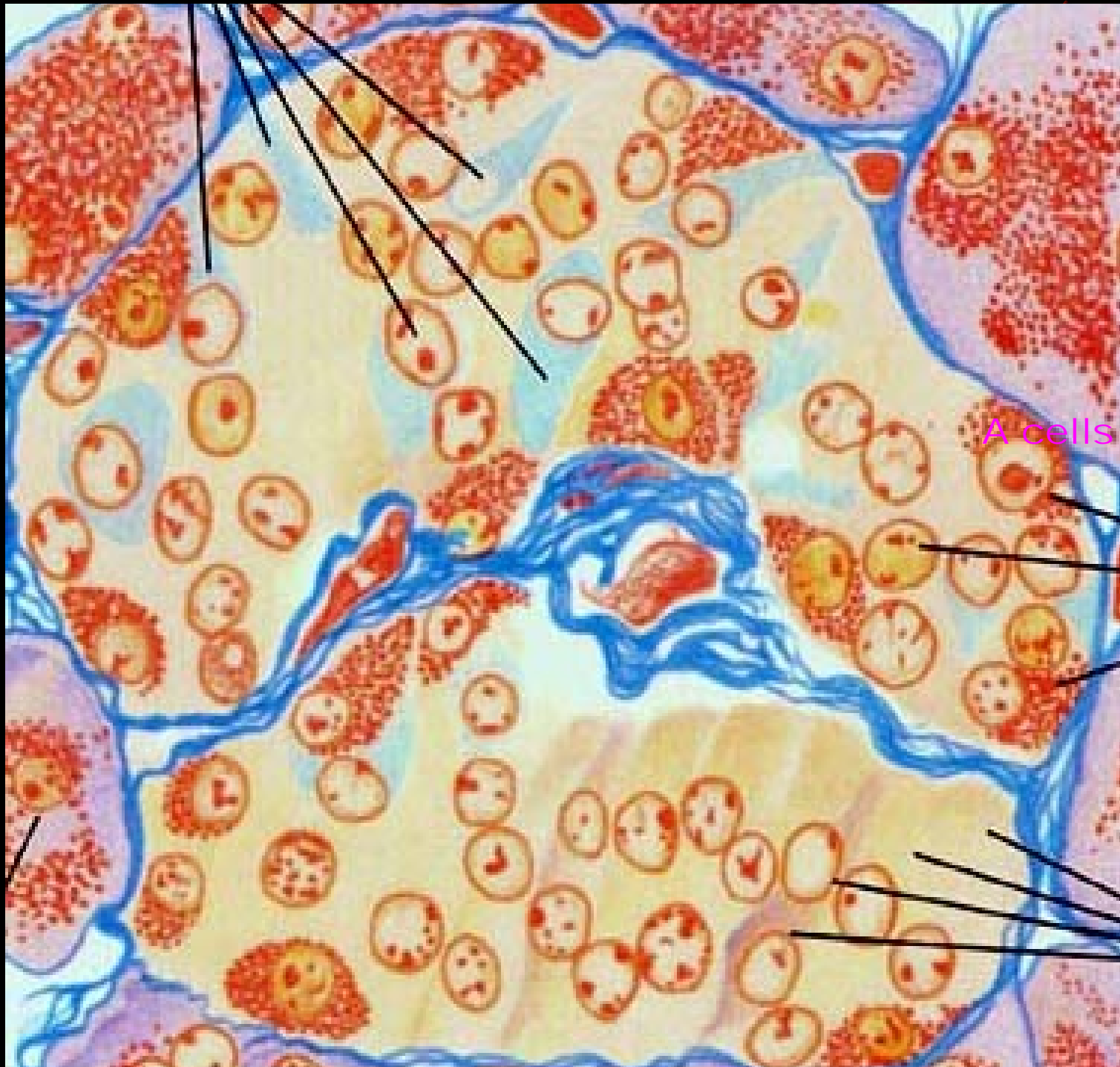
Function : secrete glucagon, which

increases the rate of conversion


of liver glycogen to glucose,


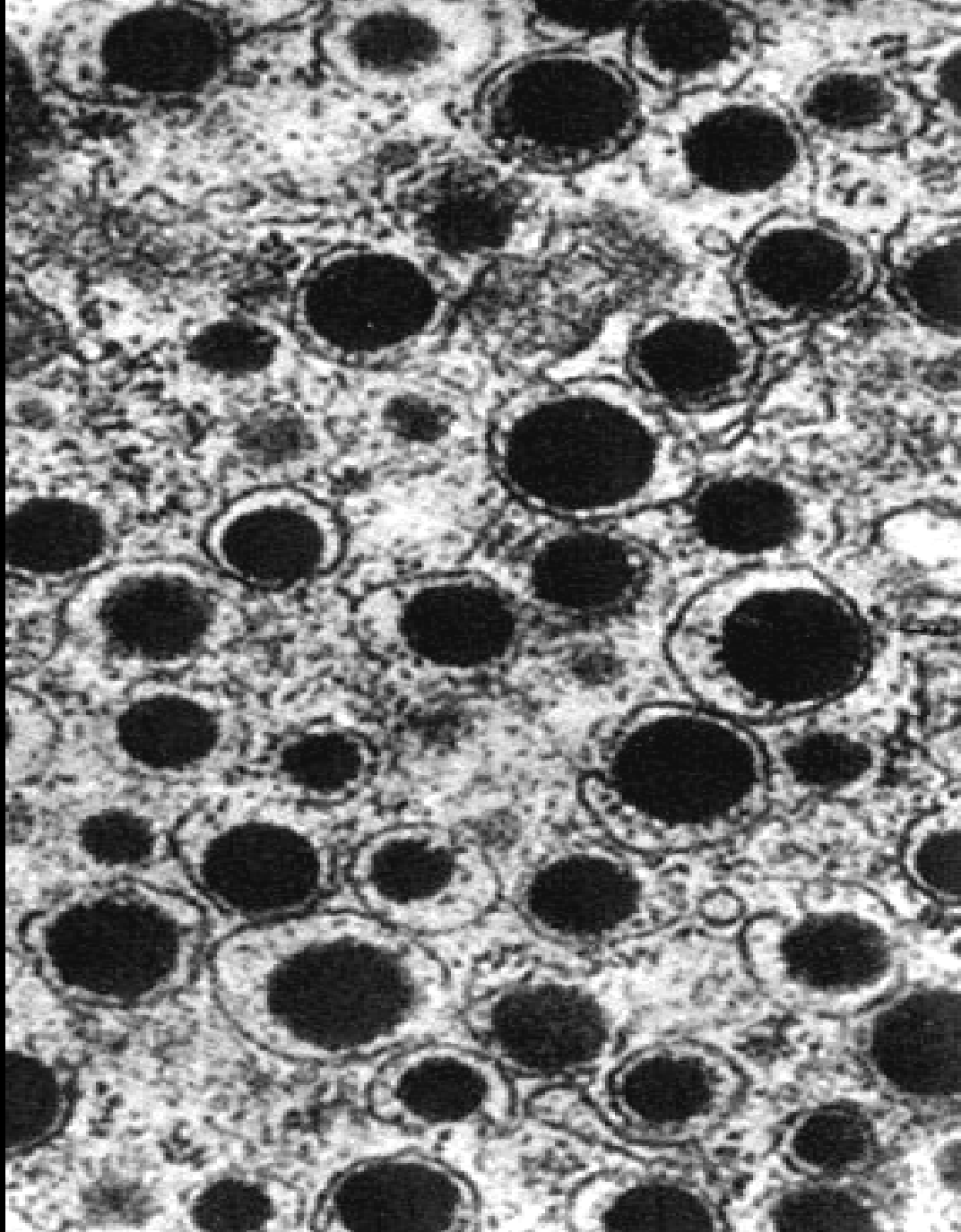
raises blood sugar levels





A cells



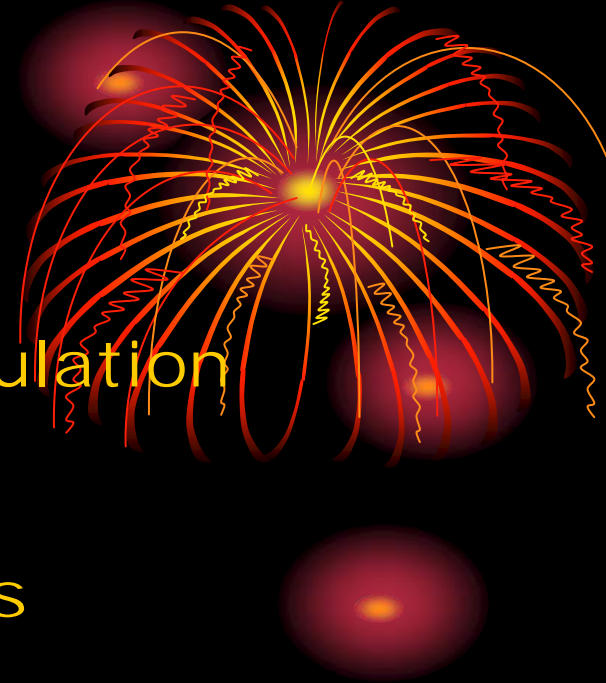A decorative graphic of fireworks exploding in the upper right corner. The fireworks are rendered in bright red and orange colors against a black background. The explosion is centered, with many thin, radiating lines representing the firework's path. There are also some glowing red and orange spheres scattered around the main explosion.

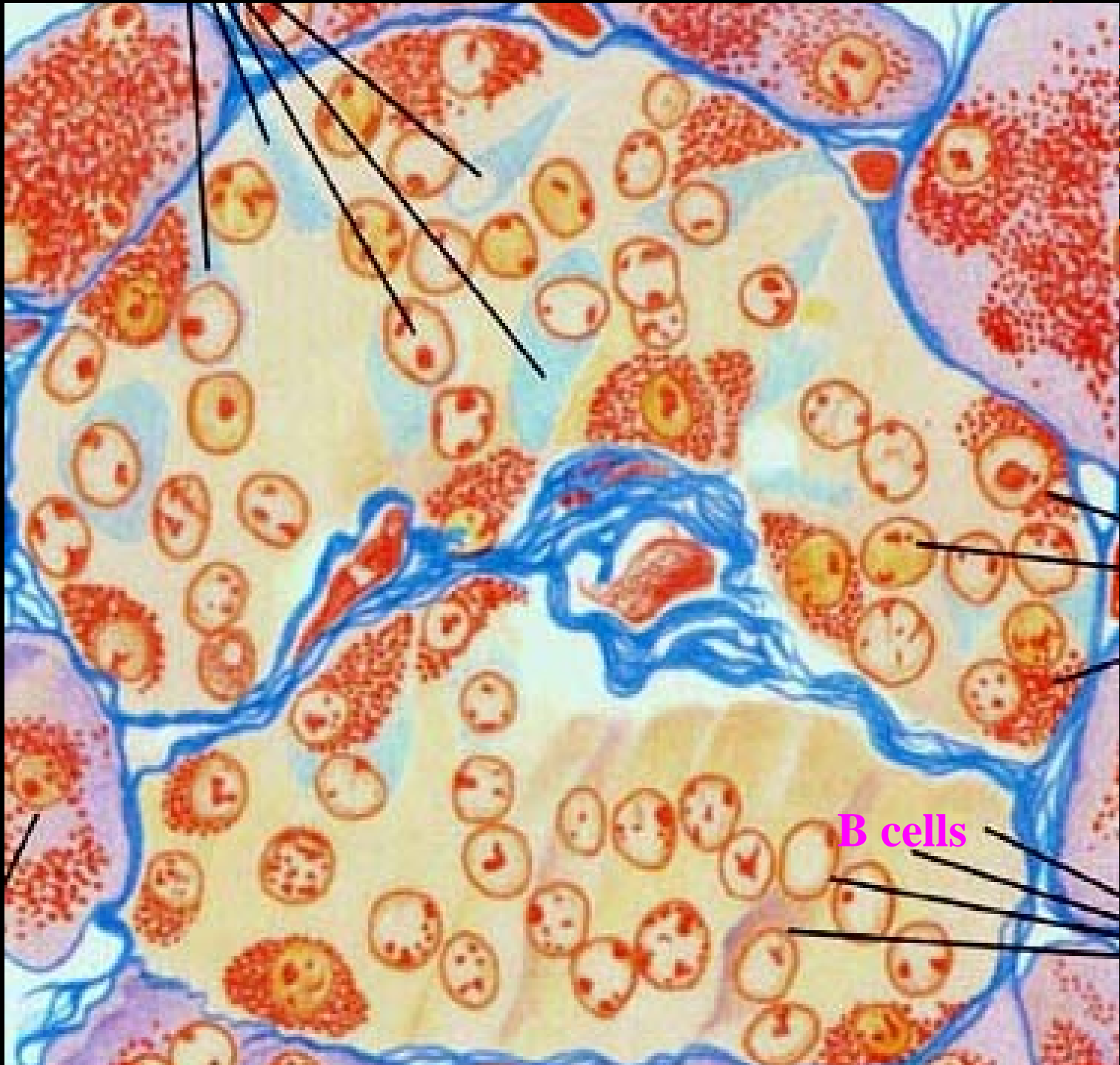These granules are shown to be membrane-bound, with a highly electron-dense core

3.2.2 B-cells


Constitute 70% of the islet cell population
located at the centre of an Islet


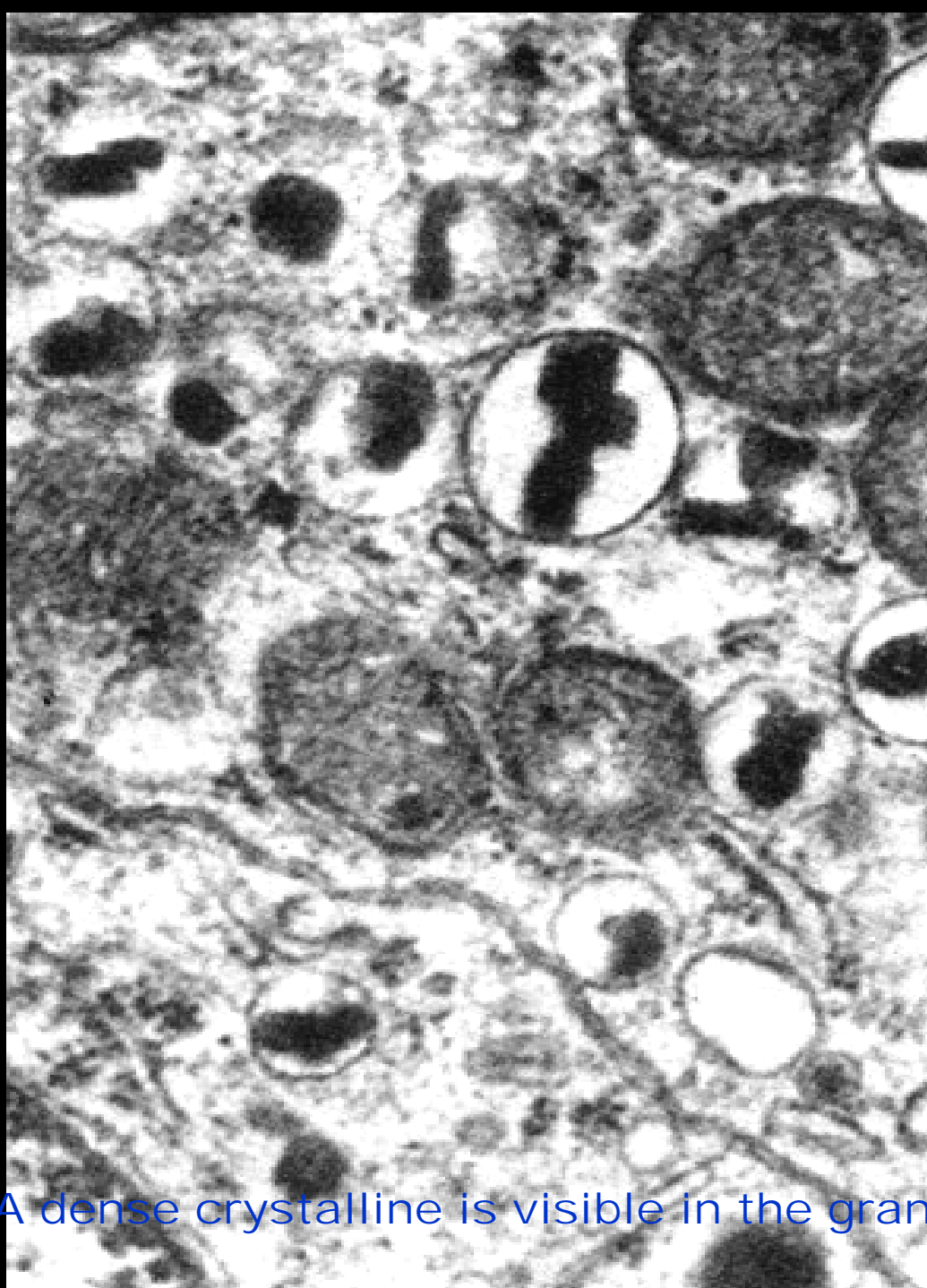
Function: secrete insulin which acts
antagonistically to glucagon and
facilitates the utilization of glucose by
increasing glucose oxidation and
glycogenesis, thus lowering blood
sugar levels





B cells



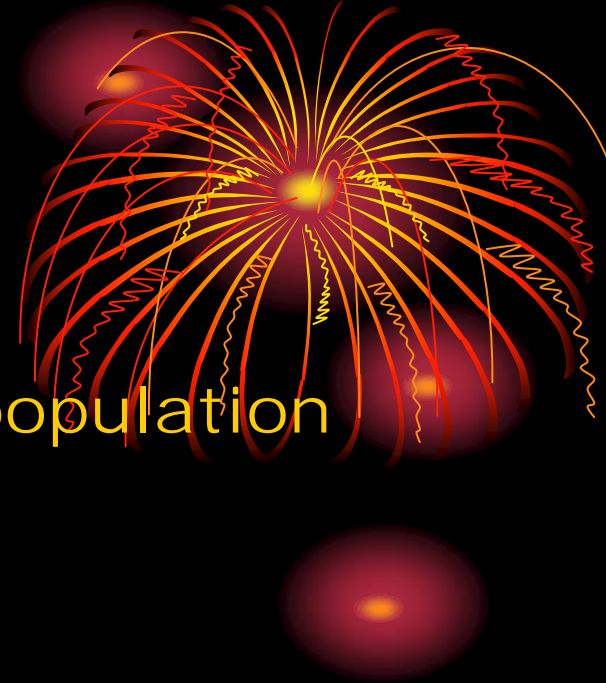


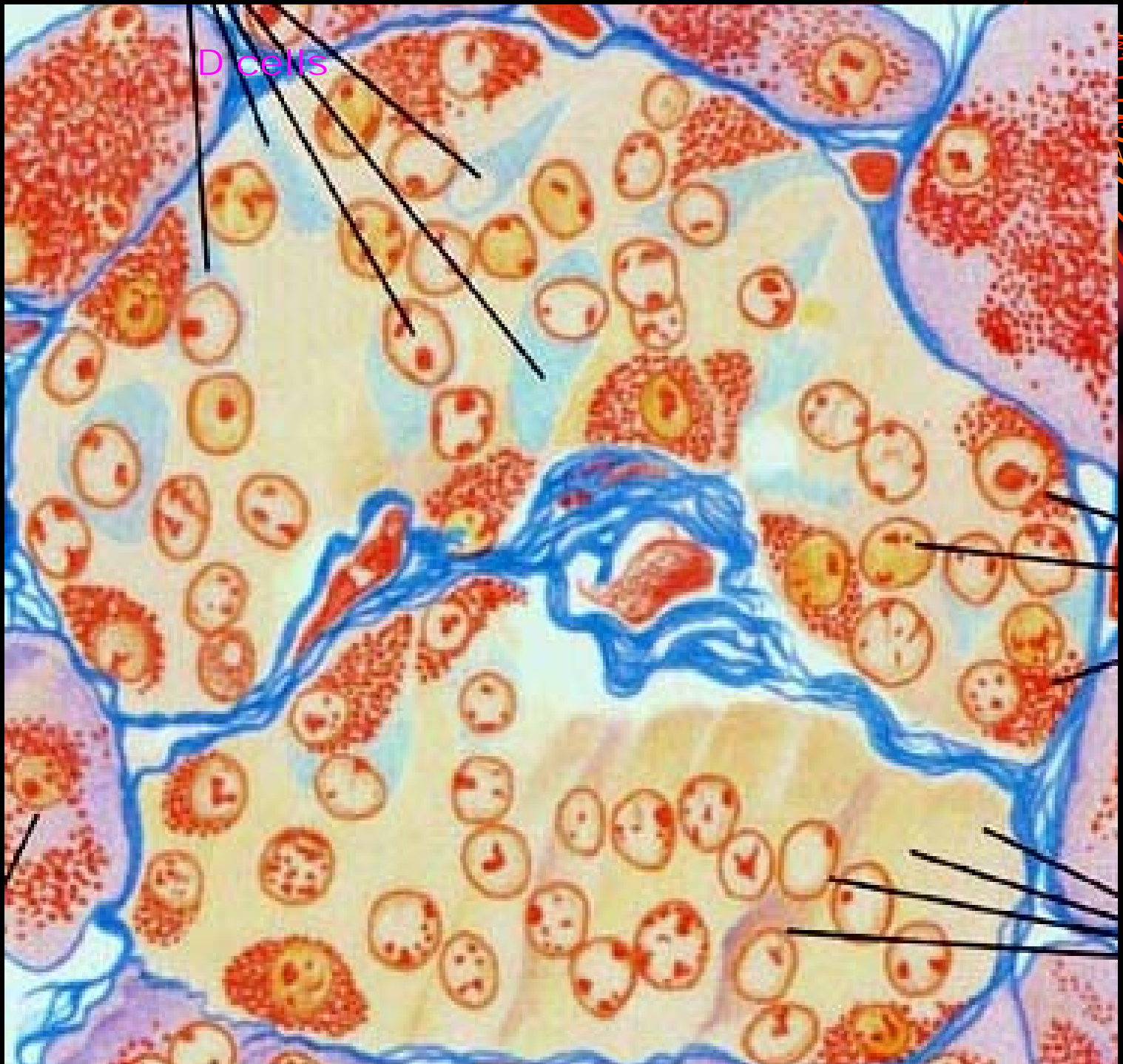
A dense crystalline is visible in the granules

3.2.3 D-cells


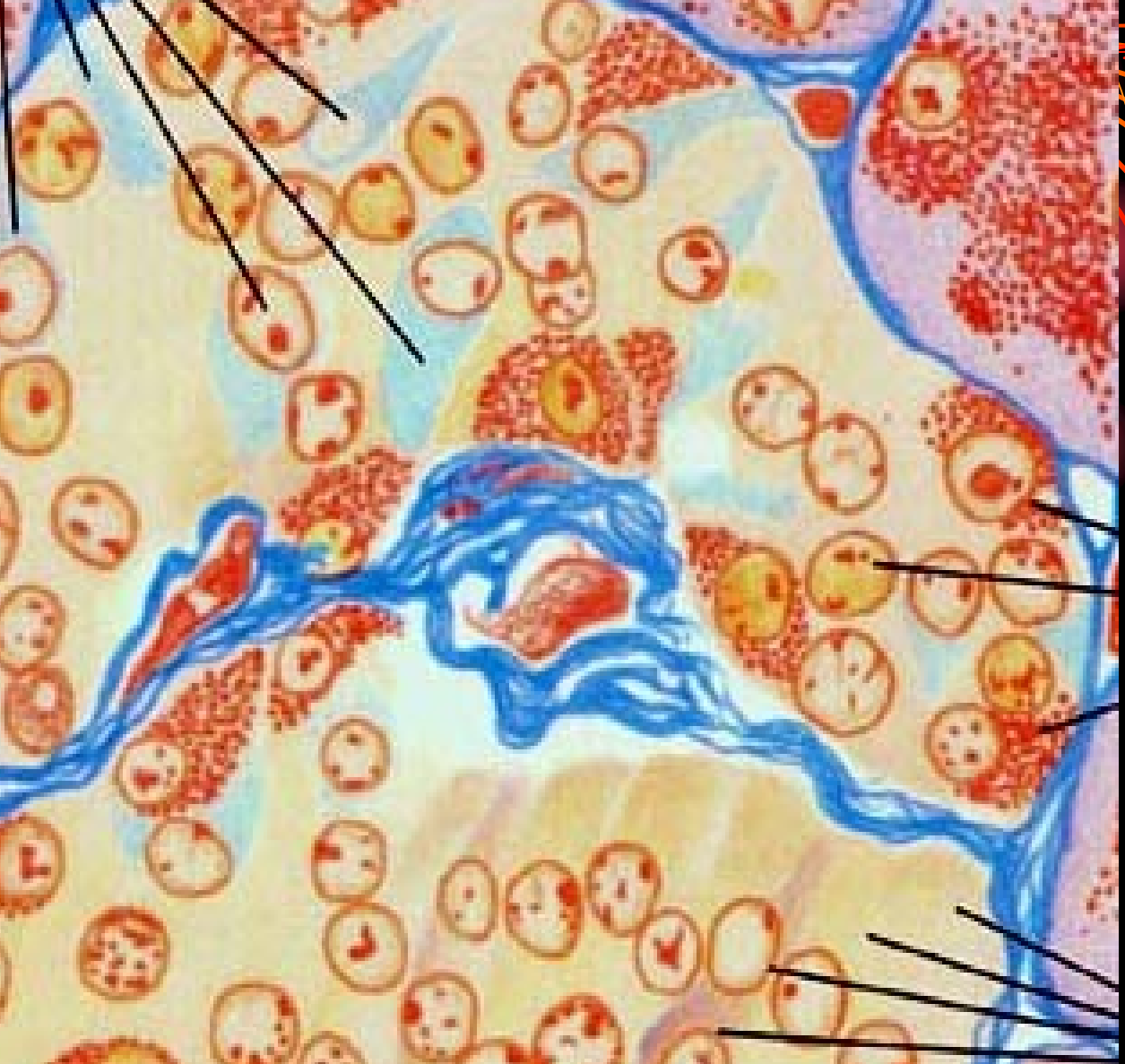
Constitute 5% of the islet cell population
scattered in an Islet

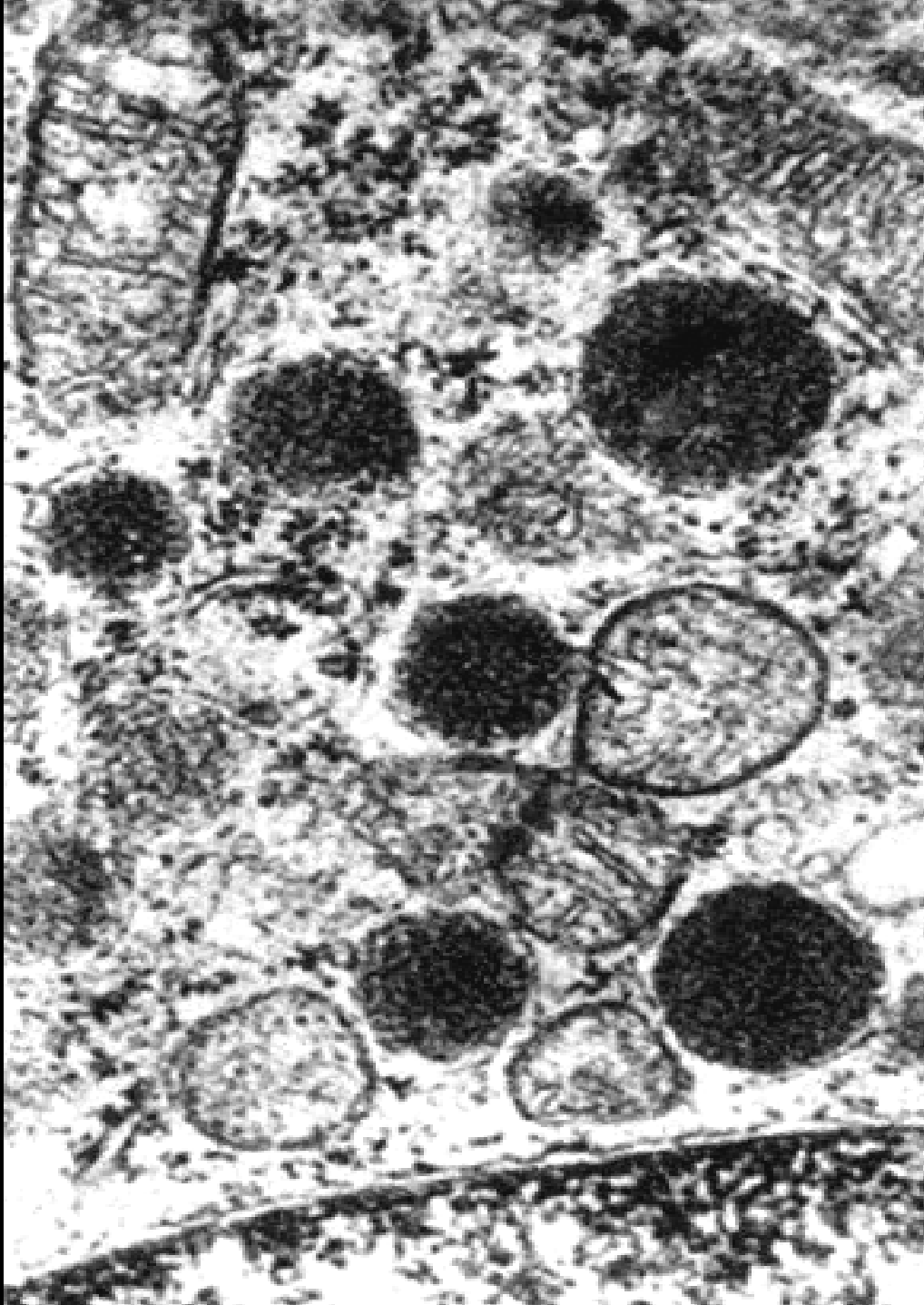
Function: secrete somatostatin which
inhibits the release of glucagon
and insulin






D cells





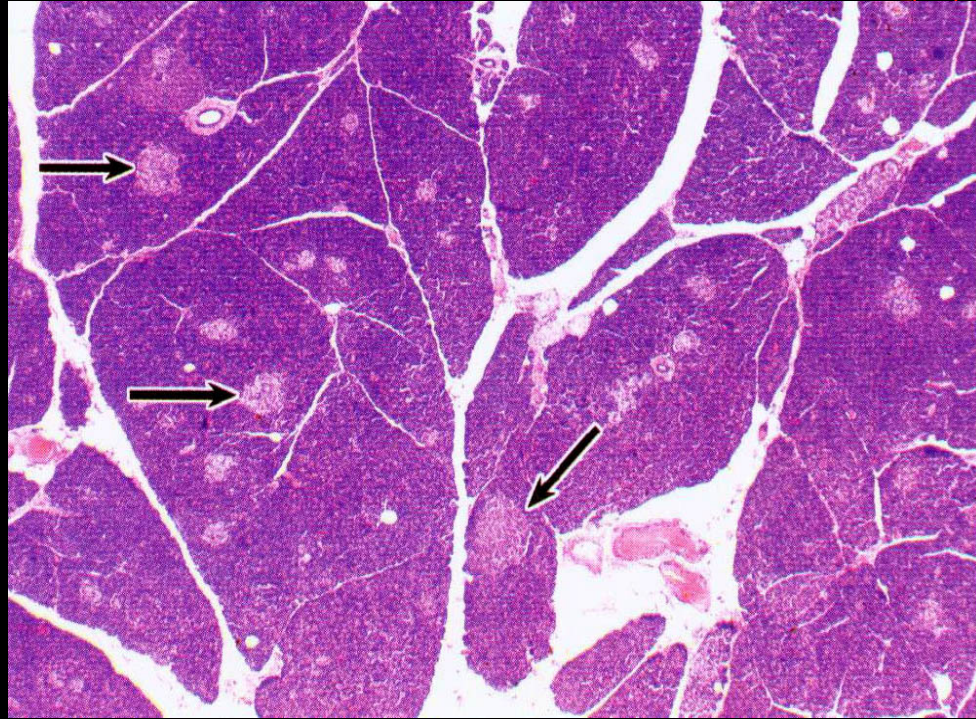
These granules appear less electron-dense than those of the A-cells



In addition to the above cell-types, the pancreatic islets also contain PP-cells and D1 cells.

PP-cells which secrete pancreatic polypeptide, to promote the secretion of gastric acid and pepsinogen.

D1 cells which secrete vasoactive intestinal peptide which to stimulate the secretion of glucagon and insulin. to inhibit the secretion of gastric acid



exocrine portion: water and electrolytes,
several proteases ,amylase, lipases and so on.

endocrine portion

(pancreatic islets): A cells (glycogen), B cells (insulin),
D cells (somatostatin)

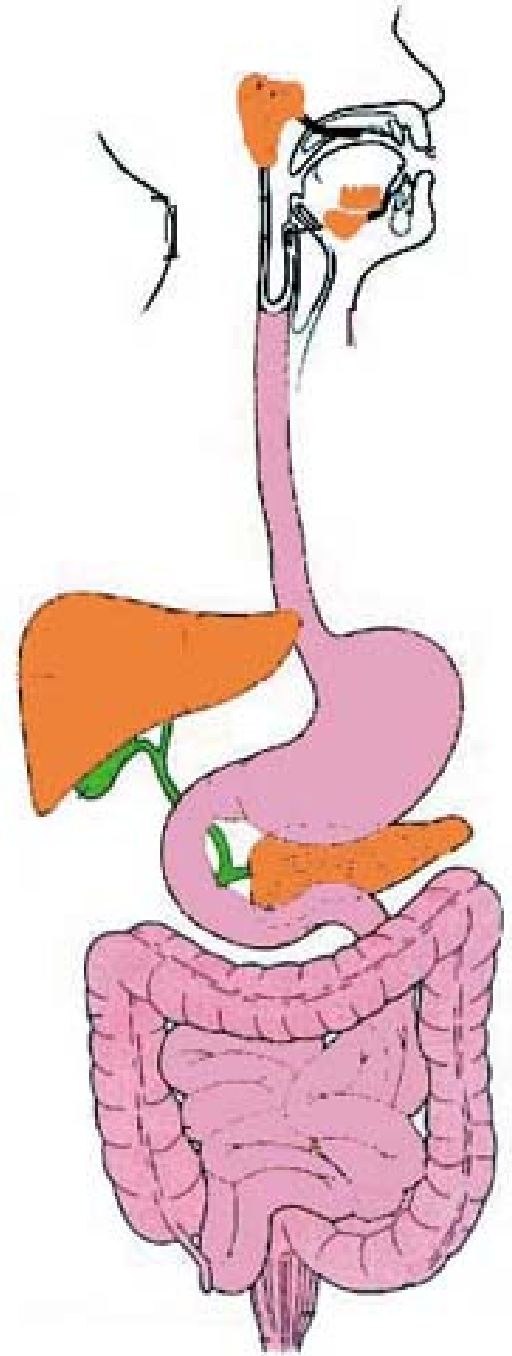
4.liver

The general structure of liver

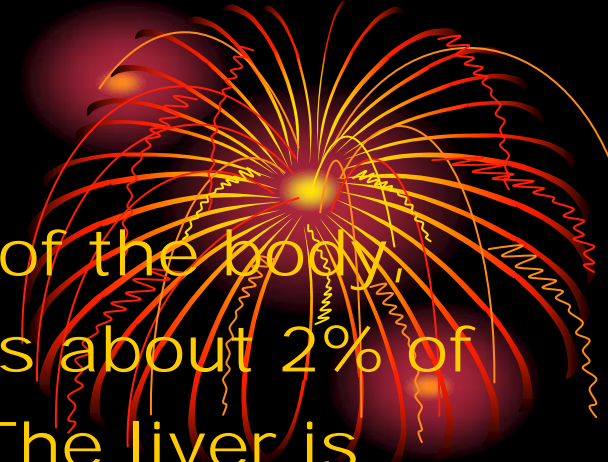Capsule

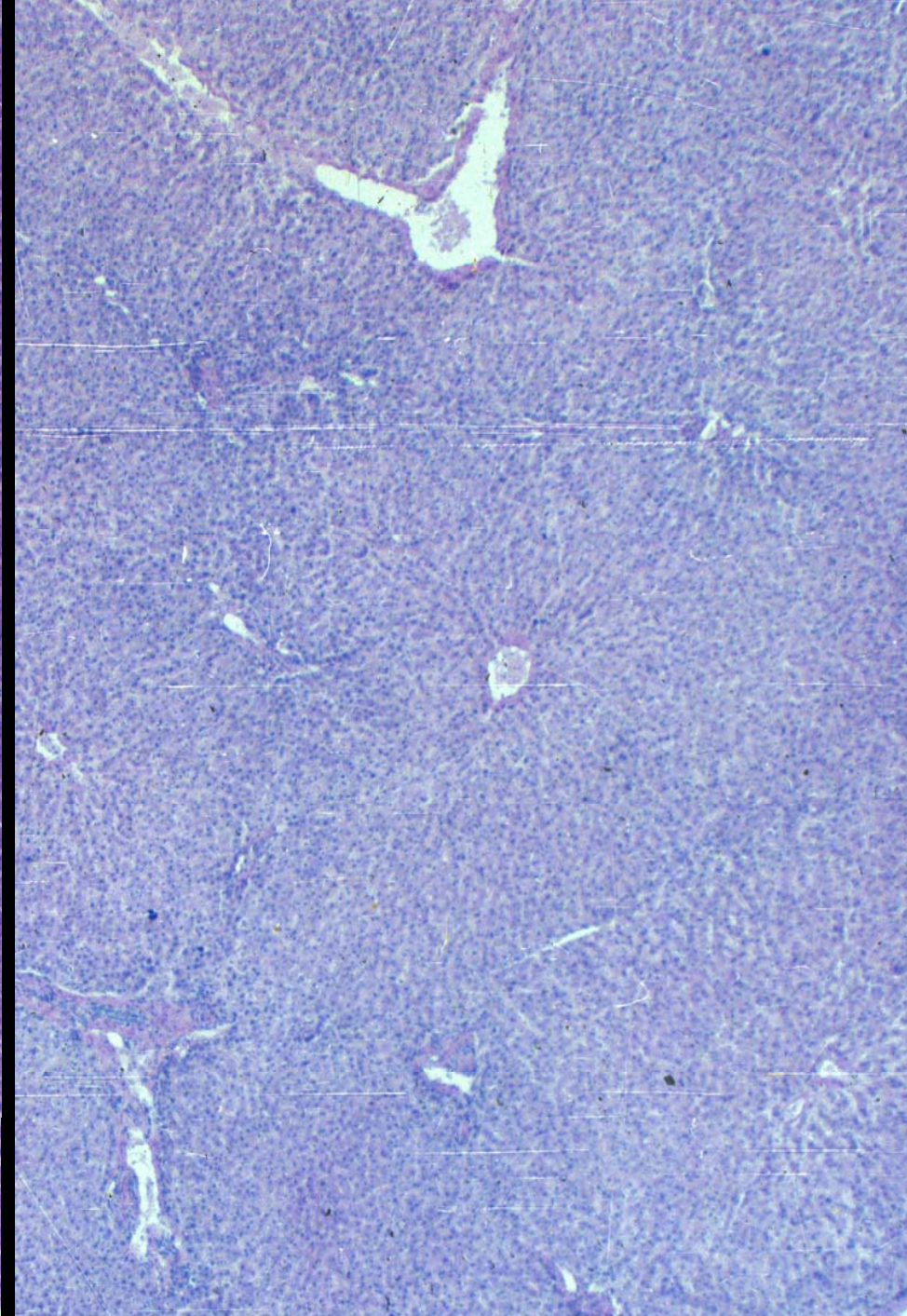
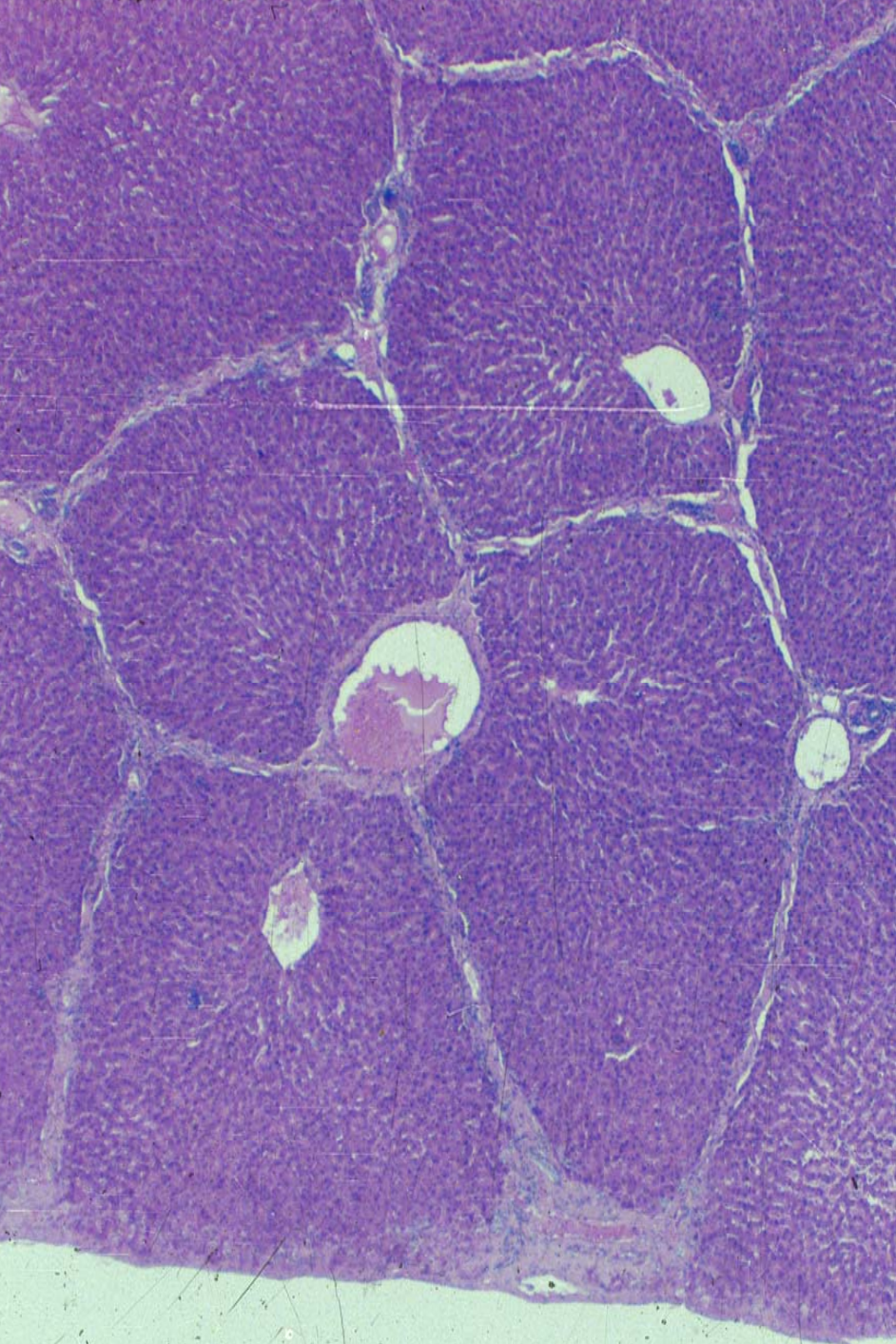
hepatic lobules

portal area: the lobules are demarcated by connective tissue containing bile ducts, lymphatics, nerves, and blood vessels, these regions, named portal area.



- The liver is the largest gland of the body weighing about 1.5kg. which is about 2% of the body weight of an adult, The liver is covered by a capsule of dense connective tissue rich in elastic fibers. Thin connective tissue septa enter the parenchyma of the liver at the hilum, together with the portal vein, hepatic artery, hepatic ducts to divide the liver into lobules

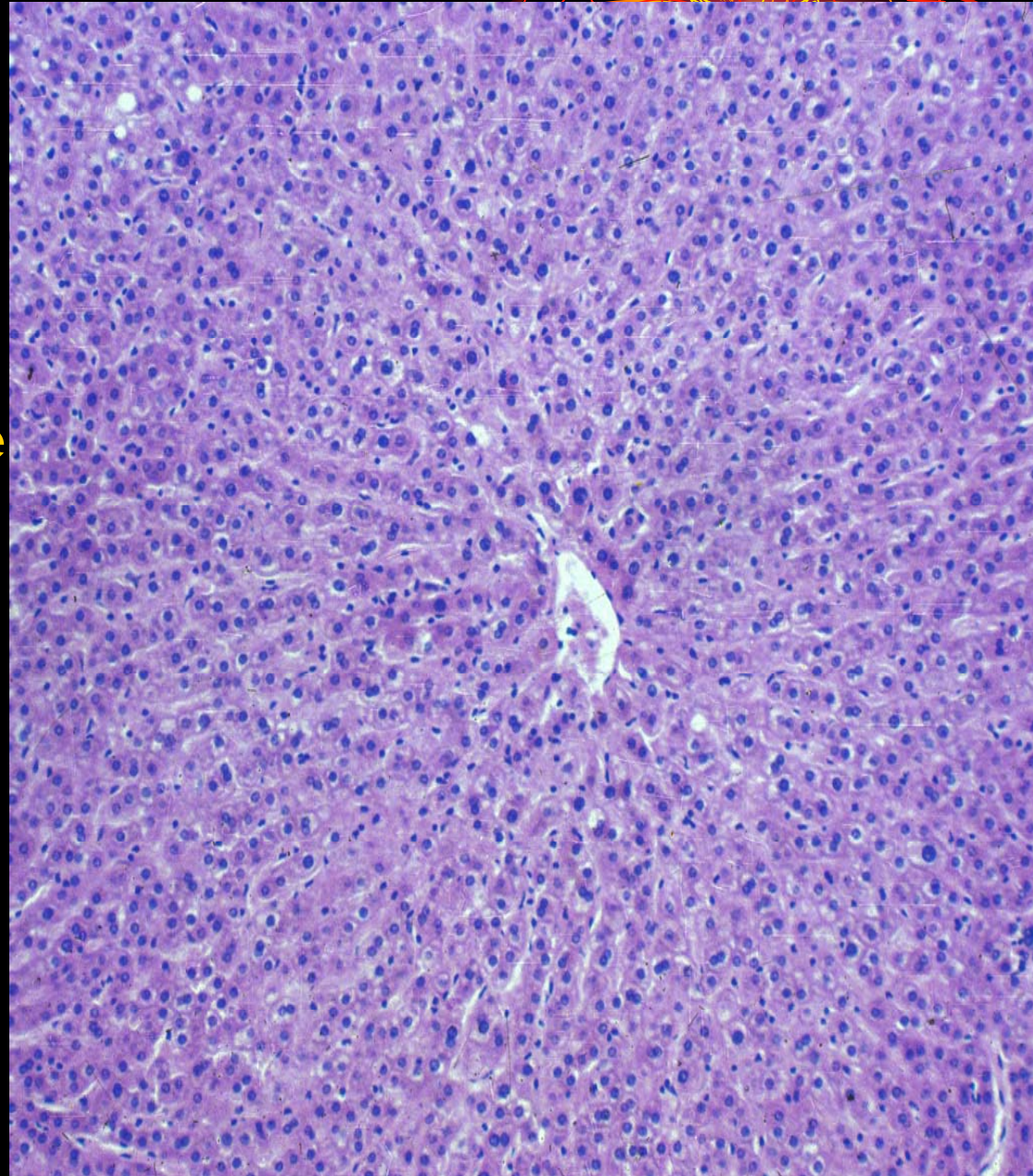




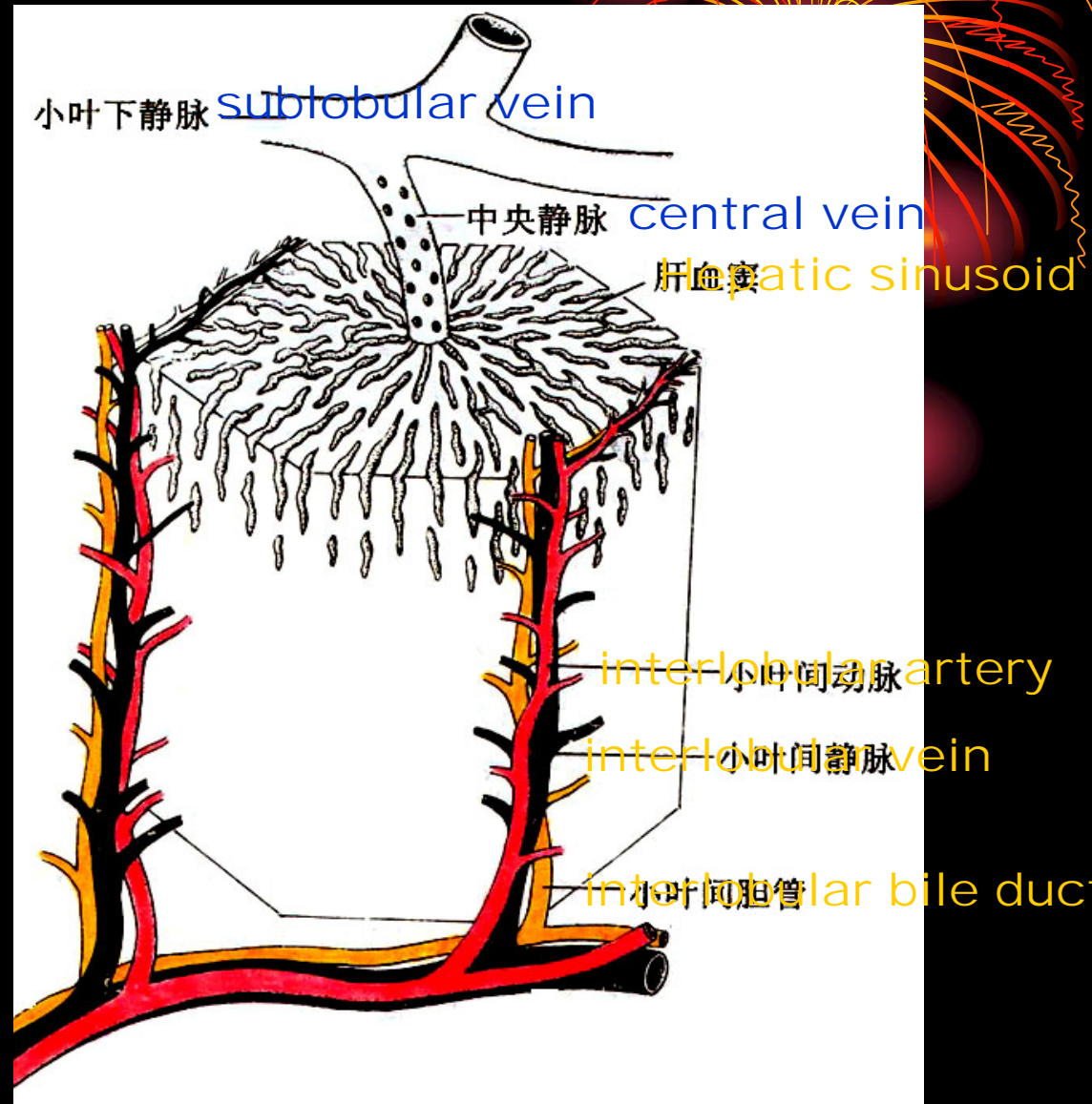
4.1 Hepatic Lobules

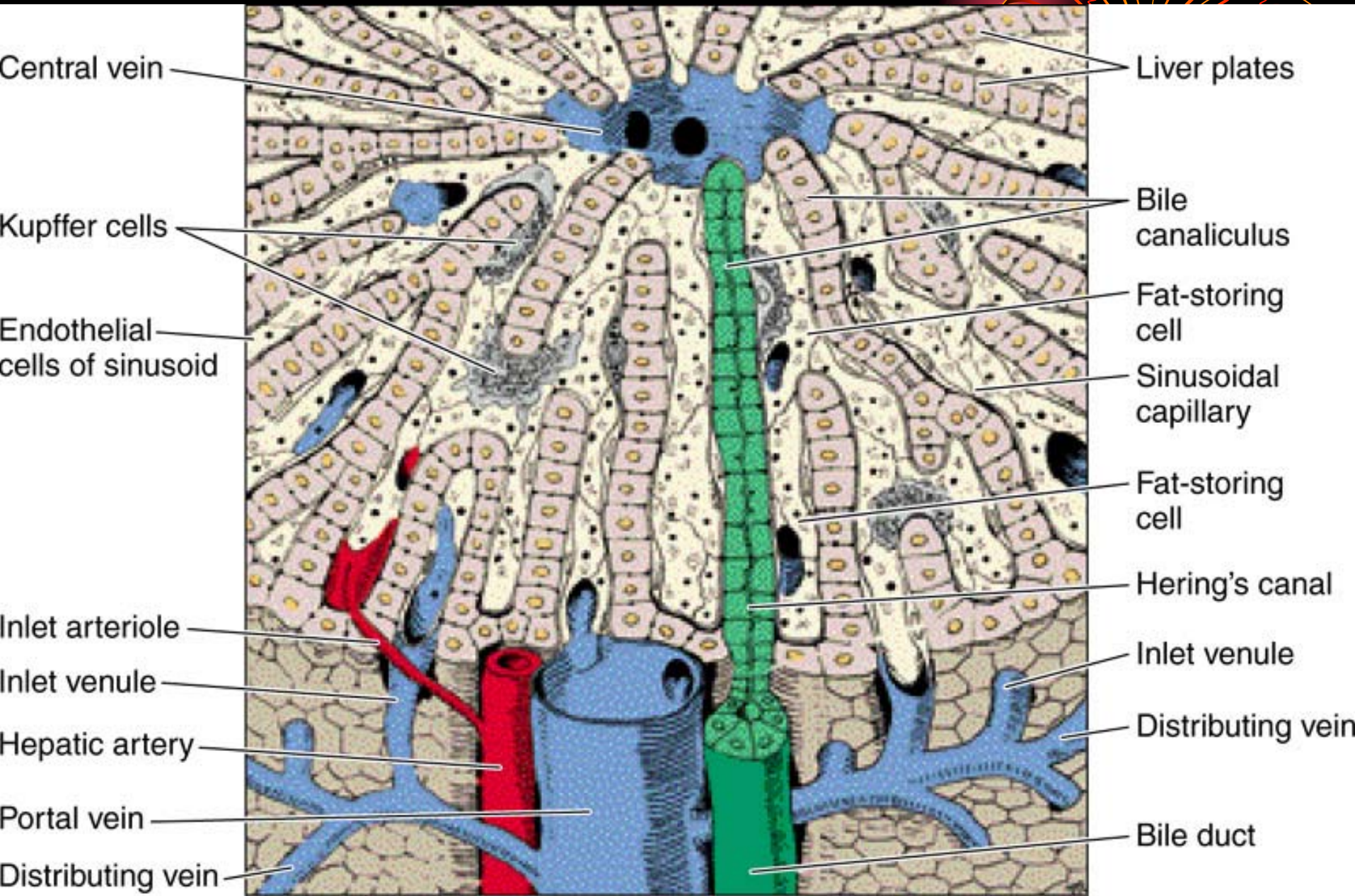


- There is a central vein at the centre of the hepatic lobule
- The hepatocytes are radially disposed and are arranged like the bricks of a wall named hepatic plate
- sinusoid

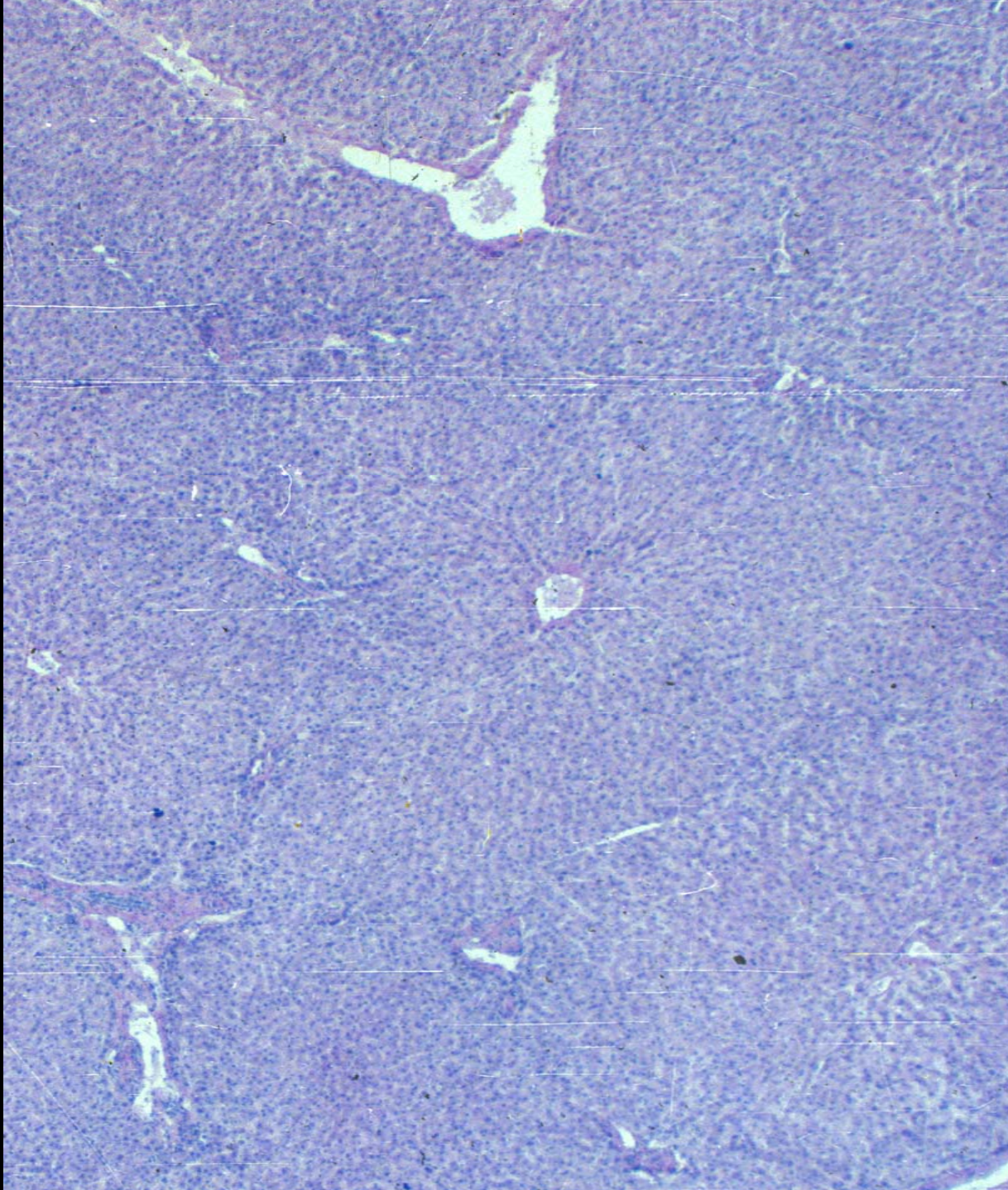


The hepatic lobule is the basic structural unit of the liver. there are about a half to one million in an adult liver. The liver lobule is formed of a polygonal mass of tissue .



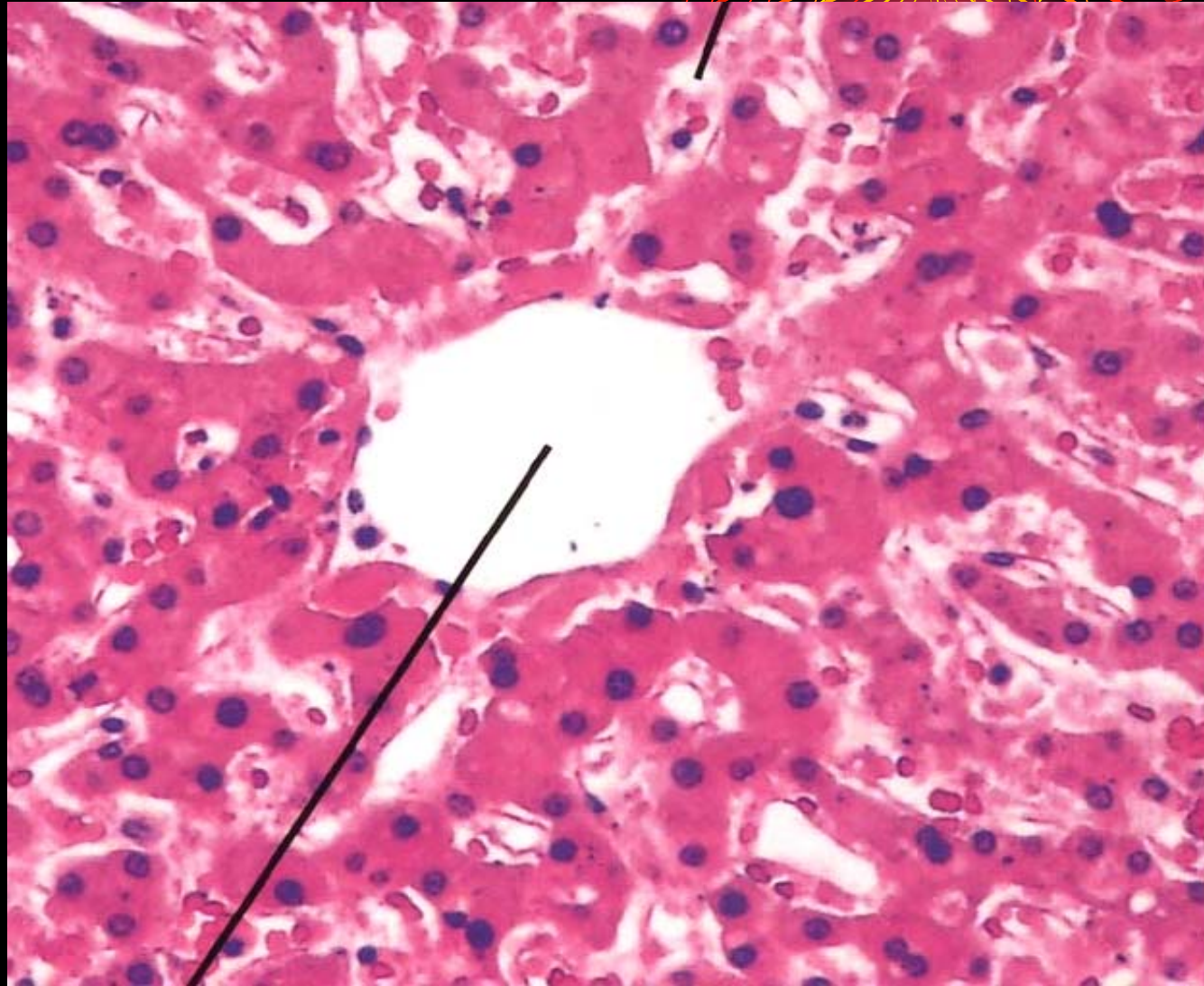


the lobules are in close contact along most of their length, making it difficult to establish the exact limits between different lobules.



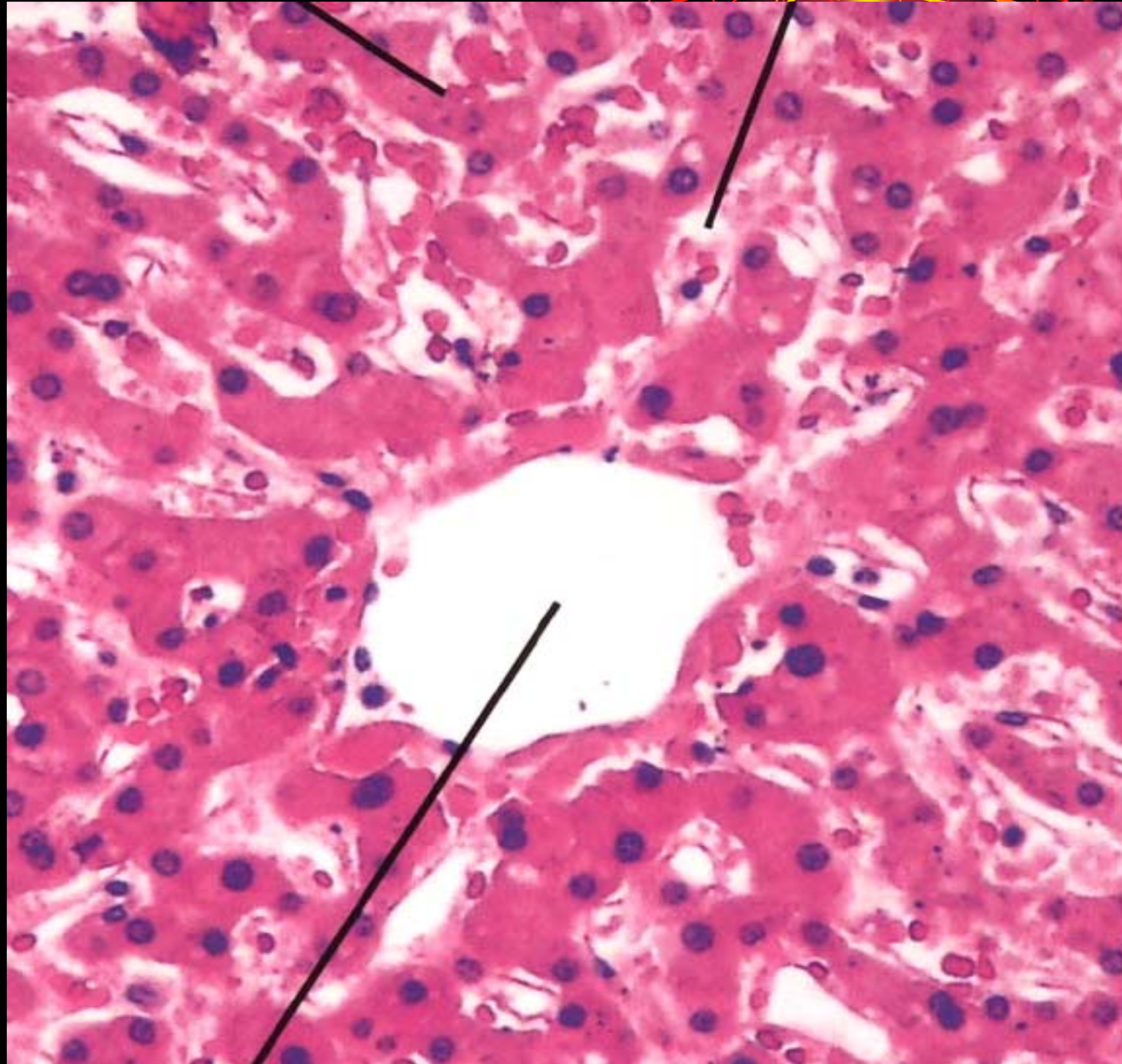
4.1.1 central vein

- this is the smallest tributary of the portal vein
- Is very thin-walled consisting of only endothelial cells supported by a sparse population of collagen fibers



4.1.2 hepatic plates

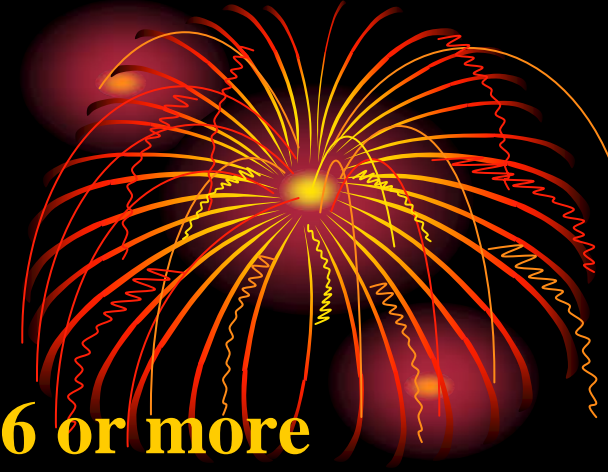- The hepatocytes are radially disposed and are arranged like the bricks of a wall named hepatic plate. These cellular plates are directed from the periphery of the lobule to its center and anastomose freely, forming a labyrinthine and spongelike structure.



hepatocytes

Structure

LM: Hepatocytes are polyhedral, with 6 or more surfaces, the cytoplasm of the hepatocyte is eosinophilic, mainly because of the large number of mitochondria and some smooth endoplasmic reticulum. basophilic granules in it, single nucleus or double nuclei, which is spherical, located in the centre of the cells. with a prominent nucleolus and scattered chromatin granules

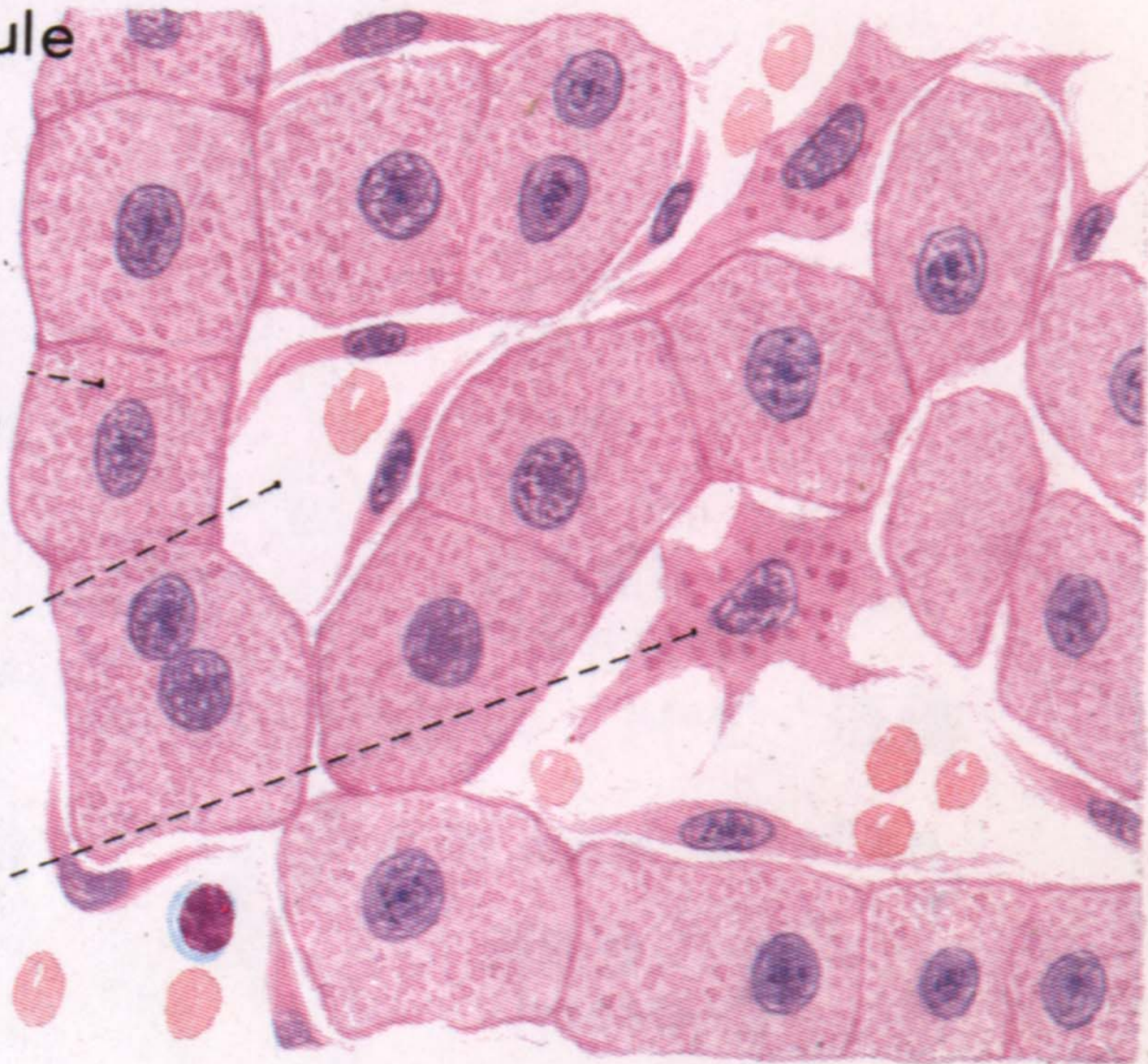


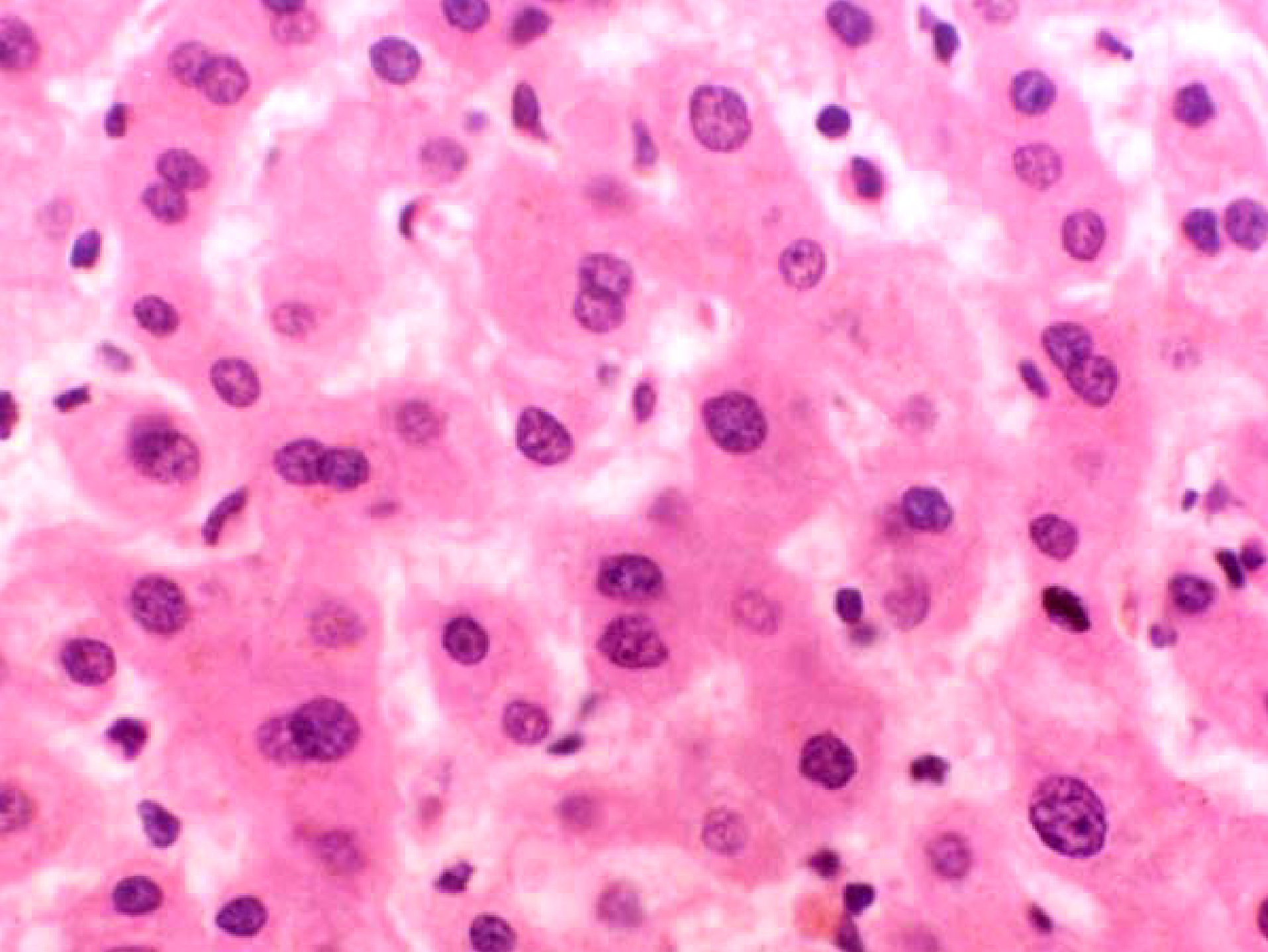
hepatic lobule

肝细胞
Hepatocyte

肝血窦
Hepatic sinusoid

肝巨噬细胞
Kupffer cell





EM structure of hepatocyte

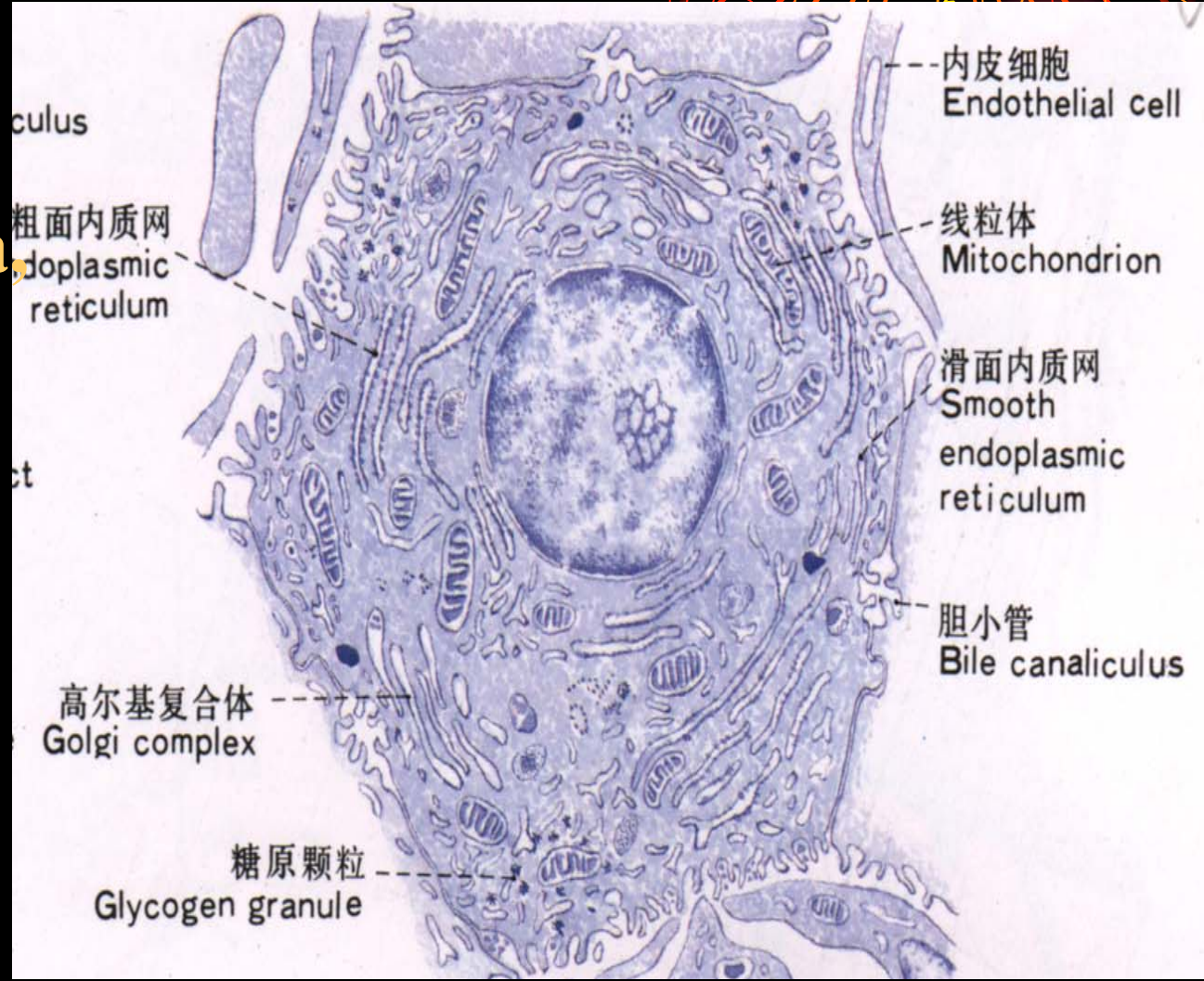


organelle:

large numbers
of mitochondria,

SER, RER,
Golgi complex,

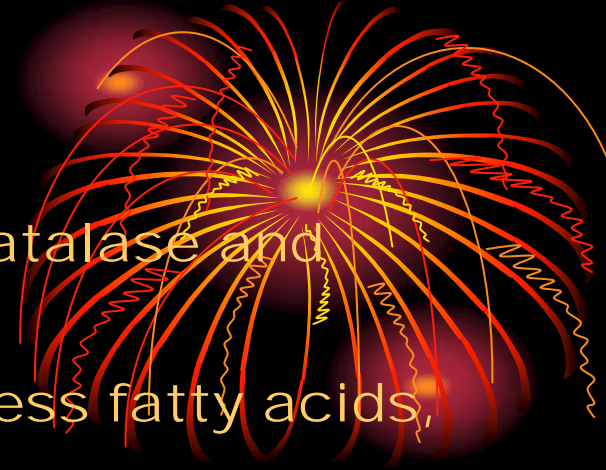lysosome,
microbody
inclusions



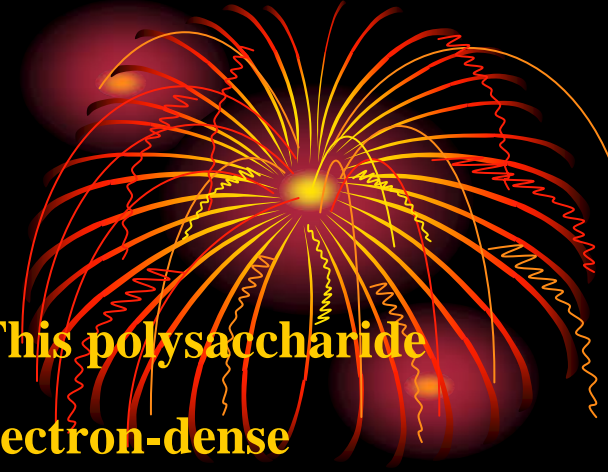- **Mitochondria:** supply energy to cells
- **RER:** several protein-eg, blood albumin, fibrinogen lipoprotein and transferrin
- **SER:** synthesizing and secreting bile, metabolism of lipids and hormones and detoxification , the proceses of oxidation,methylation,conjugation of various substances
- **Golgi complex:** formation of lysosomes and the secretion of plasma proteins, glycoproteins ,lipoproteins
- **Lysosome:** in the normal replacement of cellular components and organelles,as well as in cellular defense mechanisms



- Microbody(Peroxisomes): contain catalase and oxidative enzymes, oxidation of excess fatty acids, break down of the hydrogen peroxide, break down of excess purines to uric acid, participation in the synthesis of cholesterol, bile acids, and some lipids used to make myelin



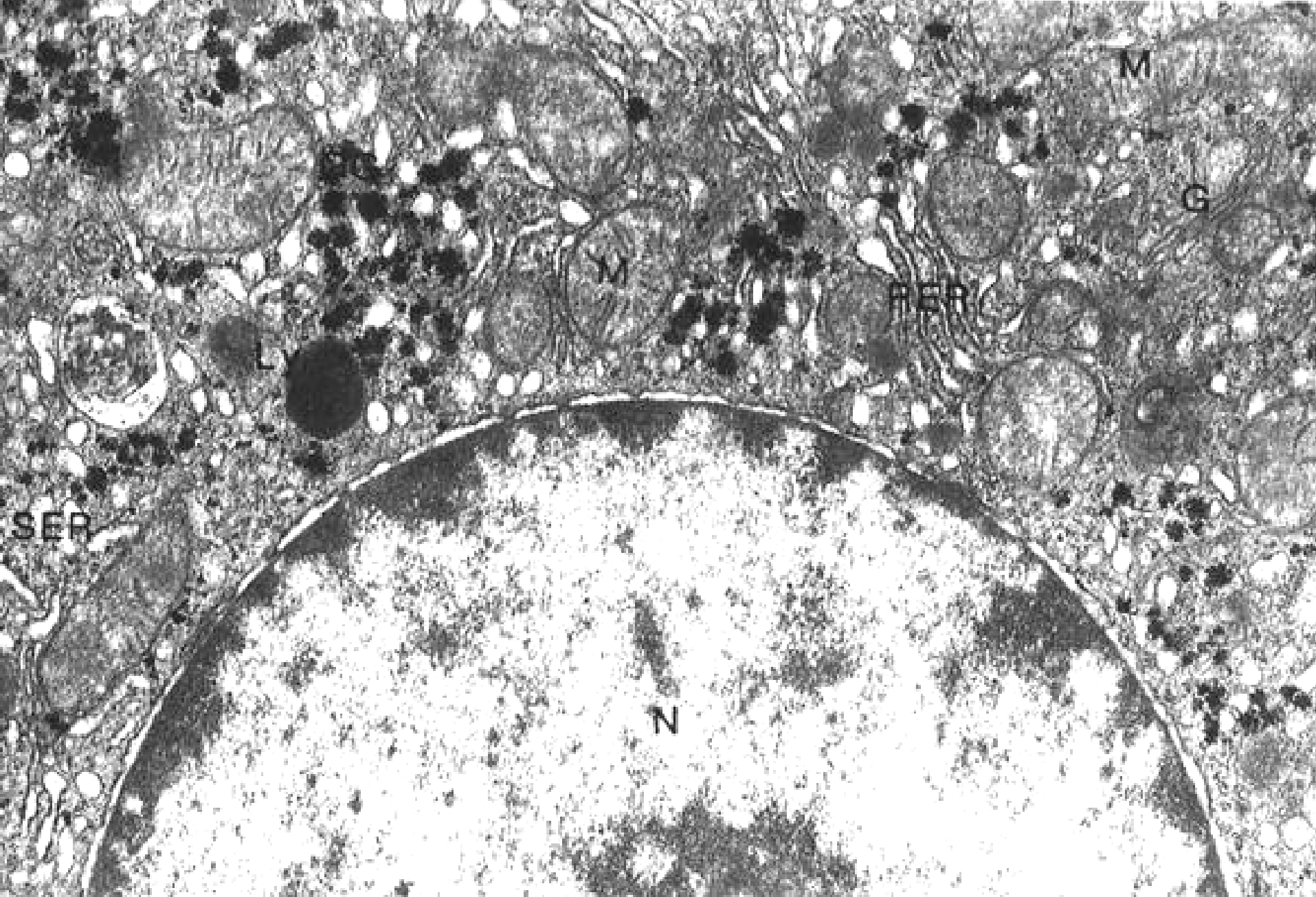
Inclusions

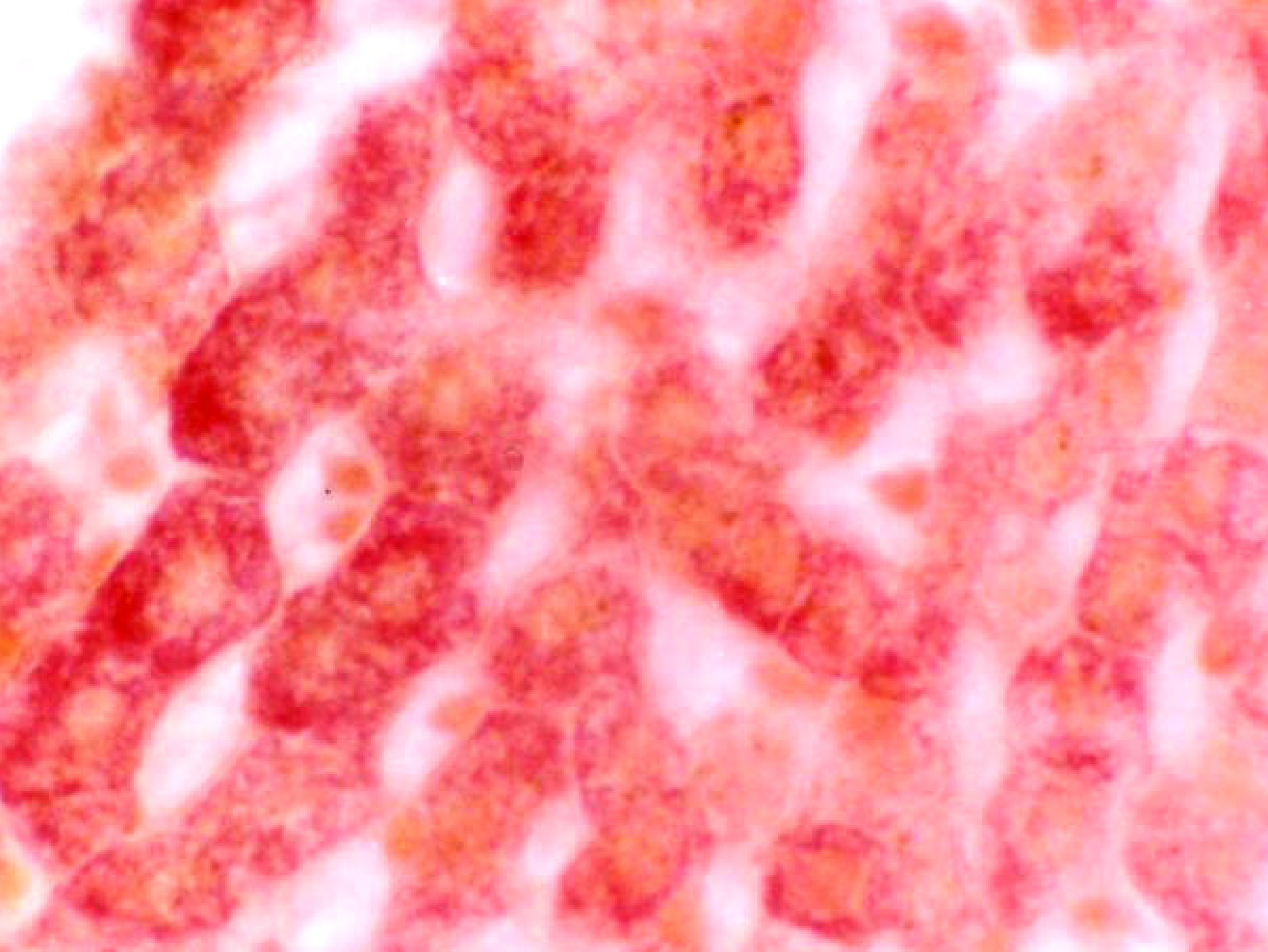


- The hepatocyte frequently contains **glycogen**. This polysaccharide appears in the electron microscope as coarse, electron-dense granules that frequently collect in the cytosol close to the smooth endoplasmic reticulum . The amount of glycogen present in the liver conforms to a diurnal rhythm; it also depends on the nutritional state of the individual. Liver glycogen is a depot for glucose and is mobilized if the blood glucose level falls below normal. In this way, hepatocytes maintain a steady level of blood glucose, one of the main sources of energy for use by the body.

lipid droplets

- **pigment**

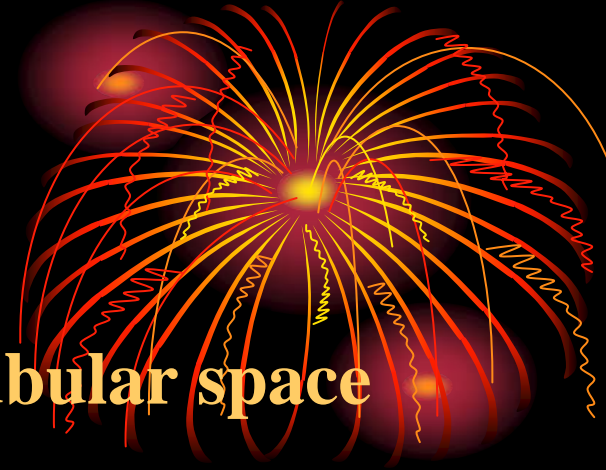

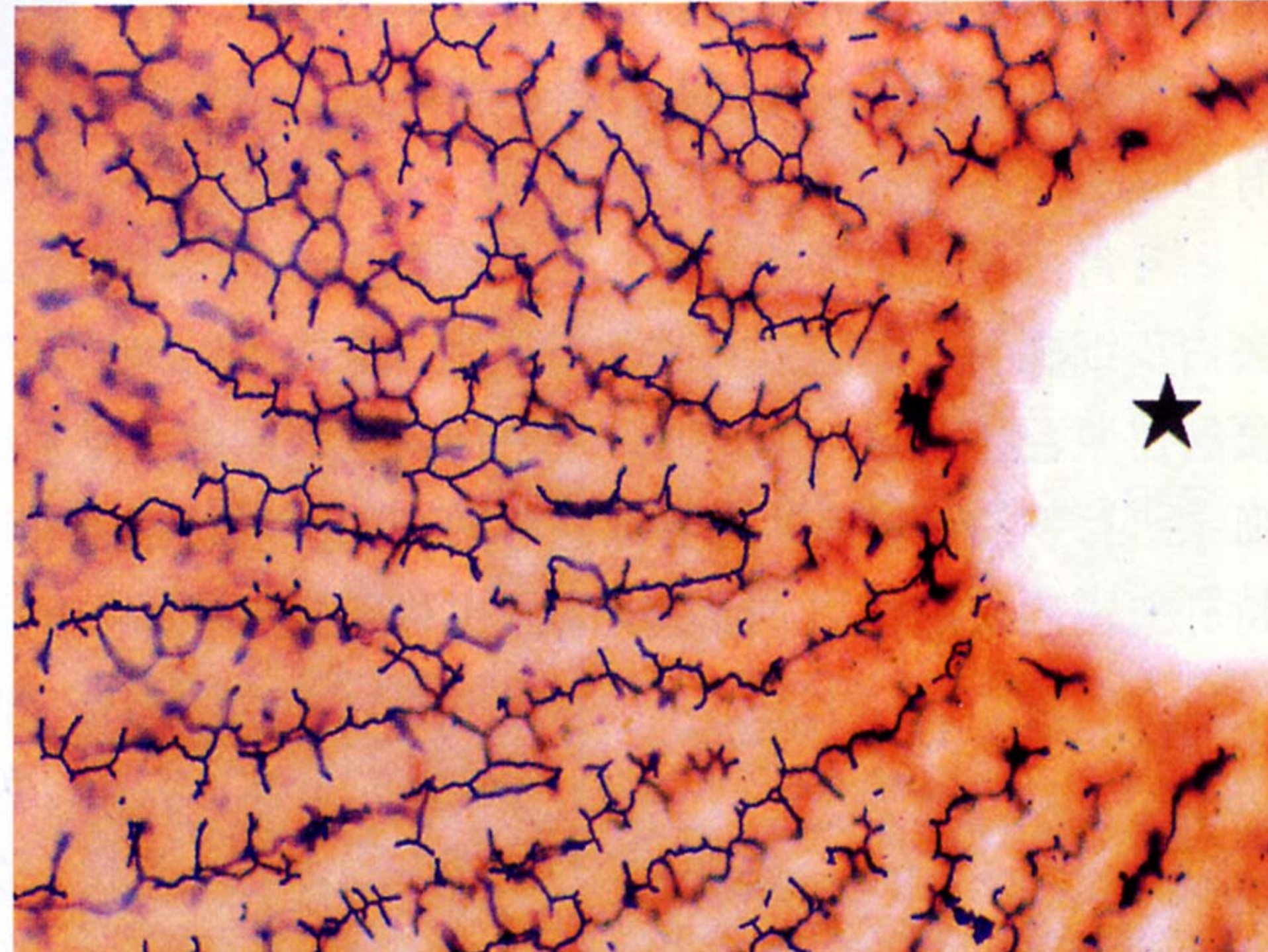


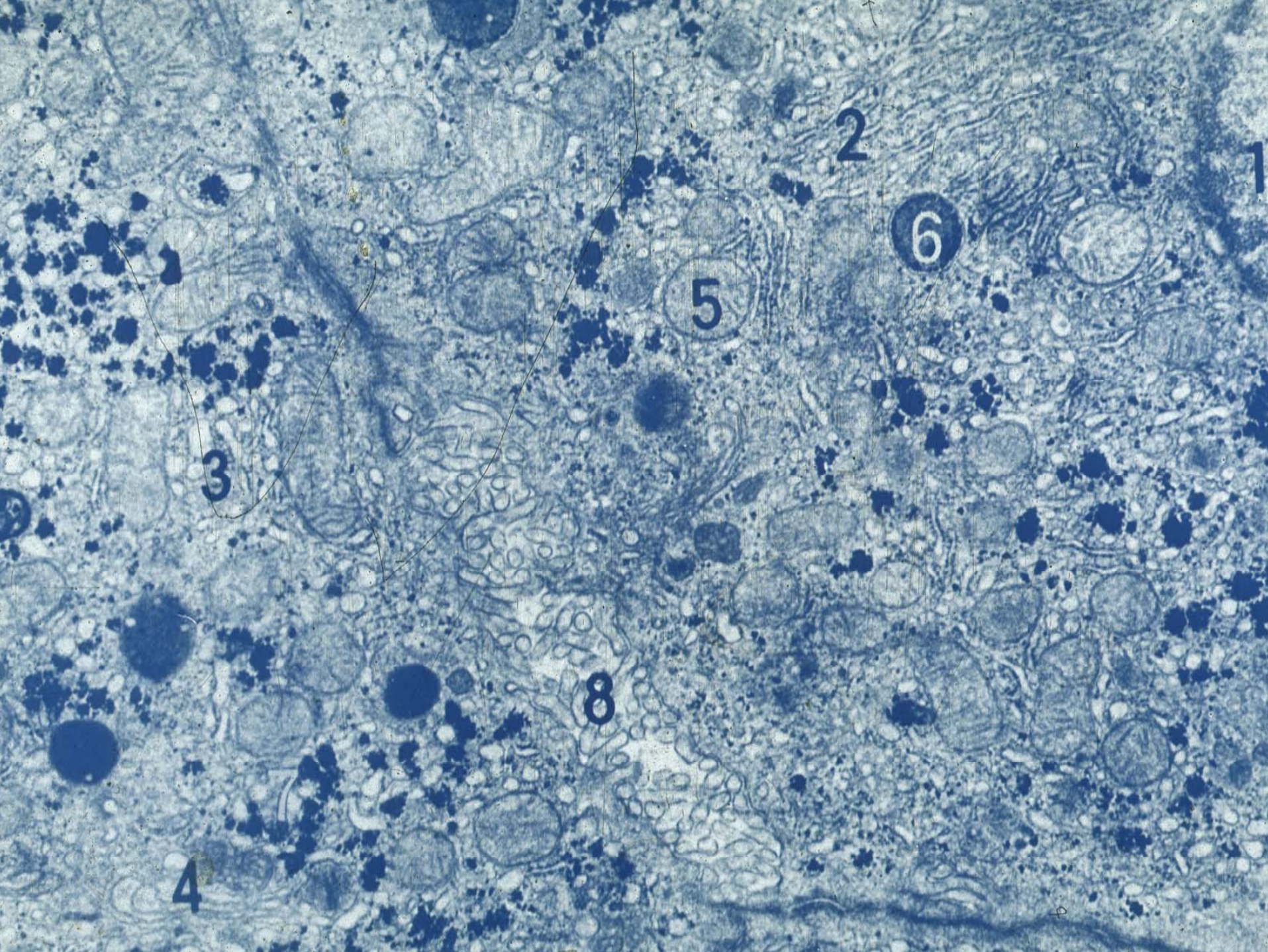
bile canaliculi

2 hepatocytes abut, they delimit a tubular space between them known as bile canaliculus in which have a small number of microvilli.

The cell membranes near these canaliculi are firmly bound by tight junction, desmosomes and gap junction.







2

6

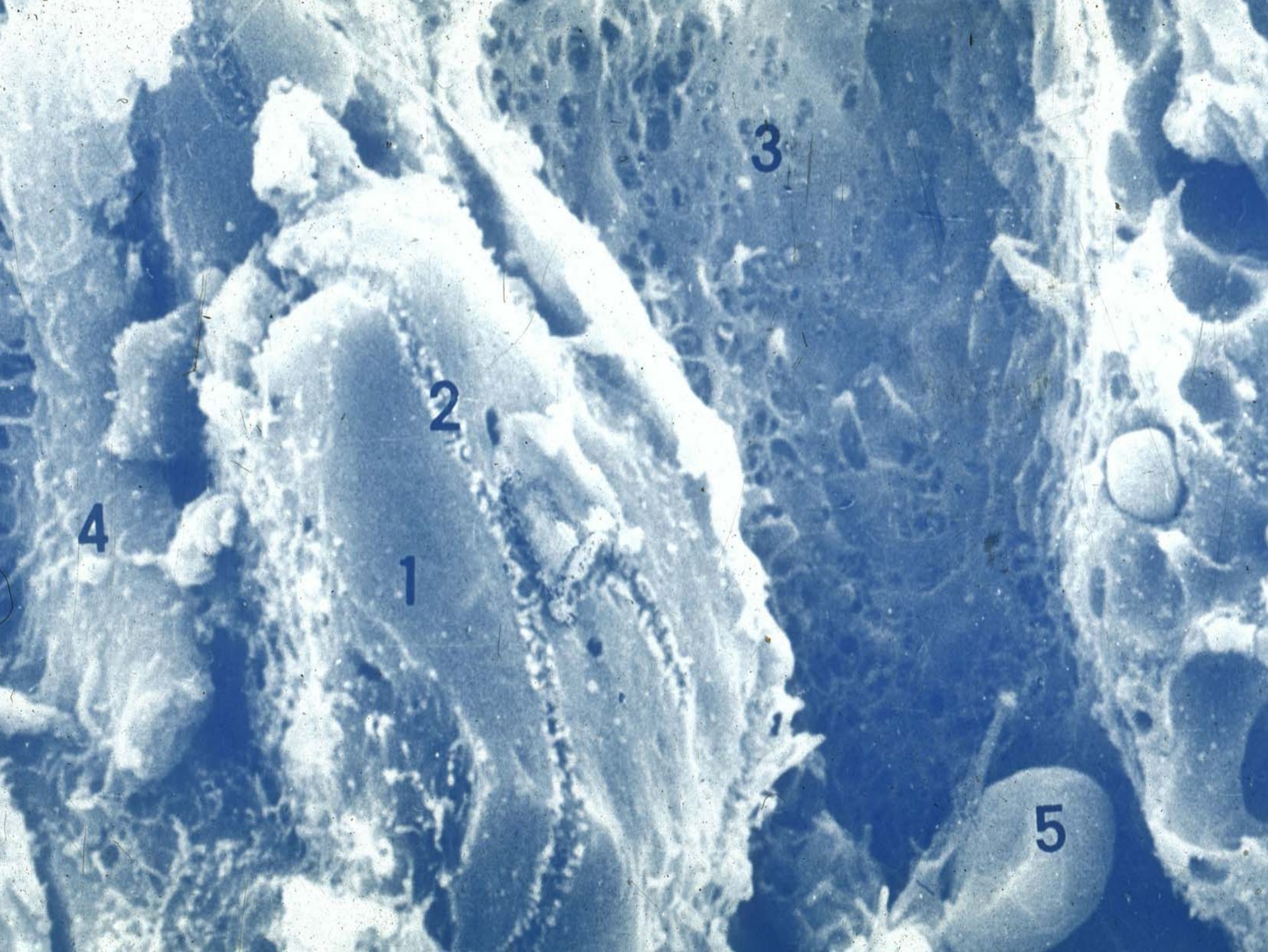
5

3

8

4

P



3

2

1

4

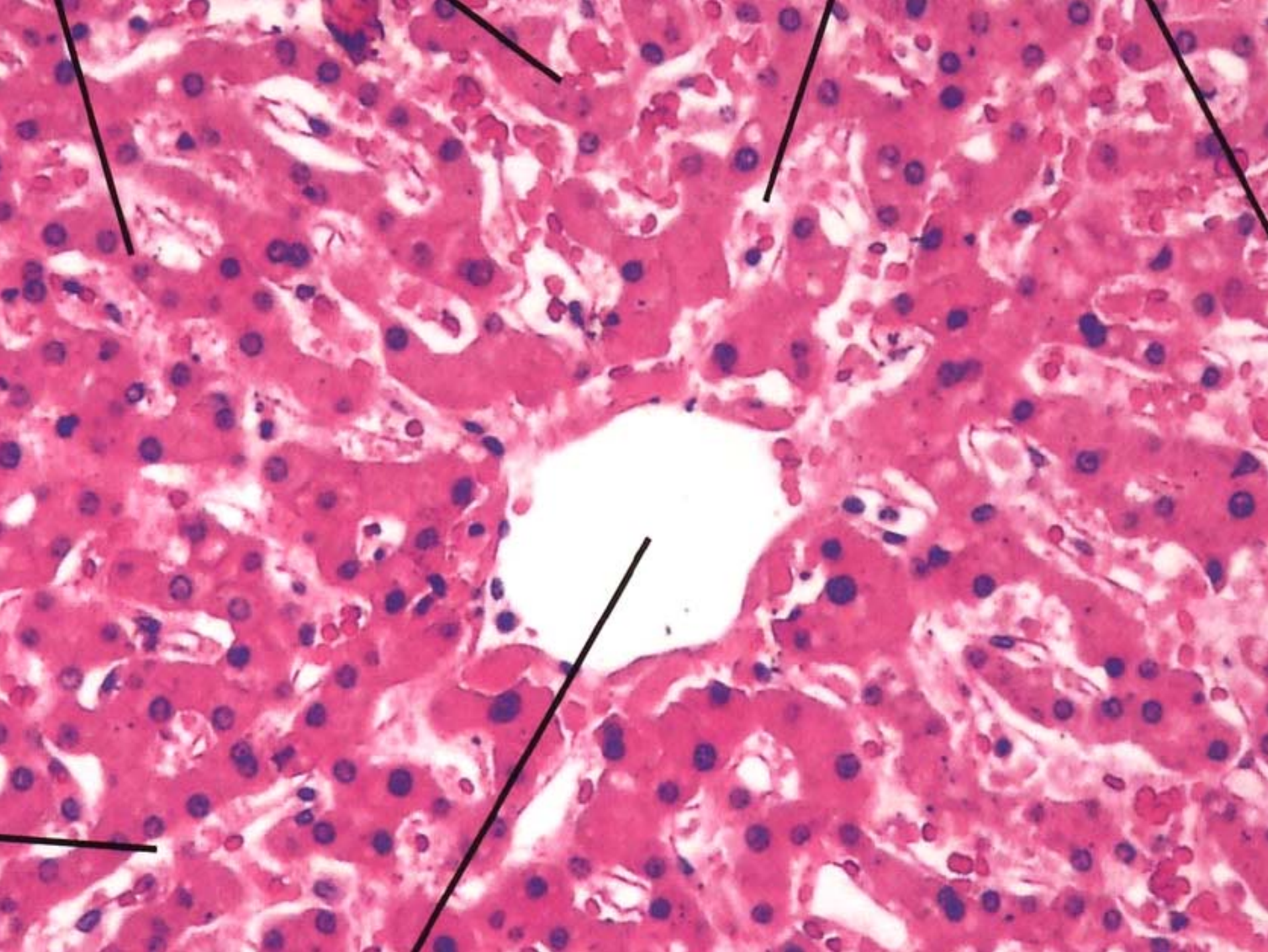
5

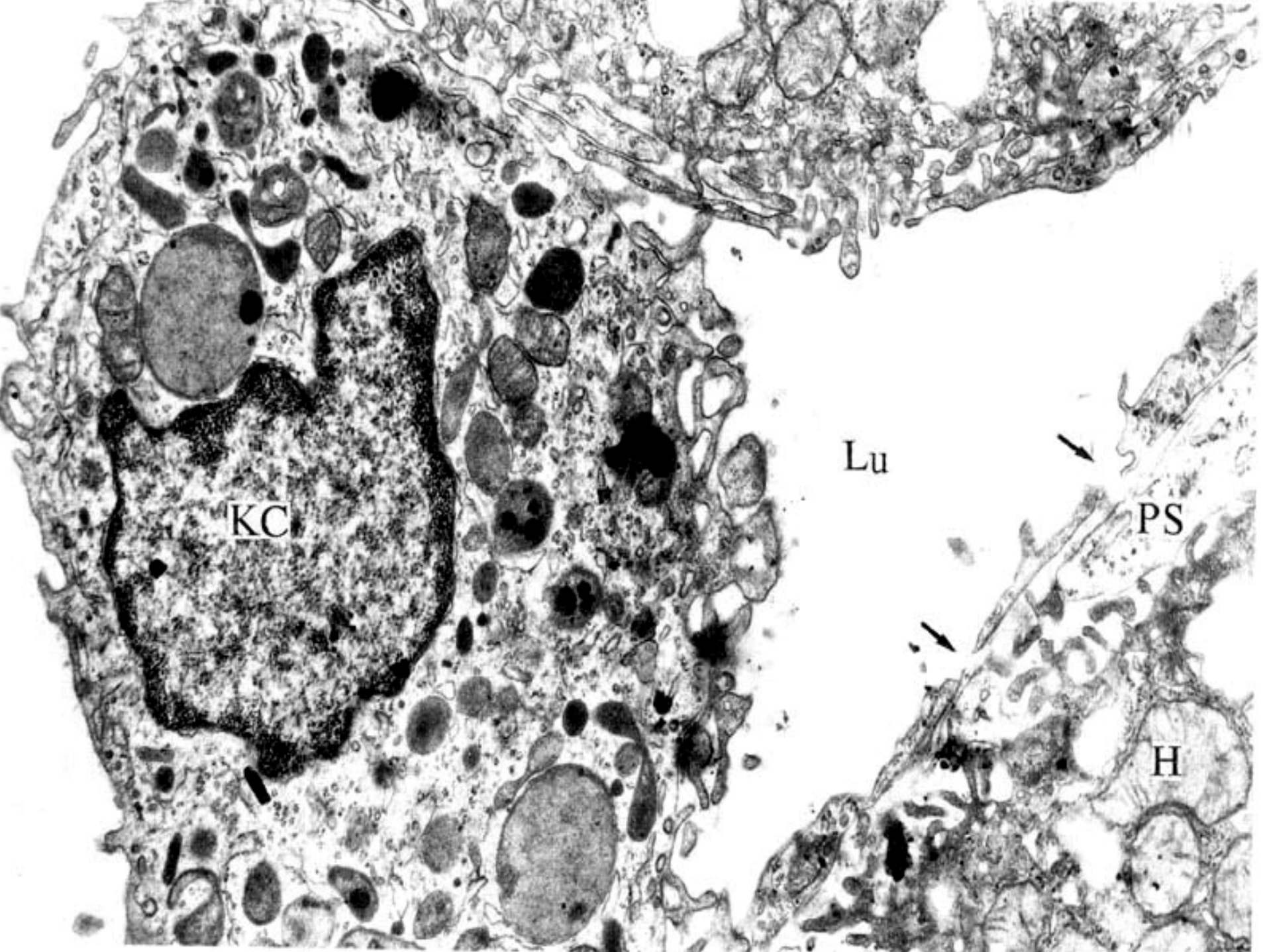
hepatic sinusoid

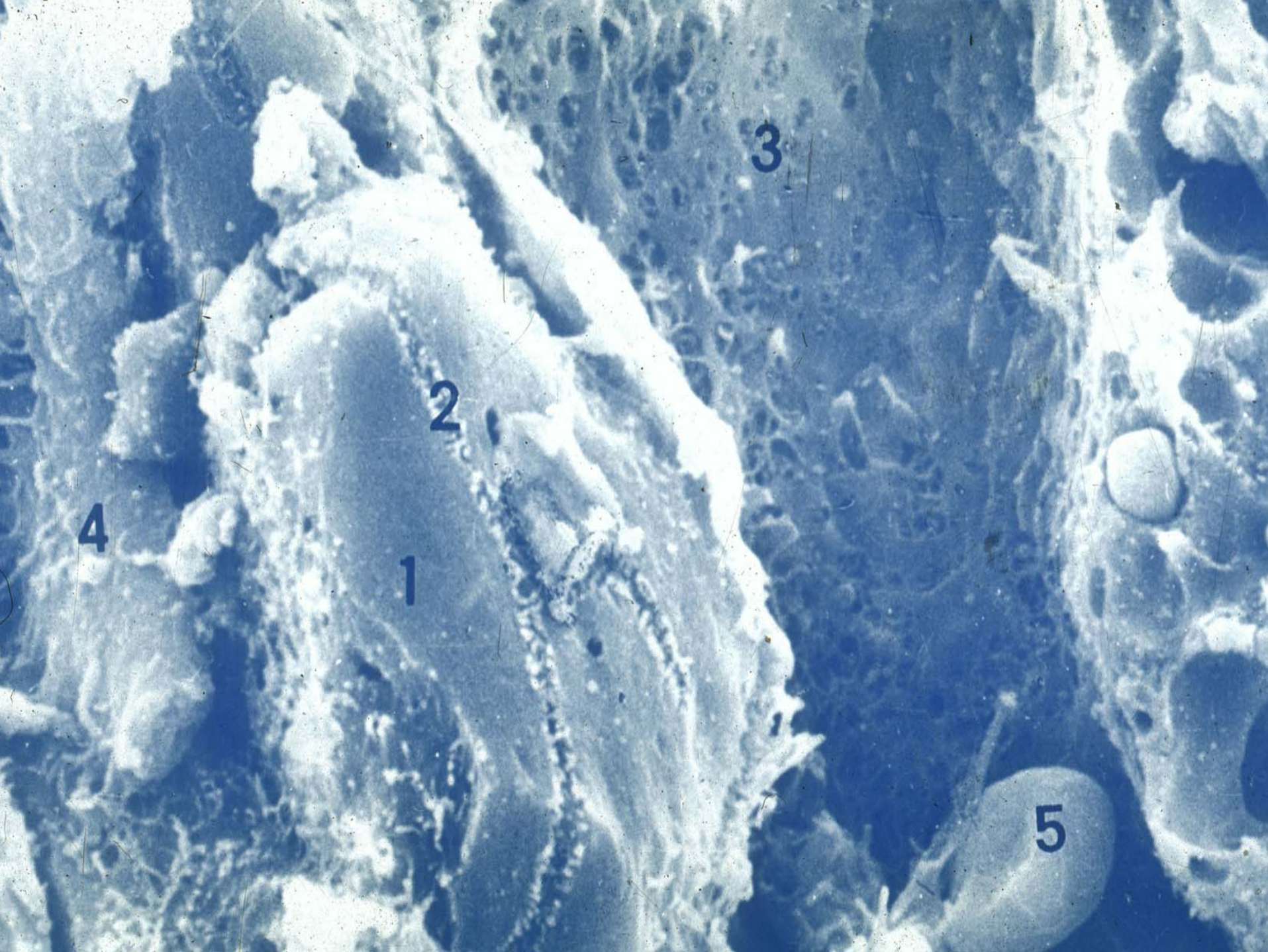


between hepatic plates sponge work

**Wall of sinusoid: fenestrated endothelium, no
basement membrane,
macrophages(Kupffer cells)
and large granules cells in
lumen of sinusiod**







3

2

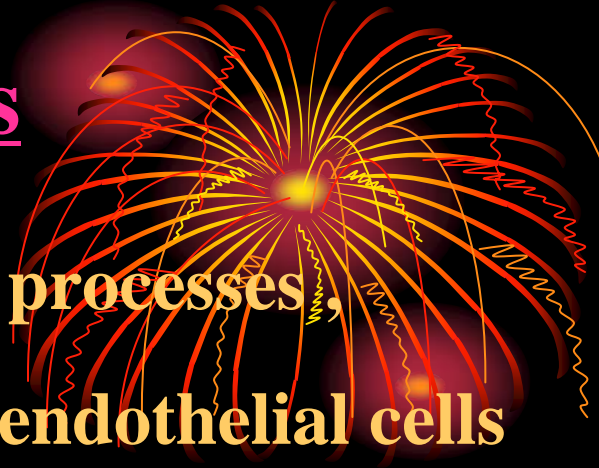1

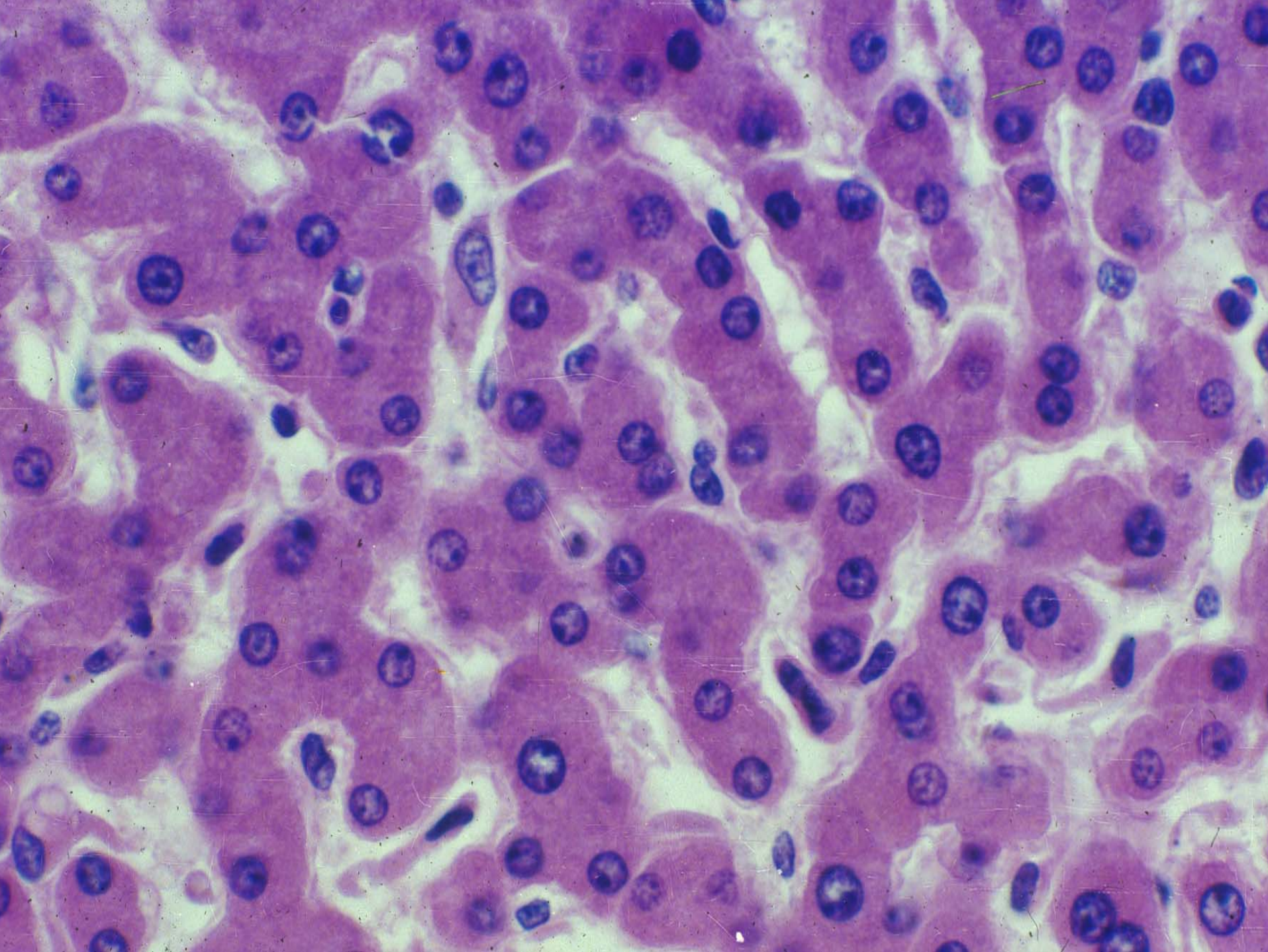
4

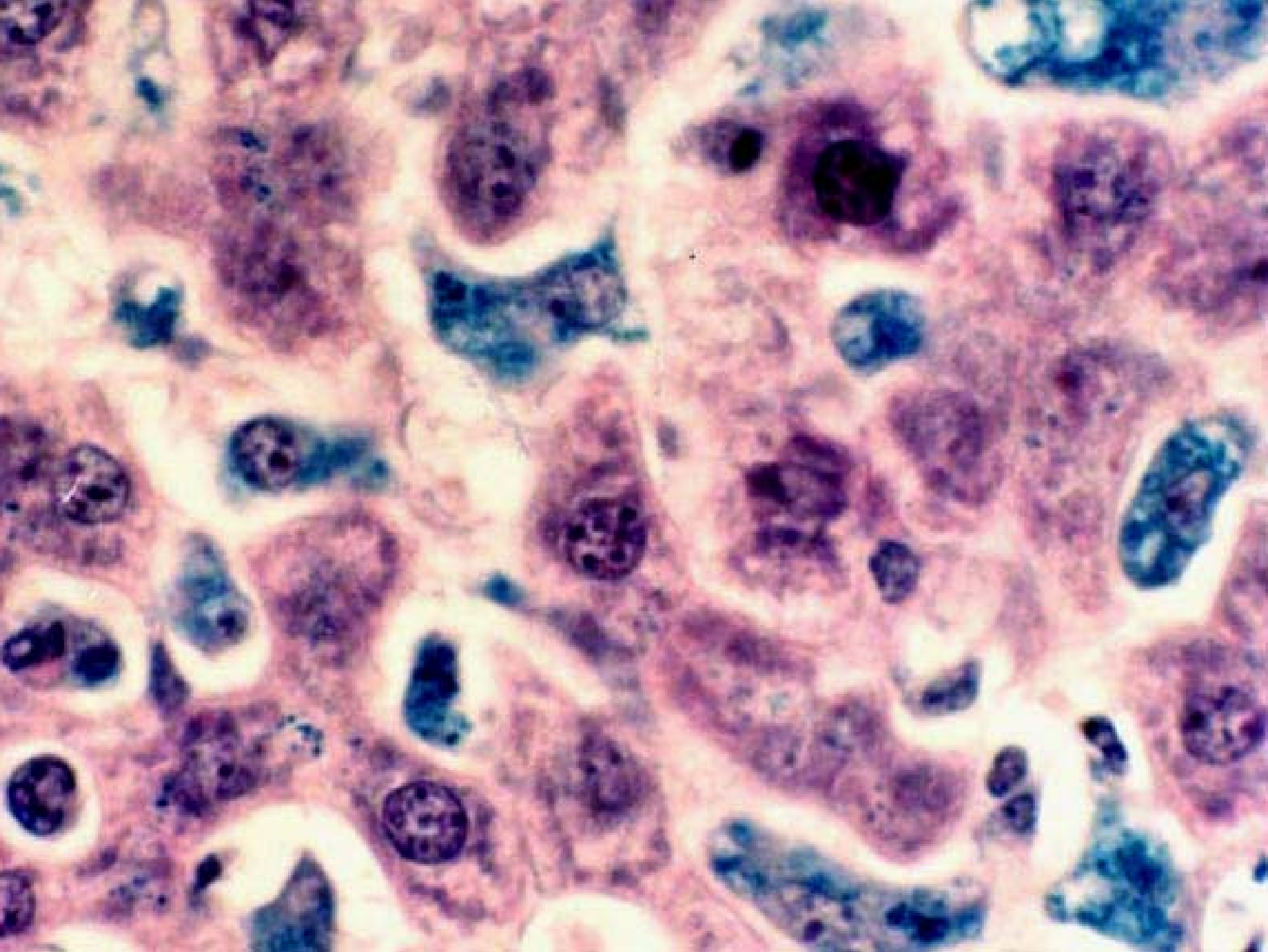
5

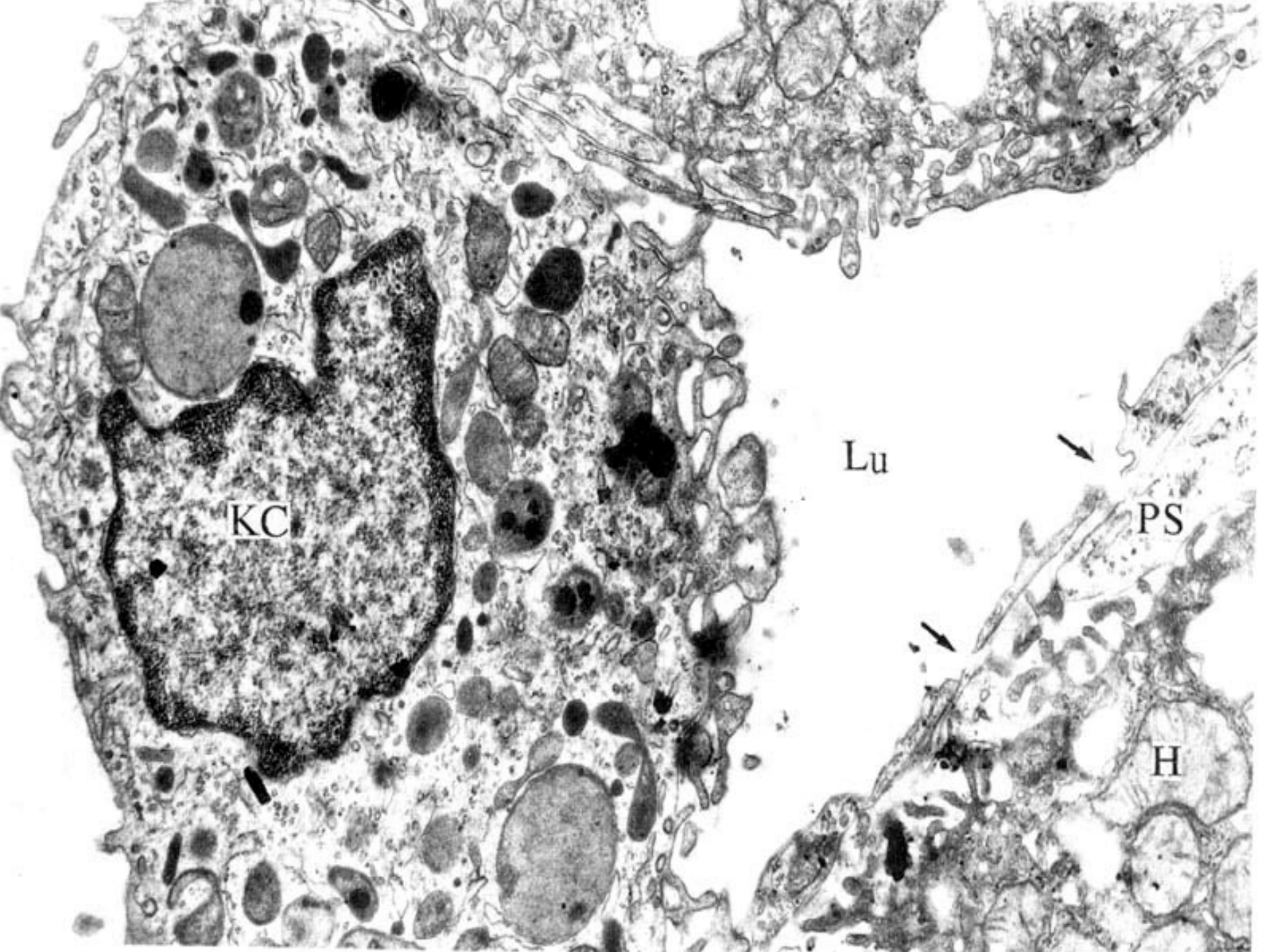
Hepatic macrophages

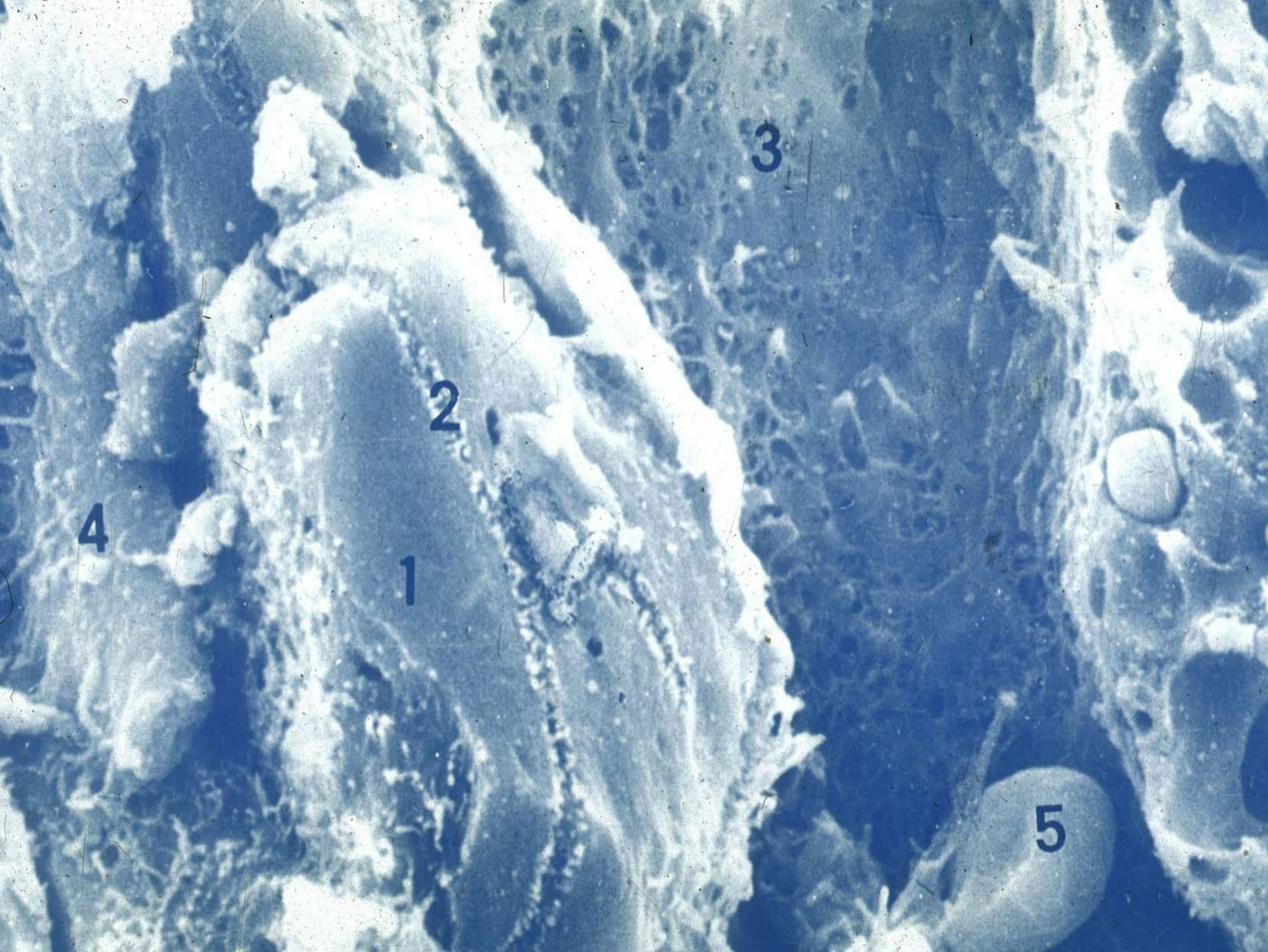
so called Kupffer cells, the cells with processes, location on the luminal surface of the endothelial cells or between them. In electron micrographs, Kupffer cells can be identified by the presence of large numbers of lysosomes in the cytoplasm. They phagocytose remnants of degenerating red cells and are involved in the metabolism of haemoglobin.











3

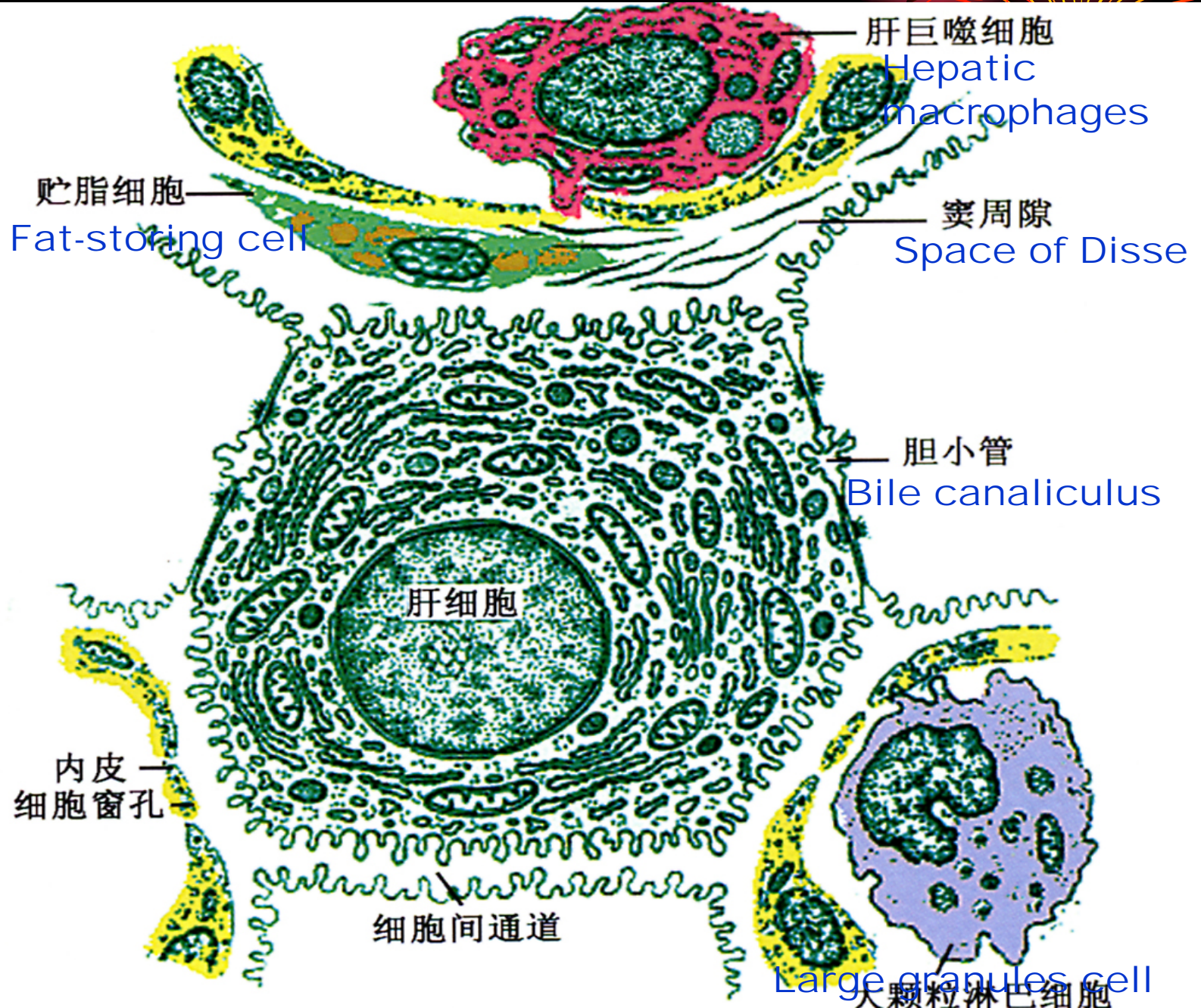
2

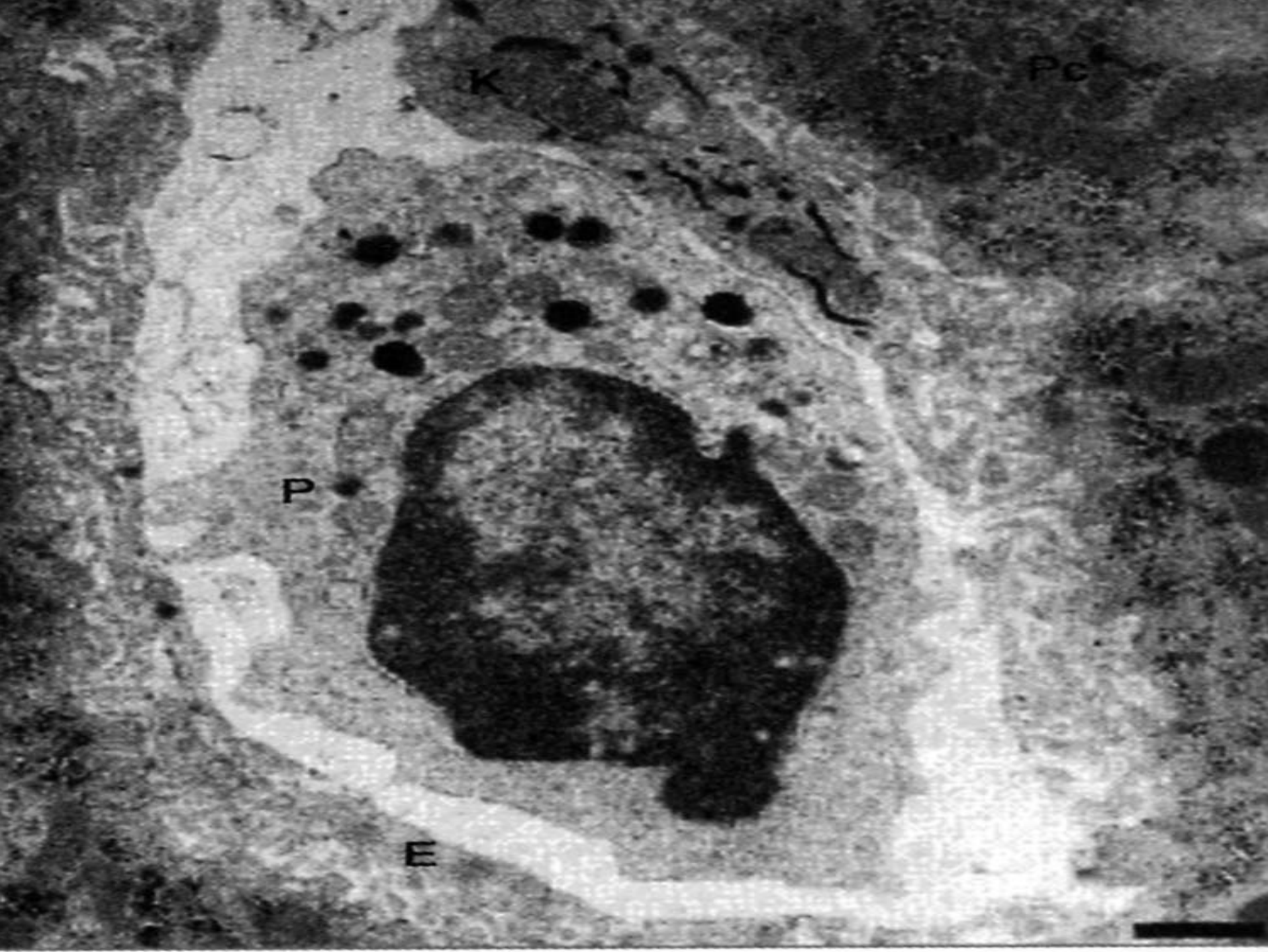
1

4

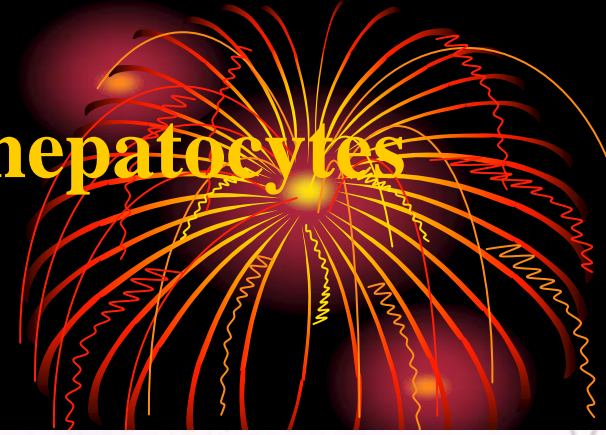5

large granules cells





Three function surfaces of the hepatocytes

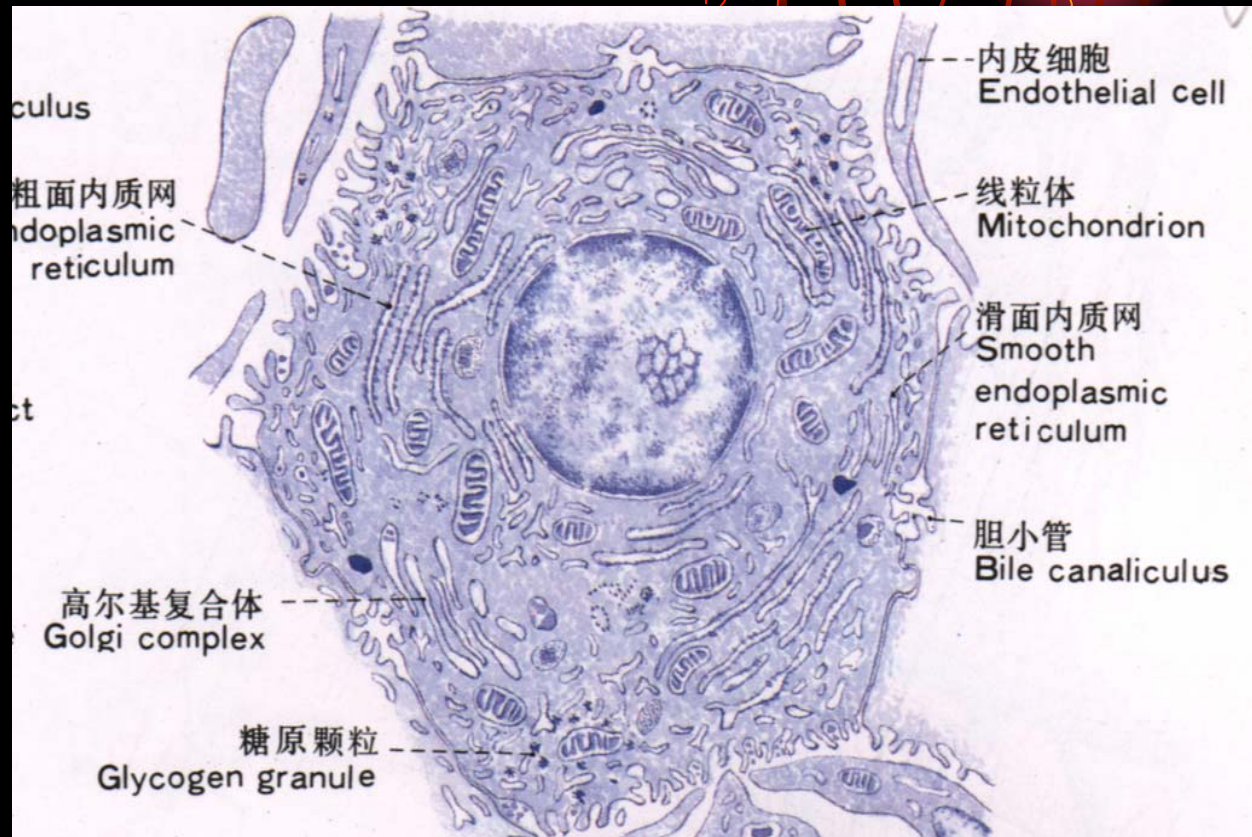


Facing the sinusoids

Contacting with adjacent

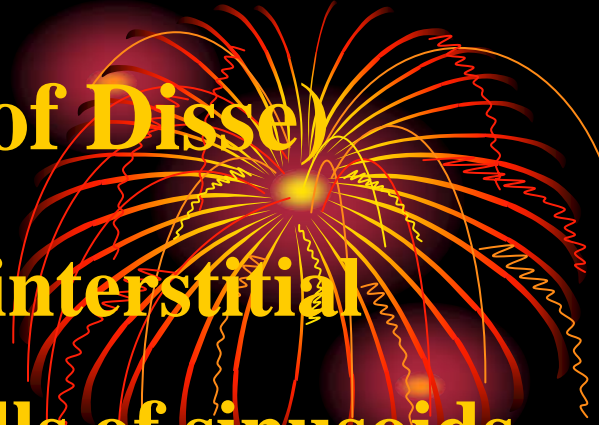
cells



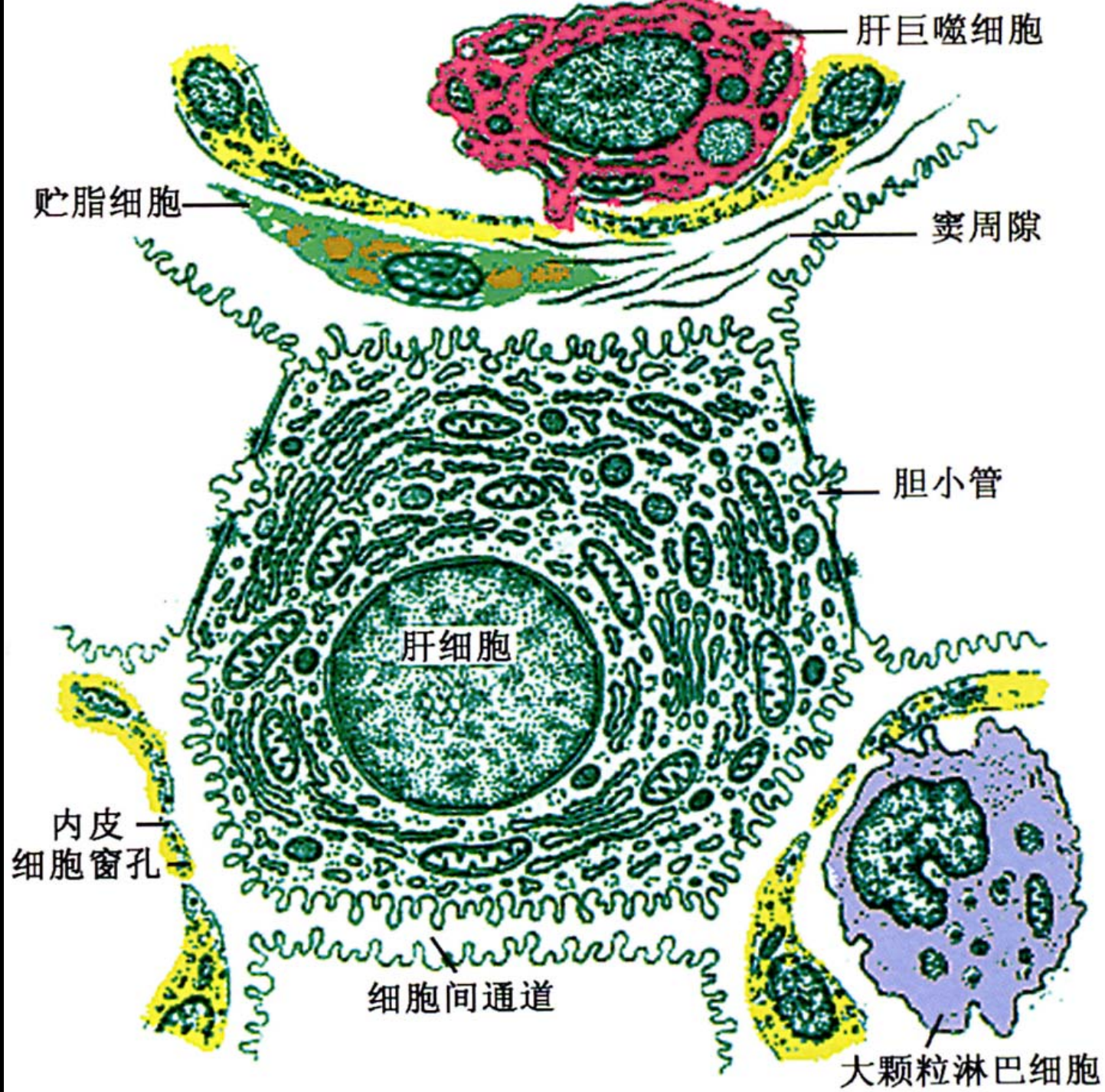
Facing a bile canaliculus

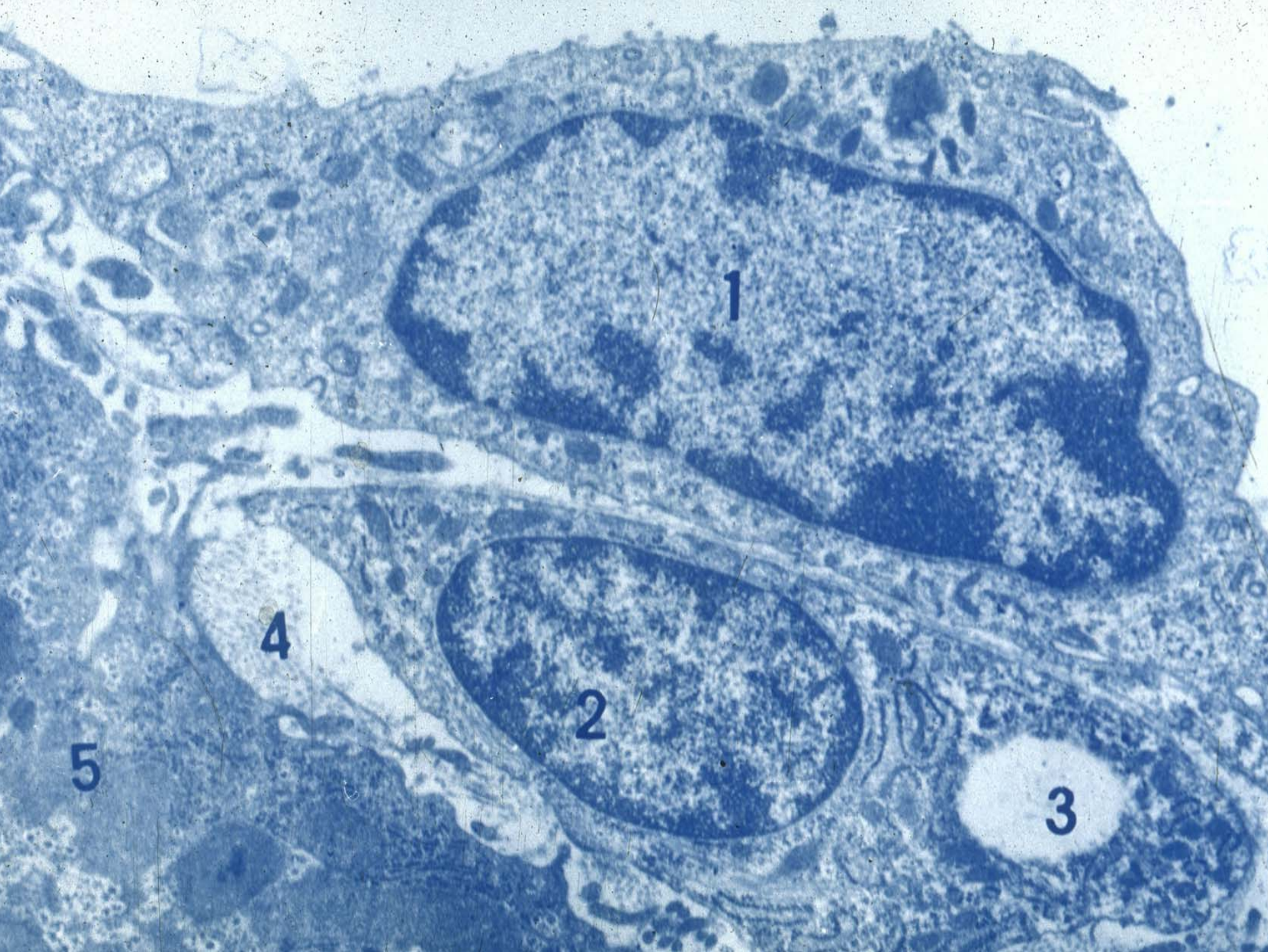


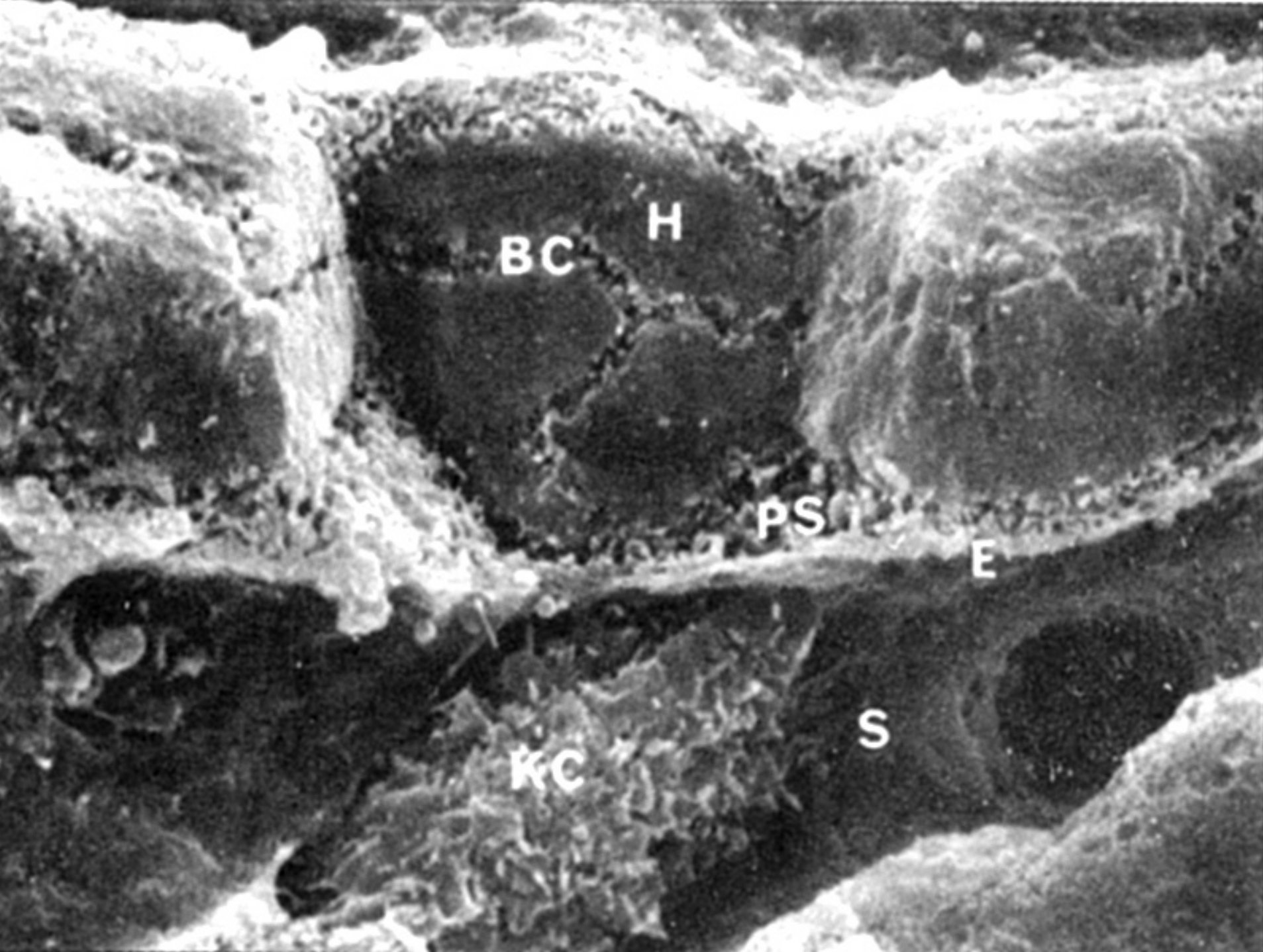
perisinusoidal space(space of Disse)

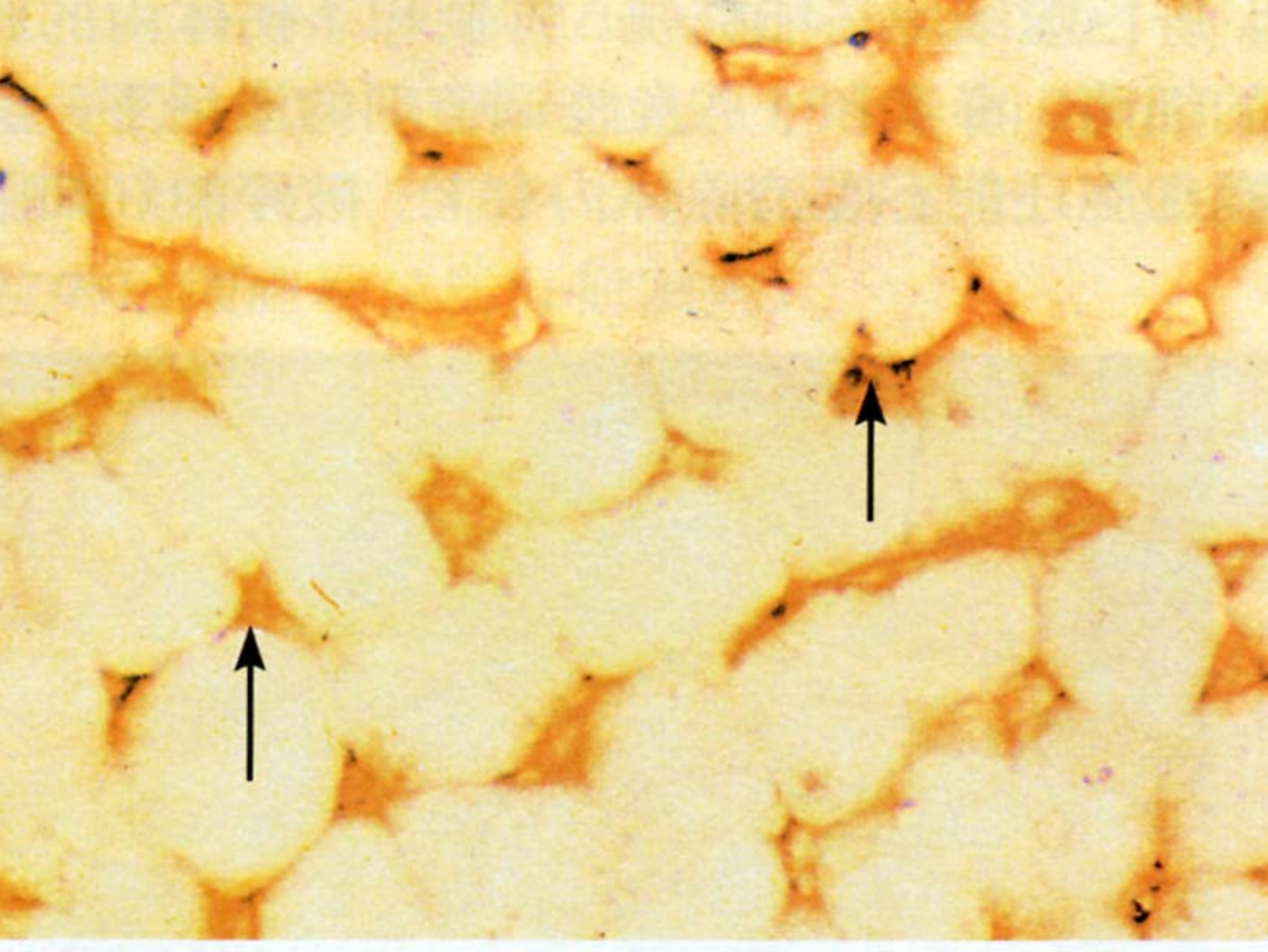
- The perisinusoidal space is an interstitial space between the endothelial cells of sinusoids and the hepatocytes
- allowing active metabolic exchange between the liver and the plasma. small numbers of fat-storing cells (lipocyte) are found in the perisinusoidal space . They contain fat droplets and store vitamin A

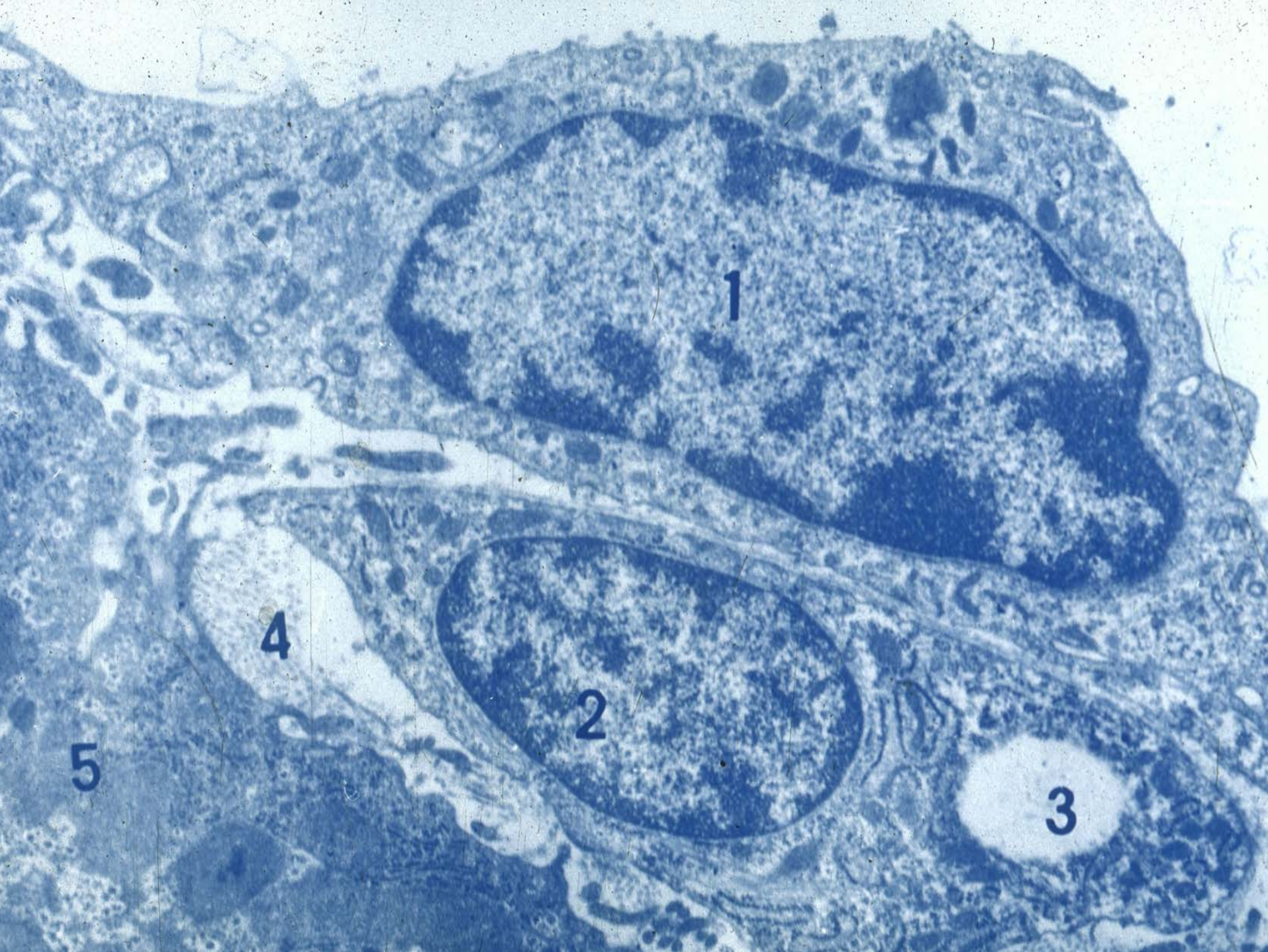














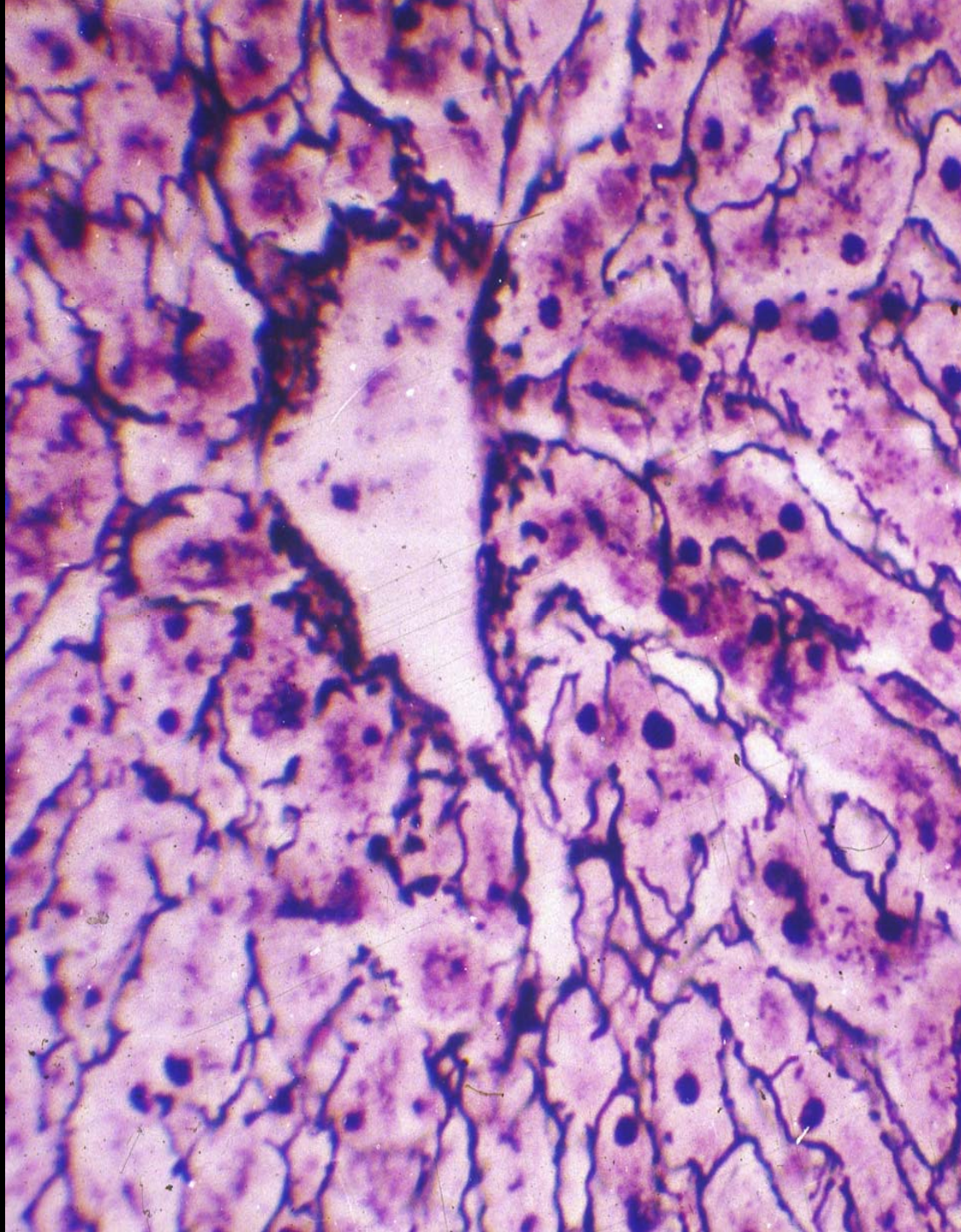
1

2

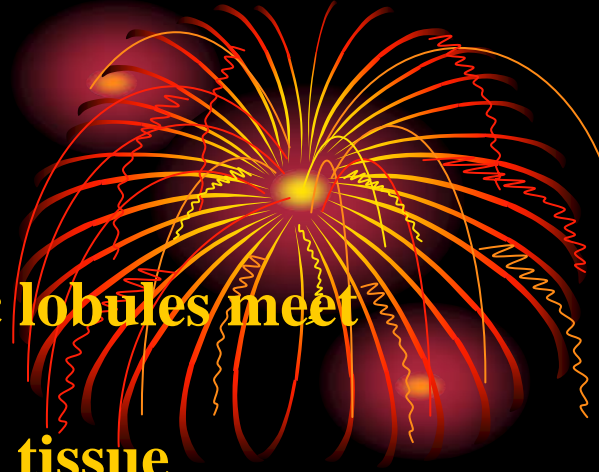3

4

5



4.2 port areas



Are found in the angles where adjacent hepatic lobules meet

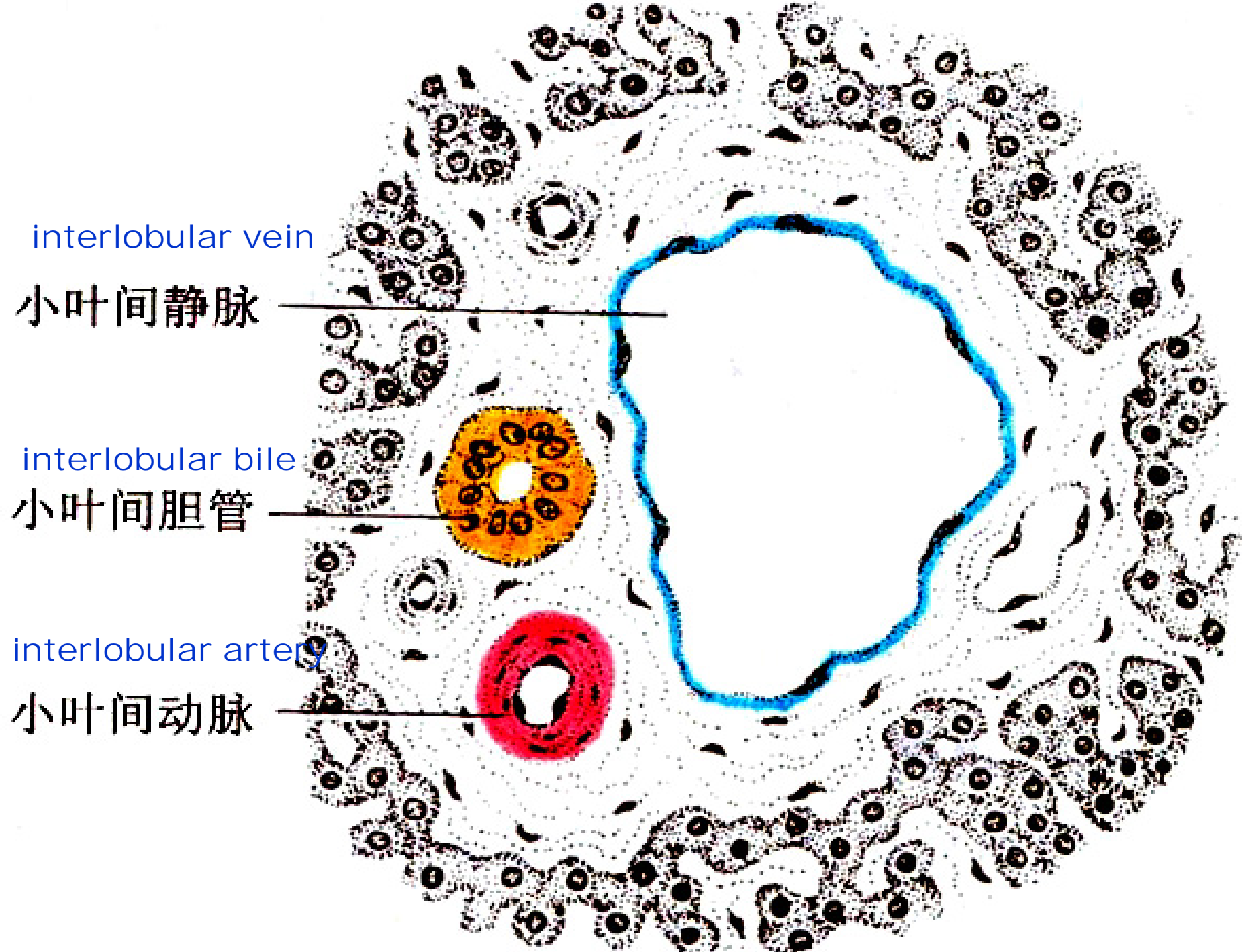
are surrounded by amounts of fibroconnective tissue

Comprises interlobular arteries: the branches of hepatic artery

interlobular veins: the branches of portal vein

interlobular bile duct: the branches of hepatic duct,

it makes up of simple cuboidal epithelium



interlobular vein

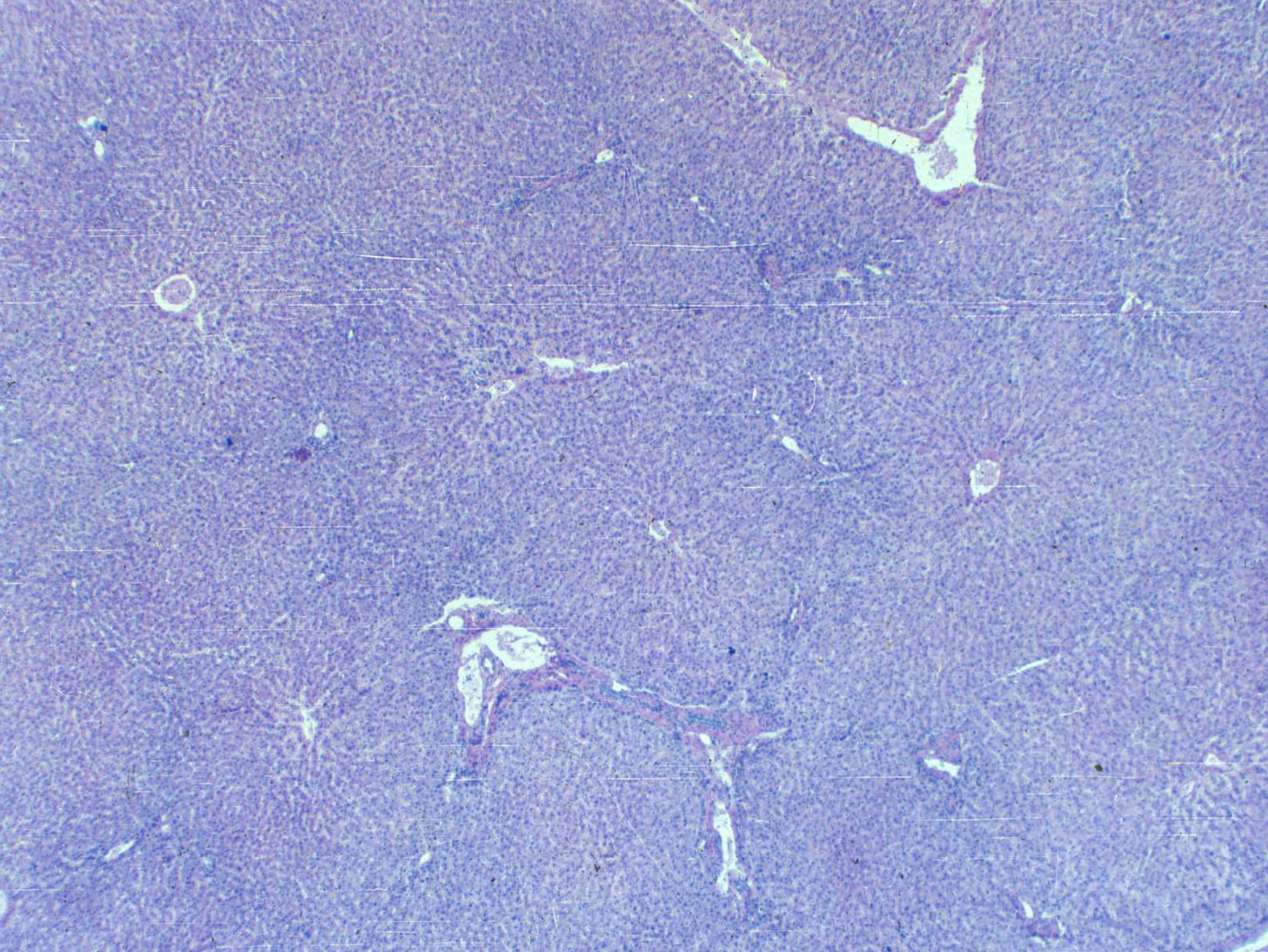
小叶间静脉

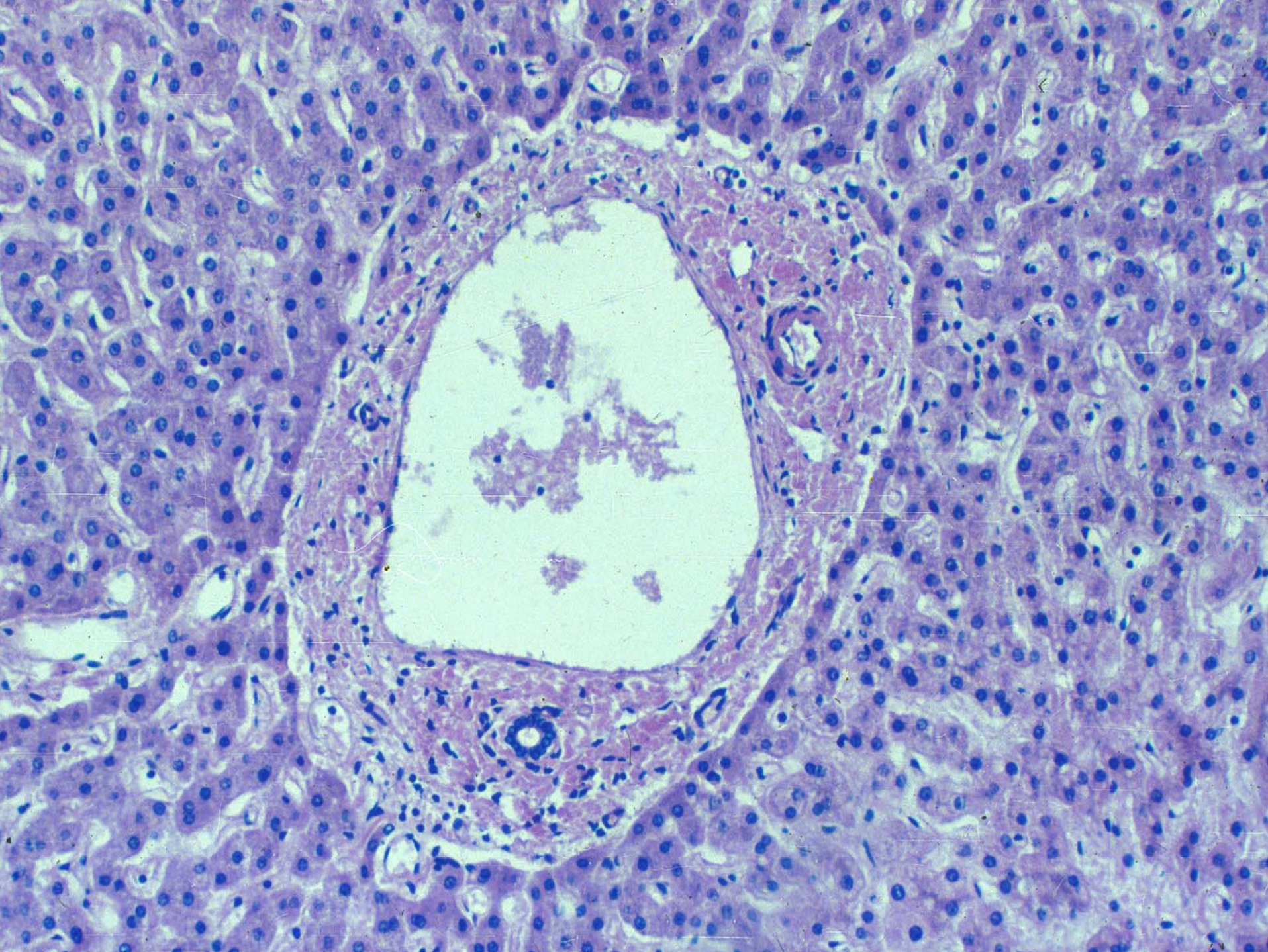
interlobular bile

小叶间胆管

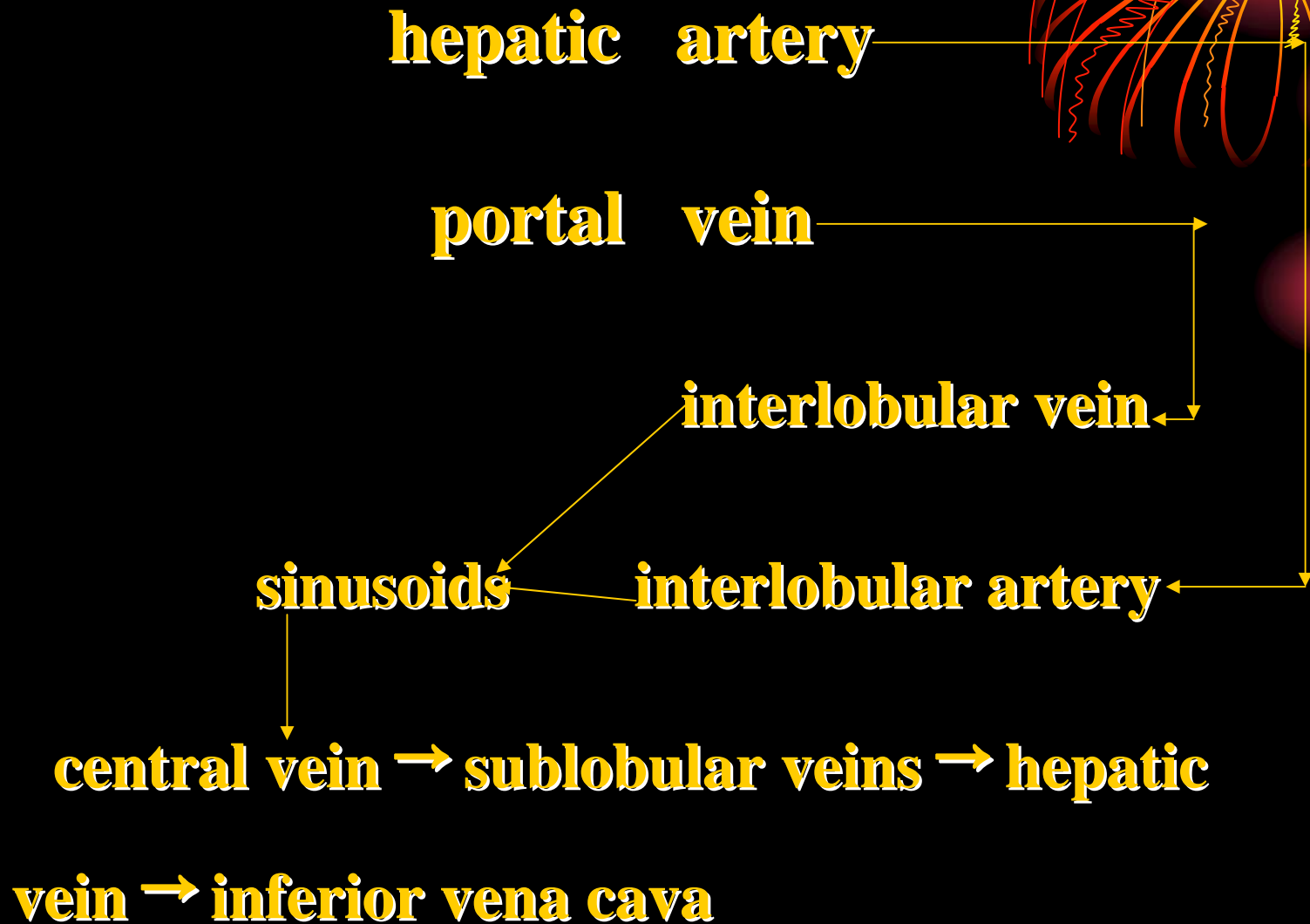
interlobular artery

小叶间动脉

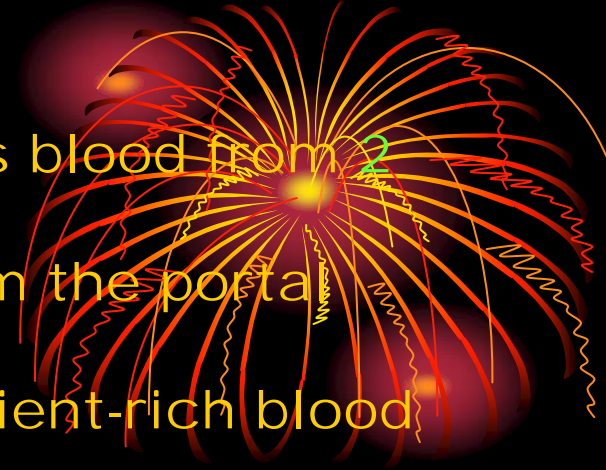

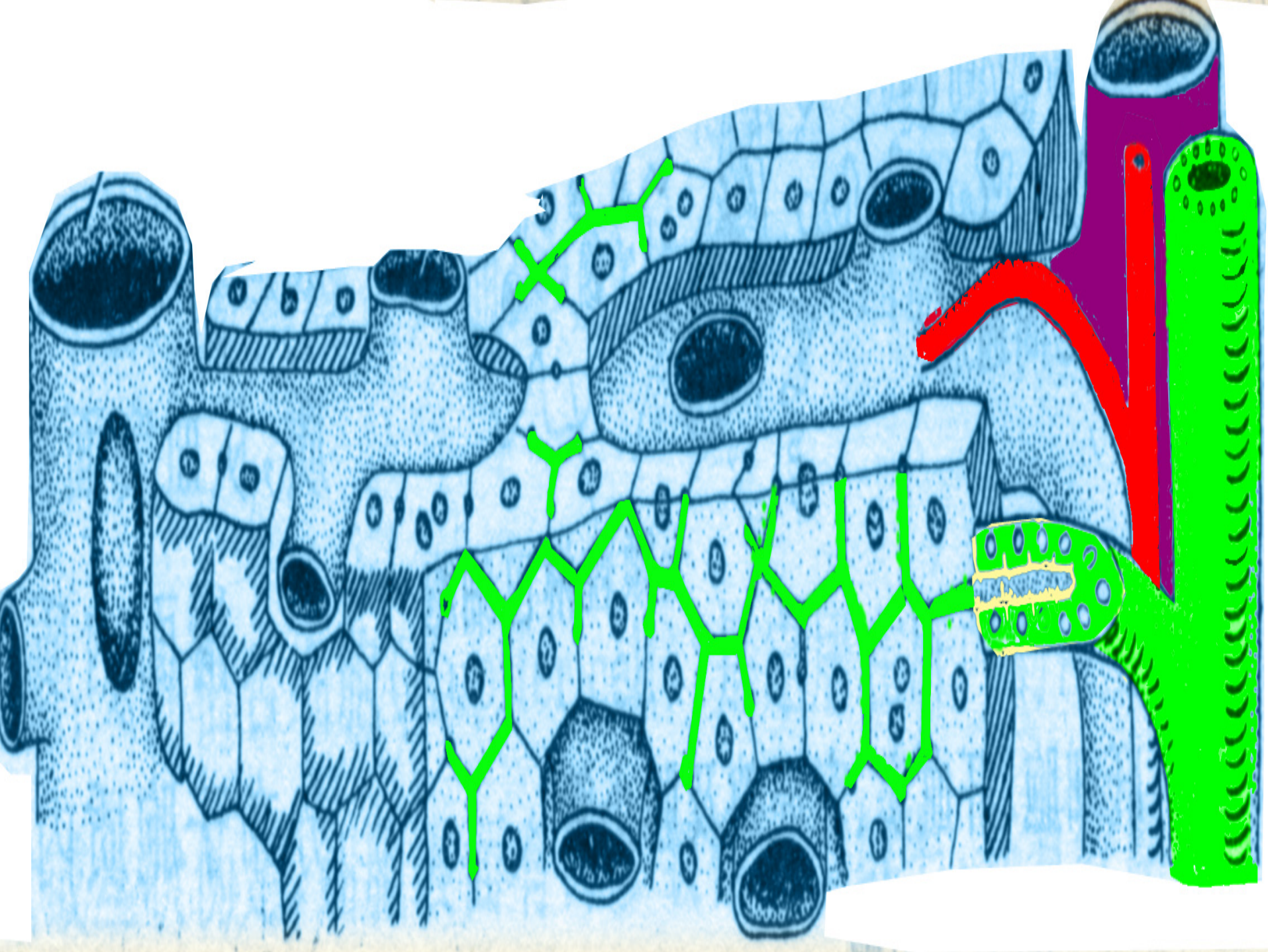


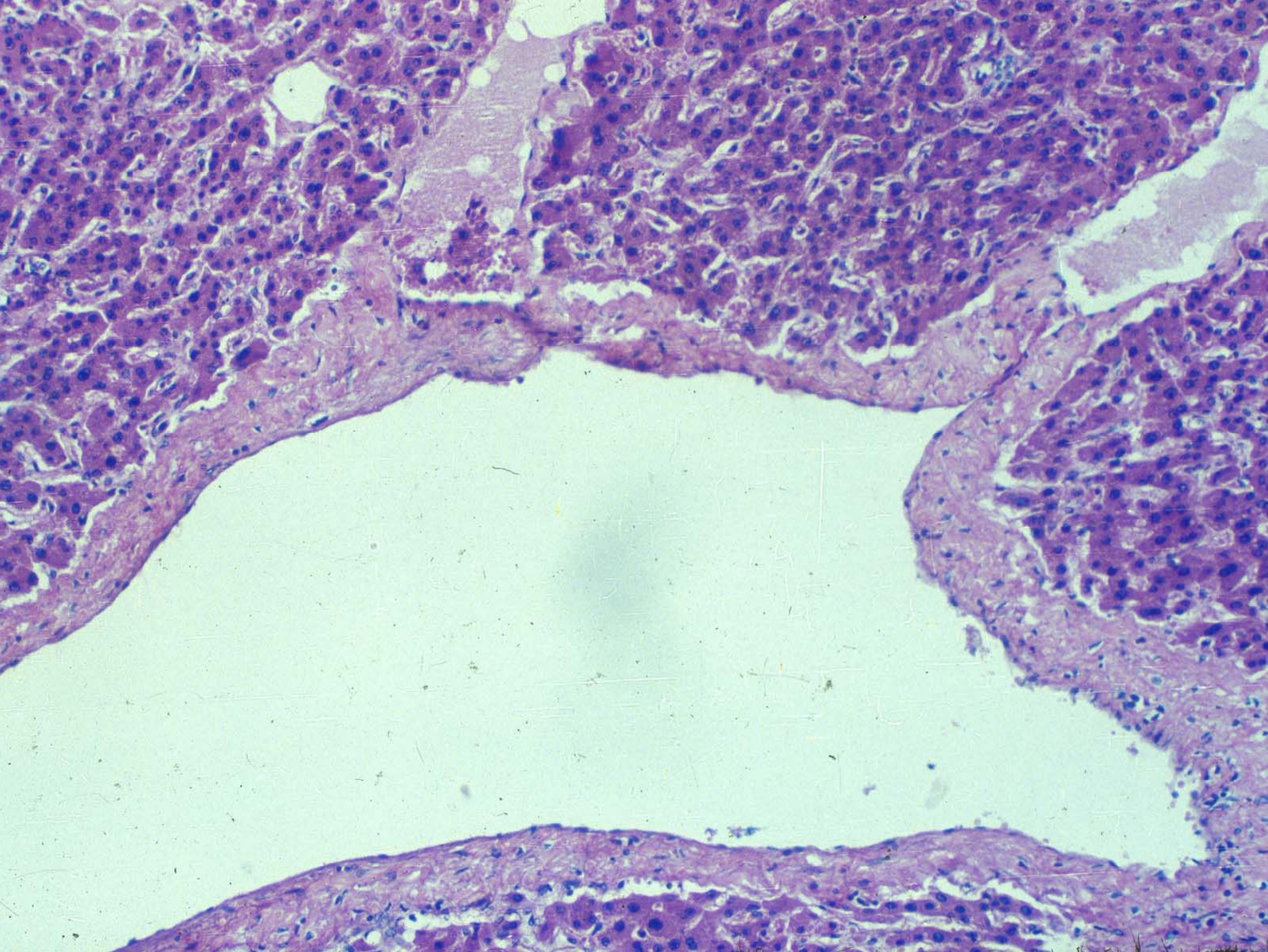
4.3 Blood supply of Liver



- The liver is unusual in that it receives blood from two sources: 80% of the blood derives from the portal vein, which carries oxygen-poor, nutrient-rich blood from the abdominal viscera, and 20% derives from the hepatic artery, which supplies oxygen-rich blood. Blood flow is directed from the periphery through the sinusoids between plates of hepatocytes to the central vein, blood is thereafter conveyed through sublobular veins, eventually drawing into the inferior vena cava

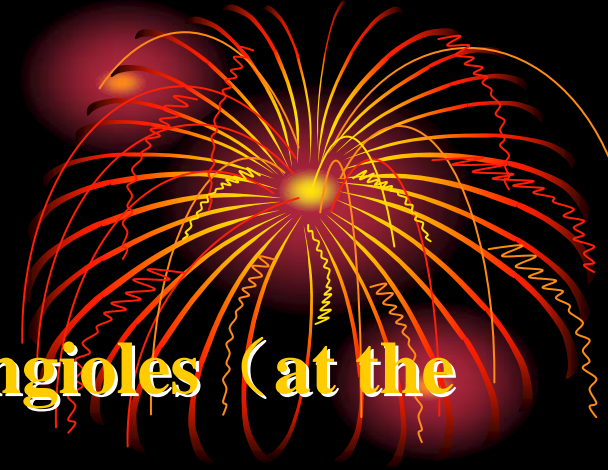




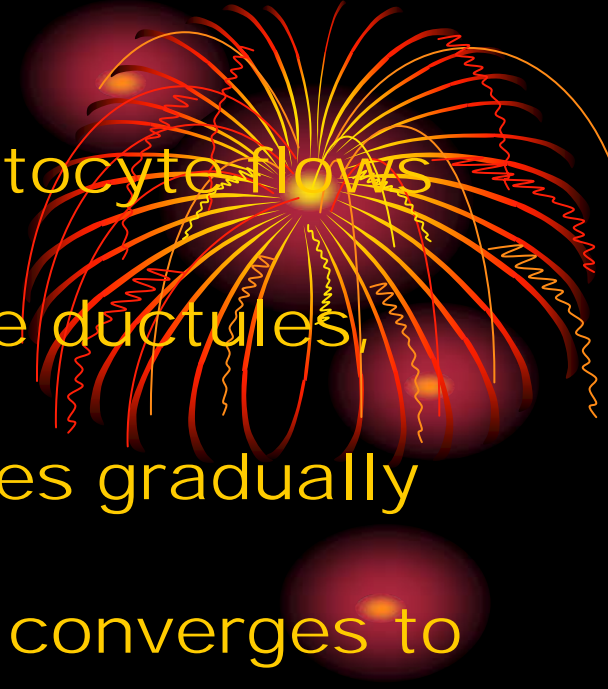
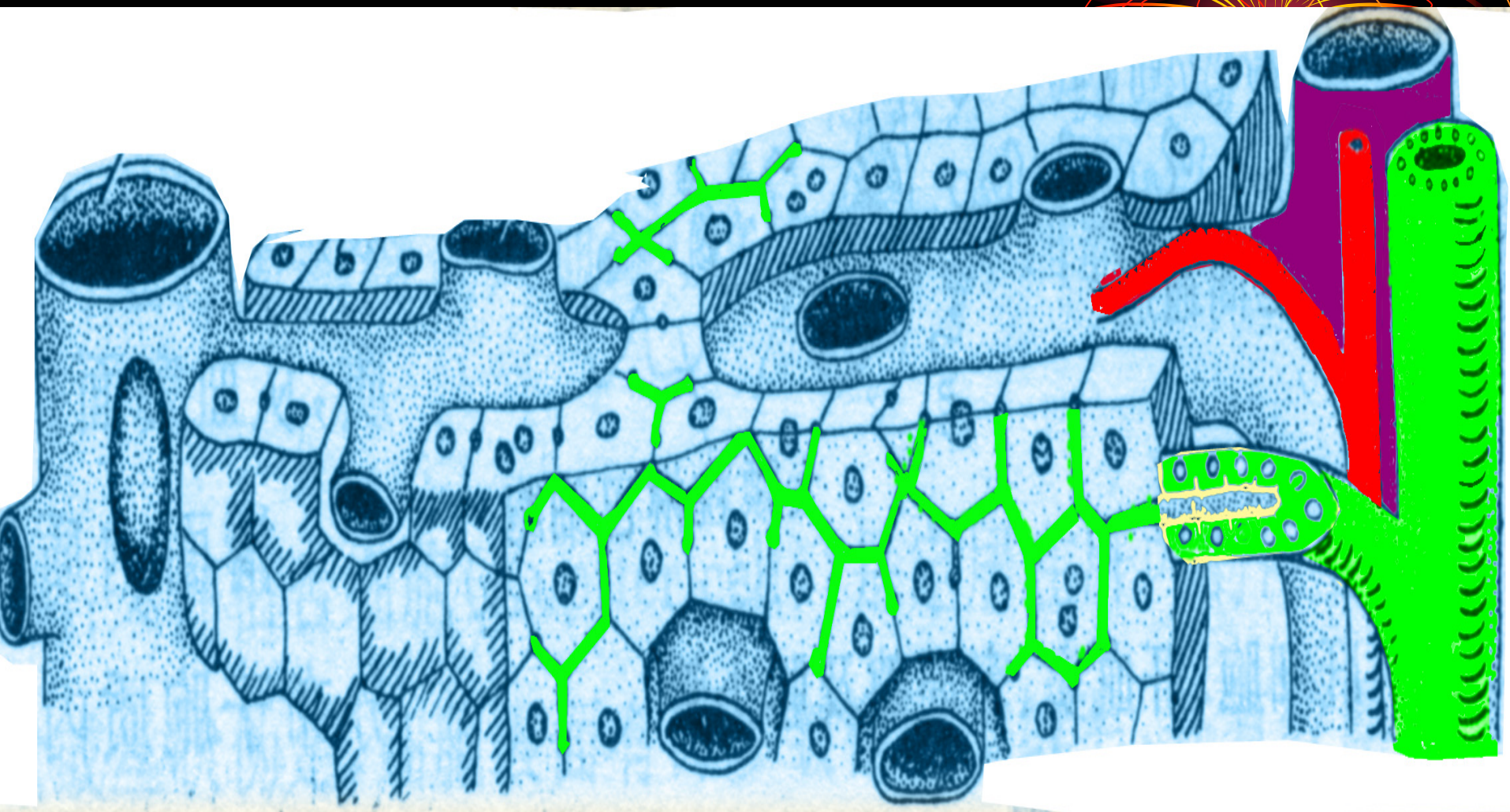

4.5 passage of bile

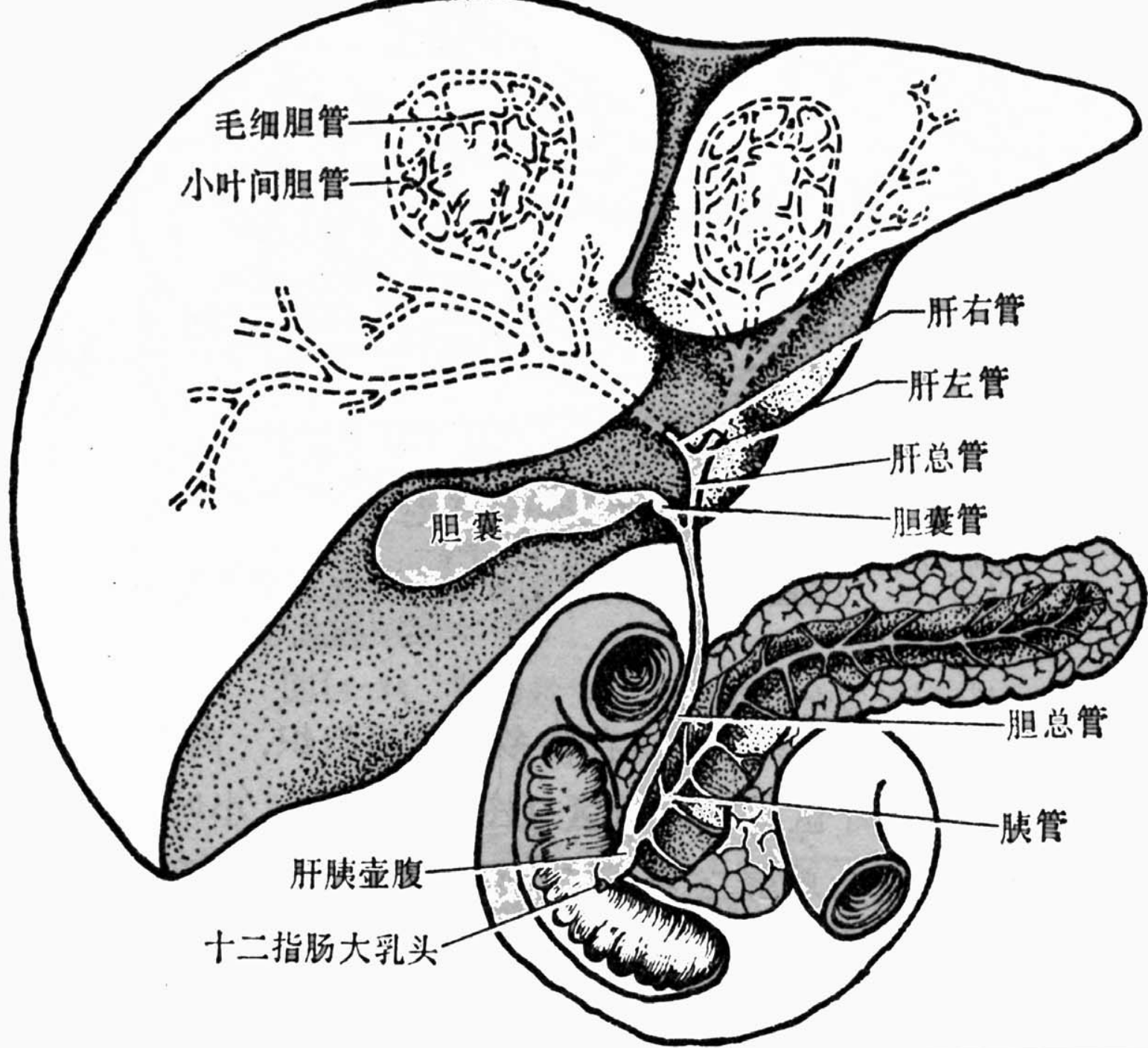
hepatocytes → bile canaliculi → **cholangioles** (at the periphery of the lobule) → interlobular bile duct (in the portal area) → left and right hepatic duct → the common hepatic duct → the common bile duct (ductus choledochus) which continues to the duodenum



- The bile produced by the hepatocyte flows through the bile canaliculi, bile ductules, and bile ducts. These structures gradually merge, forming a network that converges to form the hepatic duct, the hepatic duct, after receiving the cystic duct from the gallbladder, continues to the duodenum as the common bile duct







Emphasis of this chapter



- **The general structure of pancreas, the structure and function of acini and pancreatic islets**
- **The general structure of the liver and the lobular liver**
- **the structure and function of hepatocyte, the Kupffer cells, the fat-storing cells**
- **The blood supply and the passage of bile**